

Generic Contrast Agents

Our portfolio is growing to serve you better. Now you have a *choice*.



[VIEW CATALOG](#)

AJNR

MR Imaging and Diffusion-Weighted Imaging Changes in Metronidazole (Flagyl)–Induced Cerebellar Toxicity

Conor J. Heaney, Norbert G. Campeau and E. Paul Lindell

AJNR Am J Neuroradiol 2003, 24 (8) 1615-1617

<http://www.ajnr.org/content/24/8/1615>

This information is current as of May 6, 2025.

MR Imaging and Diffusion-Weighted Imaging Changes in Metronidazole (Flagyl)–Induced Cerebellar Toxicity

Conor J. Heaney, Norbert G. Campeau, and E. Paul Lindell

Summary: We describe a case demonstrating reversible MR imaging findings, including diffusion-weighted imaging changes in association with metronidazole (Flagyl) toxicity. The diagnosis of metronidazole toxicity was made clinically and supported by the MR imaging findings. Quantitative apparent diffusion coefficient (ADC) maps demonstrated edema with associated increased ADC values within the dentate nuclei of the cerebellum on initial imaging. Follow-up imaging performed 8 weeks after cessation of metronidazole therapy demonstrated resolution of imaging findings, including diffusion changes.

Metronidazole (Flagyl) is a common antimicrobial agent used in the treatment of anaerobic and protozoal infections. Serious neurologic side effects of metronidazole toxicity include peripheral neuropathy, ataxic gait, dysarthric speech, convulsive seizures, and encephalopathy (1, 4–6). Associated imaging manifestations of metronidazole toxicity, however, have only rarely been reported; a review of the literature demonstrates two case reports documenting MR imaging findings in patients with suspected metronidazole toxicity (2, 3). In this report, we present an additional case depicting MR imaging changes of metronidazole toxicity, including diffusion-weighted (DW) imaging changes and normalization of the MR imaging findings on follow-up imaging performed following discontinuation of metronidazole therapy.

Case Report

A 74-year-old male patient with a history of unresectable metastatic abdominal carcinoid developed a large purulent abdominal abscess with fistulous connections to the large and small bowels. He was hospitalized and underwent percutaneous aspiration of the abscess with drain placement. Adjunctive empiric antibiotic therapy was instituted during the hospital stay. The patient was discharged home with continuing oral antibiotics, including metronidazole 500 mg t.i.d., Levofloxacin, and amoxicillin. Eight weeks later, after consuming a total of more than 75 g of metronidazole, he presented to the emer-

gency room with complaints of a subacute onset (over several days) of progressive bilateral lower extremity weakness and dysarthria. The patient's vital signs were normal and stable. He was oriented to name, time, and place. Neurologic examination demonstrated that the patient was severely ataxic and was unable to stand unassisted. His speech was slurred, and he demonstrated dysmetria on finger-to-nose examination. He also demonstrated a mild left gaze nystagmus. There was a mild peripheral sensory neuropathy involving the lower extremities. Strength in upper and lower extremities remained normal on physical examination. An equivocal Babinski response was present bilaterally. Cranial nerve examination was normal.

Head CT on admission showed old lacunar disease with no evidence of acute stroke or metastatic disease. Laboratory analysis on admission, including a full paraneoplastic panel, was unremarkable. Electromyography and nerve-conduction studies demonstrated nonspecific findings of mild peripheral neuropathy and a diffuse myopathy with lower motor neuron involvement of bulbar muscles. MR imaging of the brain was performed without and then with gadolinium on a high-field-strength 1.5-T system and included conventional T1- and T2-weighted spin-echo, axial fluid-attenuated inversion recovery (FLAIR), and axial DW sequences. MR imaging demonstrated markedly increased signal intensity symmetrically involving the dentate nuclei bilaterally on T2-weighted and FLAIR images (Fig 1A), with minimal associated T1 hypointensity and no evidence of enhancement following administration of gadolinium (Fig 1B). DW imaging demonstrated corresponding high signal intensity within the dentate nuclei on the isotropic diffusion images (Fig 1C). An ADC map (Fig 1D) demonstrated an increase in the value of the diffusion coefficients in the regions of diffusion signal intensity abnormality, consistent with T2 shine-through. The MR image also demonstrated subtle nonenhancing areas of increased T2 signal intensity in the subcortical and periventricular white matter (Fig 1E). The patient's clinical presentation and imaging changes were thought to be most consistent with metronidazole toxicity. Metronidazole was discontinued, and the patient's condition improved dramatically. By the time of his discharge to rehabilitative services, on hospital day 5, the patient's speech had normalized, and he was able to ambulate with assistance. Two weeks after discharge, the patient was able to ambulate with the assistance of a cane. His neurologic examination remained remarkable for mild lower extremity paraesthesias. Repeat MR imaging examination of the brain performed on a 3.0-T MR system approximately 8 weeks after discontinuation of metronidazole showed complete resolution of the previously noted nonenhancing areas of within the dentate nuclei (Figs 2A–D).

Discussion

This case report describes MR imaging findings of metronidazole toxicity, including a description of DW imaging changes associated with this process.

Ahmed et al (2) first described the imaging findings of metronidazole toxicity in a 45-year-old woman who

Received January 8, 2003; accepted after revision February 7, 2003.

From the Department of Radiology, Mayo Clinic, Rochester, MN. A portion of this work was presented at the 40th annual meeting of the American Society of Neuroradiology, Vancouver, British Columbia, May 13–27, 2002.

Address correspondence to Dr. Norbert G. Campeau, East 2 Mayo Building, Department of Radiology, Mayo Clinic, 200 First St. SW, Rochester MN 55905.

© American Society of Neuroradiology

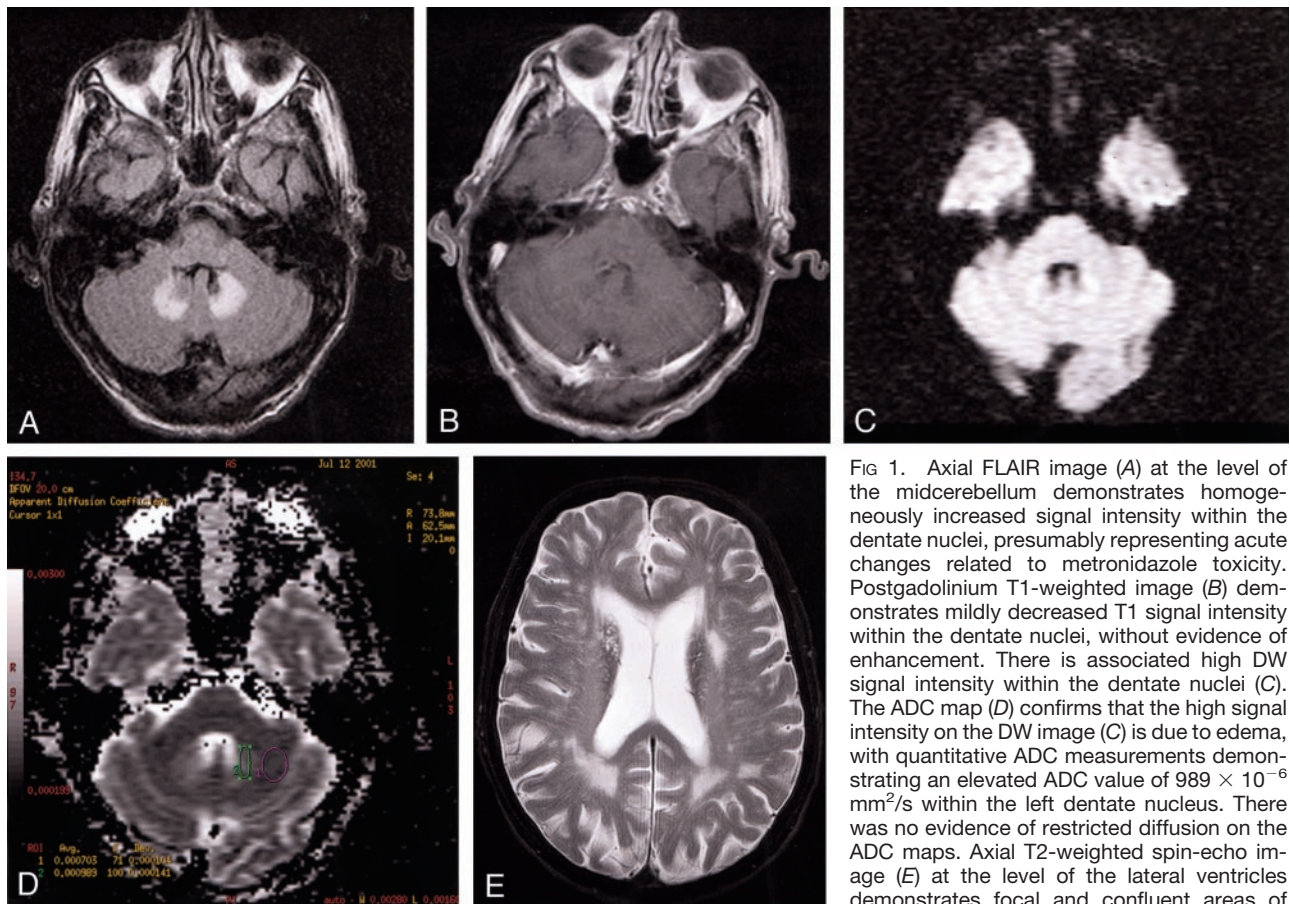


FIG 1. Axial FLAIR image (A) at the level of the midcerebellum demonstrates homogeneously increased signal intensity within the dentate nuclei, presumably representing acute changes related to metronidazole toxicity. Postgadolinium T1-weighted image (B) demonstrates mildly decreased T1 signal intensity within the dentate nuclei, without evidence of enhancement. There is associated high DW signal intensity within the dentate nuclei (C). The ADC map (D) confirms that the high signal intensity on the DW image (C) is due to edema, with quantitative ADC measurements demonstrating an elevated ADC value of $989 \times 10^{-6} \text{ mm}^2/\text{s}$ within the left dentate nucleus. There was no evidence of restricted diffusion on the ADC maps. Axial T2-weighted spin-echo image (E) at the level of the lateral ventricles demonstrates focal and confluent areas of nonenhancing signal intensity abnormality in

the periventricular regions believed to be related to chronic small vessel ischemic changes. These changes were stable at follow-up imaging (not shown) and presumably not related to metronidazole toxicity.

developed nausea, vomiting, vertigo, dysarthria, and confusion after consuming 35 g metronidazole over a 30-day course of therapy. MR imaging of the brain at this point showed “symmetric abnormal signal intensity within supratentorial white matter including the corpus callosum and within the cerebellum and cerebellar deep nuclei (page 89).” Following discontinuation of metronidazole, the patient’s symptoms resolved rapidly (ambulating by day 3). Repeat MR imaging of the brain demonstrated near-complete resolution of findings 6 weeks after discontinuation of metronidazole.

Horlen et al (3) reported imaging findings of presumed metronidazole toxicity in a 35-year-old male patient with liver cirrhosis who had consumed greater than 60 g metronidazole over a 55-day period and developed clinical symptoms consistent with metronidazole toxicity (ataxia, disorientation, peripheral neuropathy). MR imaging of the brain demonstrated abnormal symmetric hyperintense T2 signal intensity involving the dentate nuclei and inferior basal ganglia. This patient’s symptoms also resolved with discontinuation of metronidazole. No follow-up MR imaging was obtained.

In each of the cases, including ours, there was symmetrically increased T2 signal intensity in the deep cerebellar nuclei. The supratentorial imaging

findings reported by Ahmed et al (2) likely correlate to the clinically observed encephalopathy in this patient and presumably represent a more severe case of metronidazole toxicity. Because our case and the two other reported cases all demonstrated changes within the deep cerebellar nuclei, this area is likely to be most sensitive to the effects of metronidazole toxicity and is the most specific observed imaging manifestation of metronidazole toxicity. No case demonstrated evidence of significant mass effect or abnormal enhancement associated with the areas of signal intensity abnormality. In each of the cases, including ours, the symptoms rapidly normalized following cessation of metronidazole therapy. The rapidity with which the signal intensity abnormality resolves remains to be elucidated since earliest follow-up MR imaging was obtained at 6 weeks in the case of Ahmed et al’s patient and 8 weeks in ours.

DW imaging was performed in our patient and demonstrated increased signal intensity on the isotropic DW image obtained with DW gradients applied in three orthogonal axes with a b value of 1000 s/mm^2 . Apparent diffusion coefficient (ADC) maps demonstrated an increase in the ADCs corresponding to the areas of abnormal DW image signal intensity. Quantitative ADC measurement showed an ADC value of $989 \times 10^{-6} \text{ mm}^2/\text{s}$ within a region of interest placed

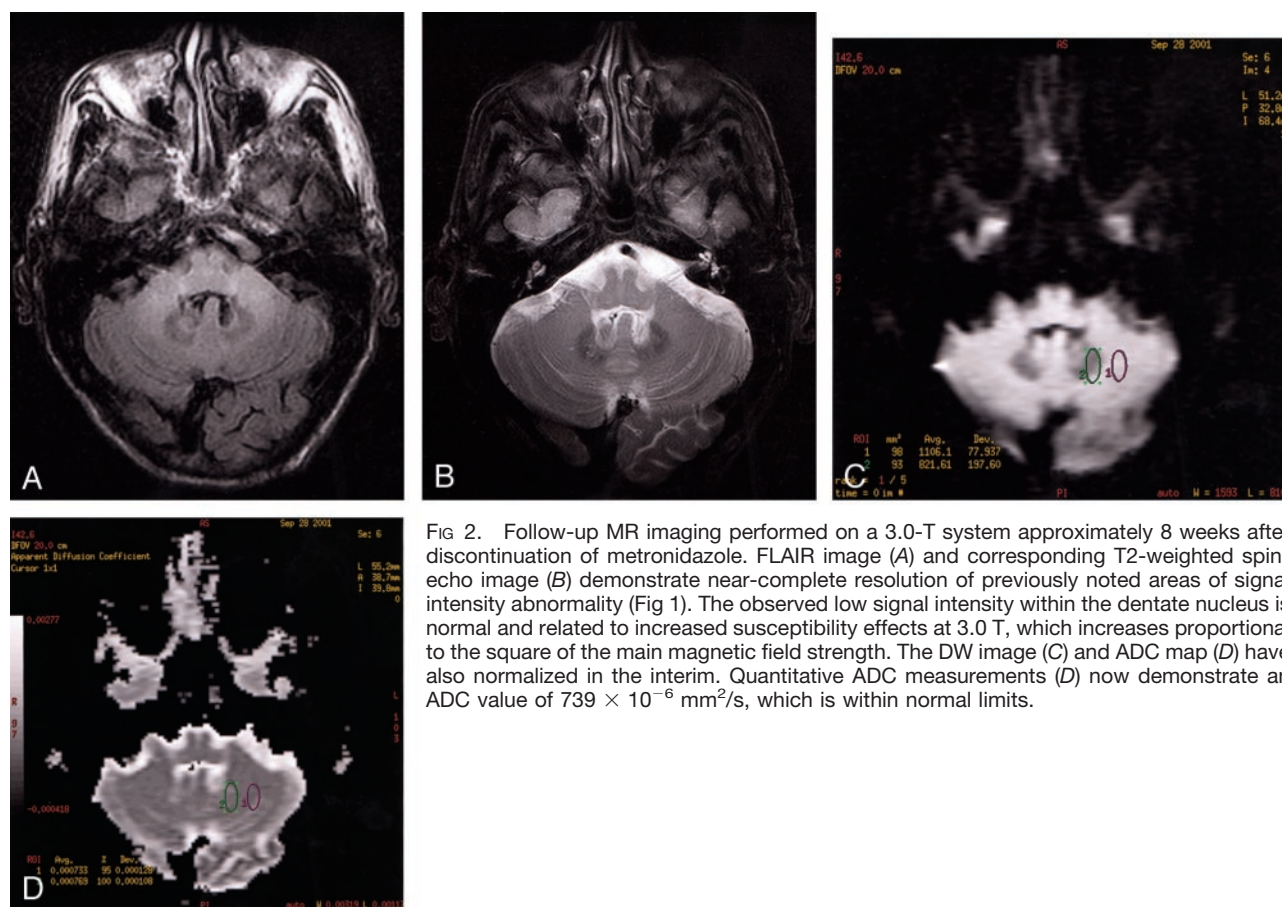


FIG 2. Follow-up MR imaging performed on a 3.0-T system approximately 8 weeks after discontinuation of metronidazole. FLAIR image (A) and corresponding T2-weighted spin-echo image (B) demonstrate near-complete resolution of previously noted areas of signal intensity abnormality (Fig 1). The observed low signal intensity within the dentate nucleus is normal and related to increased susceptibility effects at 3.0 T, which increases proportional to the square of the main magnetic field strength. The DW image (C) and ADC map (D) have also normalized in the interim. Quantitative ADC measurements (D) now demonstrate an ADC value of $739 \times 10^{-6} \text{ mm}^2/\text{s}$, which is within normal limits.

over the dentate nuclei (Fig 1D). Follow-up MR imaging showed absence of identifiable signal intensity abnormality on the DW images, and normalization of ADC value within a similarly placed region of interest to $733 \times 10^{-6} \text{ mm}^2/\text{s}$ (Fig 2D). The quantitative ADC maps confirm that the observed high DW imaging signal intensity is due to vasogenic edema with associated increased ADC values, not restricted diffusion, which would suggest an ischemic process.

The mechanism of metronidazole toxicity has not been elucidated. The signal intensity changes observed on the DW images most likely represent interstitial edemas. Ahmed et al (2) speculated that, because of the reversibility of the MR imaging changes, the cause of the changes associated with acute toxic insult were most likely due to "axonal swelling with increased water content (page 89)," not demyelination. Our observed DW imaging changes demonstrating increased ADC within involved areas would support this mechanism. Ahmed et al proposed an alternative explanation: that vascular spasm could result in localized reversible ischemia. The DW imaging changes we observed (lack of restricted diffusion), however, make this possibility less likely. Histologic examination of rat brains after high-dose metronidazole administration has shown symmetric lesions in the cerebellar nuclei, colliculus, superior olive, and cochlear nuclei that are histologically similar to Wernicke encephalopathy (4), but the observed distribu-

tion of imaging findings in Wernicke encephalopathy is predominantly in the midbrain and diencephalon.

Conclusion

This case helps further characterize the imaging changes associated with metronidazole toxicity. MR imaging is likely to be helpful in confirming the diagnosis of metronidazole toxicity in clinically suspected cases by demonstrating the presence of nonenhancing increased T2 signal intensity in the deep cerebellar nuclei, associated increased ADC, and absence of mass effect and enhancement. Additional involvement of supratentorial structures may correlate with severity of the metronidazole toxicity.

References

1. Kusumi RK, Plouffe JF, Wyatt RH, Fass RJ. Central nervous system toxicity associated with metronidazole therapy. *Ann Intern Med* 1980;93:59-60
2. Ahmed A, Loes DJ, Bressler EL. Reversible magnetic resonance imaging findings in metronidazole-induced encephalopathy. *Neurology* 1995;45:588-589
3. Horlen CK, Seifert CF, Malouf CS. Toxic metronidazole-induced MRI changes. *Ann Pharmacother* 2000;34:1273-1275
4. Von Rogulija P, Kovac W, Schmid H. Metronidazole encephalopathy in rats. *Acta Neuropathol* 1973;25:36-44
5. Frytak S, Moertel CG, Childs DS. Neurologic toxicity associated with high dose metronidazole therapy. *Ann Intern Med* 1978;88:361-362
6. Bradley WG, Karlsson IJ, Rassol CG. Metronidazole neuropathy. *BMJ* 1977;2:610-611