

# Generic Contrast Agents

Our portfolio is growing to serve you better. Now you have a *choice*.



[VIEW CATALOG](#)

# AJNR

## Imaging of Brain Tumors with Histological Correlations

*AJNR Am J Neuroradiol* 2003, 24 (9) 1921  
<http://www.ajnr.org/content/24/9/1921>

This information is current as of April 20, 2025.

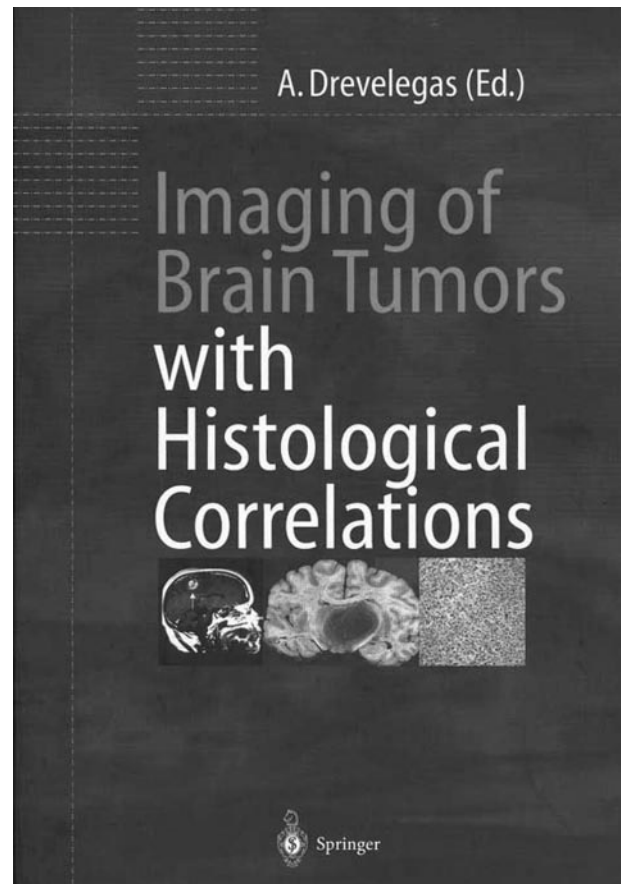
### Imaging of Brain Tumors with Histological Correlations

A. Drevelegas. Berlin-Heidelberg: Springer; 2002. 302 pages, 248 figures in 508 separate illustrations. \$149.00.

*Imaging of Brain Tumors with Histologic Correlations* is a highly illustrated and well-written multi-authored (21 authors) book. Although all the tumors shown have been widely shown and described in other textbooks, the excellent quality of the histologic sections that accompany many of the CT scans and MR images makes this a particularly valuable contribution to the neuroradiology literature.

The first three of 13 chapters are introductory in nature (classification, basic imaging concepts, and gliomas genetics), the next nine deal with specific tumor types, and the last chapter describes the use of brain scintigraphy in tumor evaluation. The first chapter briefly traces the history of the histologic classification and grading of brain tumors from Bailey and Cushing's first classification of gliomas in 1926, through other schemes, to the present WHO classification. The historical vignette is interesting; however, it would have been more educational to have highlighted the different classifications in a succinct table because brain tumor terminology is not uniform worldwide.

The second chapter, which introduces the reader to the major brain imaging techniques (MR imaging and CT), can easily be skipped by the experienced neuro-radiologist considering that none of the MR imaging methods currently used are presented in depth. Some statements require further explanation, such as the sensitivity of fast spin-echo imaging being lower than that of conventional spin-echo imaging (blood/brain should have been specifically identified) and the disadvantages of fluid-attenuated inversion recovery imaging including long imaging times (no mention is made of fast fluid-attenuated inversion recovery imaging techniques). It is understandable, however, that this chapter is short because it seems that it is intended to simply mention the MR imaging methods that are usable in tumor evaluation. Likewise, the chapter on molecular abnormalities in gliomas (Chapter 3) is short (6 pages); however, for the neuro-radiologist who might want some very basic information regarding the genetics of gliomas, this chapter presents a nice summary. The "meat" of the book begins with Chapter 4 (on low grade gliomas), and subsequent chapters take the reader through all the major tumors, specifically, high grade gliomas, pineal tumors, embryonal tumors, cranial nerve tumors, meningeal tumors, lymphomas and hemopoietic tumors, sellar/parasellar tumors, and metastasis. No important or significant tumor has been omitted, and most include illuminating descriptions of pathologic abnormality, with high-quality color plates showing the histopathology. The authors have nicely introduced very high field imaging (8 T) to brain tumor



and have incorporated diffusion imaging and color perfusion with quantitative mapping of blood flow.

The final chapter on brain scintigraphy summarizes the major issues in evaluating brain tumors. For those with a meager background in nuclear imaging and for those who are not directly involved in nuclear imaging on a regular basis, this will be a valuable chapter. Well discussed are the pros and cons of single photon emission CT and positron emission tomography cameras and the isotopes used for brain tumor detection. The images selected show the usefulness of various agents and the scanning involved (single photon emission CT versus positron emission tomography). They are educational and useful to those who focus on only MR imaging and CT, too infrequently considering the importance of adjunctive nuclear medicine examinations.

In summary, this well-designed and smartly illustrated volume combines imaging and histopathology in a fashion that helps add a solid perspective to brain tumor imaging.