

Generic Contrast Agents

Our portfolio is growing to serve you better. Now you have a *choice*.



[VIEW CATALOG](#)

AJNR

Endoscopic Endonasal Transsphenoidal Surgery

AJNR Am J Neuroradiol 2004, 25 (4) 661-662
<http://www.ajnr.org/content/25/4/661>

This information is current as
of May 7, 2025.

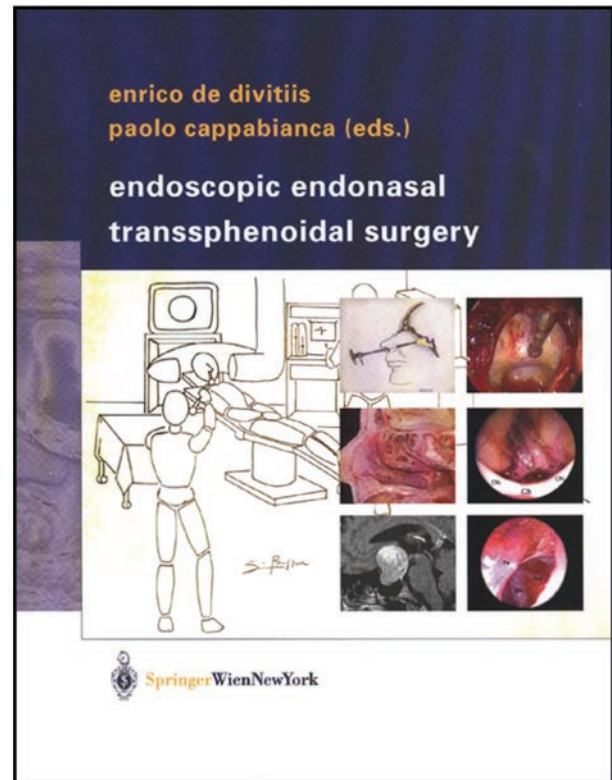
Endoscopic Endonasal Transsphenoidal Surgery

Enrico de Divitiis and Paolo Cappabianca, eds. New York and Vienna: Springer-Verlag; 2003. 198 pages, 172 illustrations. \$219.00.

Despite medical advances—including treatment with dopamine agonists, somatostatin analogs, and hormone receptor blockers, in addition to endocrine replacement—surgery remains at the forefront of the treatment of pituitary adenomas. The exception to this rule is prolactin-secreting tumors, which are, for the most part, adequately treated with dopamine agonists. Nevertheless, the need to eliminate mass effect—causing neurologic dysfunction and rampant hormonal hypersecretion has maintained a strong place for surgery in the field of pituitary tumors. Of course, the art of surgery has evolved over time, from the early century exploits of Cushing to promote transsphenoidal surgery, followed by a resurgence of transcranial procedures, which eventually gave way to a resurgence of the transsphenoidal approach with Hardy and Guiot. Subsequently, the era of minimally invasive surgery produced endoscopic approaches, which have been successfully applied to the pituitary region. Thus, this book by de Divitiis and Cappabianca is timely and beautifully depicts the minimally invasive techniques that are evolving in neurosurgery and that will have a major impact on the way in which pituitary surgery is performed.

Chapter 1 reviews the evolution of transsphenoidal surgery and describes the transition made from radical disfiguring transfacial procedures to the sublabial and transnasal transsphenoidal procedures. This is an excellent historical perspective worth reading. The use of the microscope popularized the transsphenoidal approach to the sellar region, which has eventually given way to the endoscope in conjunction with the use of endoscopic procedures in general by ear, nose, and throat surgeons, to replace the more invasive sinus surgery.

Chapter 2 describes in detail the equipment and instrumentation associated with the endoscope as it is applied to pituitary surgery and provides a number of the critical details regarding the enhanced optics currently available for use with endoscopic systems. Light sources have evolved to the present, in which the xenon light source is the state of the art, with sophisticated optical cables for high optical transmission. In addition, the monitors, digital video recorders, and the array of surgical instruments are nicely depicted. The chapter that follows launches into a very thorough discussion of the anatomy as it pertains to the endoscopic transnasal approach. The nasal cavity and nooks and crannies of the sinuses are adequately described, from their developmental embryology to the transitions that occur throughout life. The cadaver specimens depicted are of excellent quality, and the bone vascular and nerve anatomy is nicely shown. The authors also describe the variations on the anatomical themes of the



sphenoid sinus and sellar and parasellar regions, which are important for those surgeons who undertake endoscopic approaches. Thus, this is a must-read-and-understand chapter, especially for the novice who is about to learn the field of endoscopic transnasal surgery to approach the sellar, parasellar, and suprasellar region.

Chapter 4 deals with the role of the endocrinologist, and though this may not seem necessary for a surgical text, it is clear that, although the primary objectives are to normalize hormones, shrink the tumor mass, and play a key role in situations where surgery fails, surgery is still the mainstay of the approach to this region, except for the prolactin-secreting tumor. This chapter covers the medical armamentarium that is available to surgeons, in addition to the decision-making process with regard to either pre-treatment or post-treatment strategies following an incomplete resection of a secretory pituitary tumor. I found the description of the medical management of each secretory type of pituitary tumor to be useful and helpful with regard to understanding how surgery can be maximized with adequate medical therapy. It was also of interest to understand the encouraging results with some of the new growth hormone receptor blockers such as pegvisomant. Although the fol-

lowing chapter delineates the role of the neuroradiologist in this disease, this would be additional information with regard to most neuroradiologists, in terms of their understanding of pituitary anatomy and the differential diagnosis of various lesions affecting this area. Thus, this is a nice supplement, but it in no way can replace a more definitive text needed by neuroradiologists to understand this area and to appreciate the wide variety of lesions that occur in this region. Notwithstanding, this is a useful chapter for the neurosurgeon as well as the endocrinologist and neuropathologist with regard to understanding the role of MR imaging and CT scanning in defining not only the tumor, but also the adjacent bony anatomy. The illustrations representing the multitude of lesions that occur in this area are descriptive and representative, as is the section on presurgical planning with regard to thin-section CT, which is critical for the endoscopic surgeon.

A subsequent brief chapter regarding the role of the ophthalmologist is informative and certainly useful for the surgeon, but it will have little application for the neuroradiologist.

Subsequently, the authors describe in great detail the endoscopic endonasal transsphenoidal approach to the sella. This is done in a nearly step-by-step fashion, first pointing out the indications of this approach as opposed to conventional pituitary microsurgery and when this approach should be used for the nonadenomatous lesions such as non-neoplastic cysts and craniopharyngiomas. They also very nicely describe how to approach residual or recurrent tumors after previous transsphenoidal resections when the anatomy is distorted. The authors cover the aspect of CSF leaks, either *de novo* or caused by surgery, and describe in detail how these should be approached.

I also found that the description of the operating room setup and instrumentation was spectacular and should give the beginning endoscopic surgeon a very good overview of the attention to detail that is necessary to minimize the likelihood of problems that could arise during the course of an endoscopic procedure.

The authors also discuss the use of navigation to identify the region of carotid vessels and the use of Doppler sonography for carotid imaging and for localizing microadenomas. Once again, this is a step-by-step description of the procedure, including the pitfalls and the learning curve for the novice and how to deal with unexpected findings that occur during this approach. I found the details explaining how to repair the sellar defects, as well as how to achieve intra- and extradural closure of the sellar floor, to be superb. In addition to their previous explanation of how to deal with CSF leaks, this certainly is one of the strongest chapters in the entire text—as it should be, because the book is intended primarily for surgeons.

The authors subsequently describe additional openings and exposures of the planum sphenoidale and upper clivus, which become very useful for tumors that extend into these regions, in addition to meningioma and chordomas, which can be approached through the endoscope.

Finally, the authors discuss their own results with regard to how they achieved the degree of resection and how it affected the patterns of recurrence. They discuss the complications in great detail and describe the plans of how to deal with them, should they arise. Finally, they review the advantages and disadvantages of different endoscopic techniques and provide in a very detailed fashion all of the important aspects of this type of procedure that they have learned through their experience with nearly 300 cases.

The final four chapters involve a brief description of the role of the anesthesiologist, which is virtually no different from that in standard transsphenoidal surgery. An overview of the extended endoscopic approaches to the skull base is covered in chapter 9, which again reviews the pertinent anatomy and types of cases that can be approached in this manner. These authors give a fair amount of detail with regard to the different types of CSF leaks and how to approach them and an excellent correlation with CT scan images. They also discuss how the images should be interpreted with regard to endoscopic anatomy. They report their experience with these different approaches in controlling CSF leaks, along with their excellent results. I also found that the detail provided regarding the approach to the cavernous sinus, including the different phases from beginning to end, was very useful, especially with regard to the use of navigation and a micro-Doppler to help expedite localization of the carotid arteries and to avoid injury to these critical structures. Notwithstanding, their results point out the high likelihood of residual disease for these types of lesions when this approach is used to treat tumors extending beyond the sellar region. Although this is clearly recognized by most pituitary neurosurgeons, I believe this chapter is critical in pointing this out and is an honest description of the often less-than-radical resection that can be performed with tumors involving these parasellar and suprasellar regions.

Finally, a brief mention of the role of the neuropathologist is made, and, though this appears to be no different, based on endoscopic techniques, it is nonetheless a very nice and appropriate review.

Overall, this is a magnificent textbook that is not only timely, but also beautifully produced, with excellent drawings, endoscopic photographs, and anatomic dissections. It is clear from reading this text that the authors have put a great deal of time and effort into its development, organization and writing, as well as the description of the necessary considerations that both the novice and experienced surgeon must take into account when approaching tumors in this area. This book is a must for any pituitary surgeon, and, to this end, as a critical member of the team, the neuroradiologist will gain great insight into how surgeons and endocrinologists approach this disease, along with the evolving field of minimally invasive surgery as it relates to pituitary surgery. Thus, without question, this book is highly recommended, not just to surgeons, but to all physicians and allied health personnel who manage patients with these very complicated sellar, parasellar, and suprasellar lesions.