

The **next generation** GBCA  
from Guerbet is here

Explore new possibilities >

Guerbet | 

© Guerbet 2024 GUOB220151-A

# AJNR

## Image-Guided Spine Intervention

*AJNR Am J Neuroradiol* 2004, 25 (7) 1299  
<http://www.ajnr.org/content/25/7/1299>

This information is current as  
of July 22, 2024.

### Image-Guided Spine Intervention

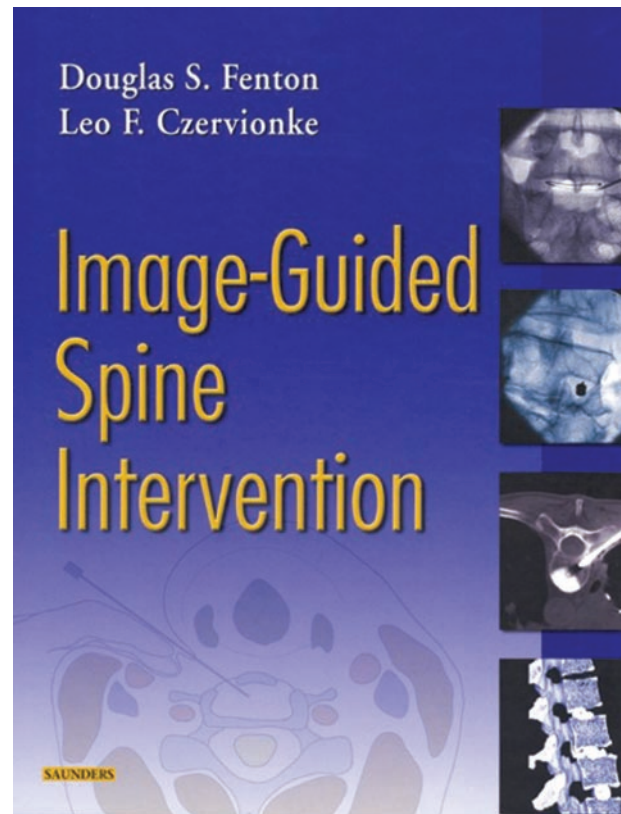
Douglas S. Fenton and Leo F. Czervionke. Philadelphia: WB Saunders; 2003. 448 pages, 519 illustrations. \$149.

The fast-growing field of spine intervention has been in need of a comprehensive guide, and Drs. Fenton and Czervionke have provided it. This book promises to become a “classic.” Its many features should prove helpful for anyone starting a spine intervention service and should also serve as a reference book for experienced operators.

The authors are well known in the field. Each chapter begins with a brief history of the procedure. Next, the pertinent anatomy is thoroughly illustrated with the use of microtomes, diagrams, and radiographs (including fluoroscopy, CT scans, and MR images). *All* images provided in the book are state of the art, which is something rarely seen today. Patient selection criteria, indication, and contraindications are well delineated. The authors then proceed to provide us with step-by-step instructions of how to perform each procedure, including the equipment and medications needed. The work also includes radiographs illustrating most steps. There is discussion of alternative approaches with their respective advantages and disadvantages. Postprocedural care is included as well.

There are sample dictations, multiple case reports, and a list of applicable CPT codes. An extensive reference list is available at the end of each chapter. After most chapters, the authors have recruited a fellowship-trained spine neurosurgeon to provide the clinician’s perspective. This latter, rather unique, feature proves to be most interesting. In these vignettes, we learn the indications for each procedure. There is also discussion of the use of alternative diagnostic tests and treatments that are not supervised by radiologists. As the authors point out, nonspecialists perform the management of a significant number of these patients. Thus, it falls on us to educate some of the referring physicians as to which procedure is most indicated for a particular situation.

The first chapter discusses basic needle manipulations. It is an excellent review of different techniques. There is the clever use of a grapefruit to demonstrate the different trajectories taken by different-shaped needles. Strategies for the treatment of facet disease and medial branch block are discussed in the next two chapters. Nerve root blocks, epidural steroid injections, sacroiliac joint injections, percutaneous spine biopsy, and pharmacology relevant to spine proce-



dures are well covered. In the vertebroplasty chapter, the authors advocate venography, which is somewhat surprising because this has mostly fallen out of favor. The chapter mentions only the use of slow-setting cement (Codman Cranioplastic). Although it is the preferred cement, a significant number of interventionalists advocate the use of faster-setting cement (Simplex P). Controversial subjects such as diskography and intradiskal electrothermal therapy are discussed. Perhaps the book’s most significant omission is automated percutaneous lumbar discectomy. In future editions, the authors may also want to discuss intraspinal cyst aspirations in more detail.

In summary, *Image-Guided Spine Intervention* is well written, well illustrated, and thorough. Any physician practicing interventional spine procedures should own a copy. This book would also be of extreme value to referring physicians.