

Are your **MRI contrast agents** cost-effective?

Learn more about generic **Gadolinium-Based Contrast Agents**.



**FRESENIUS
KABI**

caring for life

AJNR

**Advances and Technical Standards in
Neurosurgery. Vol. 29**

AJNR Am J Neuroradiol 2005, 26 (1) 188-189
<http://www.ajnr.org/content/26/1/188>

This information is current as
of April 17, 2024.

Advances and Technical Standards in Neurosurgery. Vol. 29

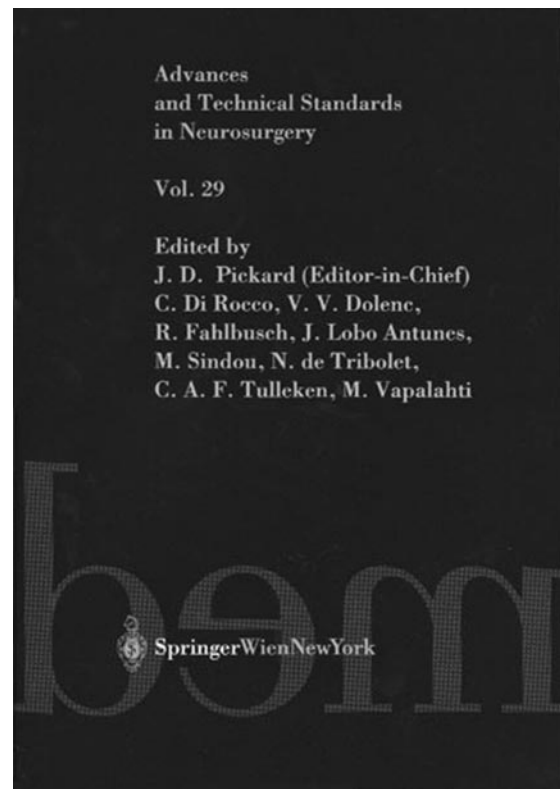
J. D. Pickard, C. Di Rocco, V. V. Dolenc, R. Fahlbusch, J. Lobo Antunes, M. Sindou, N. de Tribolet, C. A. F. Tulleken, M. Vapalahti, eds. Vienna: Springer-Verlag; 2004. 304 pages, 101 illustrations. \$125.

This is the 29th volume in a series originally developed as an adjunct to the training of European neurosurgeons. Sponsored by the European Association of Neurosurgical Societies, each book contains two main parts: the first part of each volume presents recent advances in neurosurgery and related areas, and the second part is intended to provide “in-depth reviews of established knowledge in all aspects of neurosurgery” primarily for postgraduate training of young neurosurgeons.

In this volume, the advances section covers two main topics, “anatomical and physiologic mechanisms of disorders of consciousness” and “advances in craniostyosis research and management.” These two widely disparate topics illustrate the broad spectrum covered by the specialty of neurosurgery.

The chapter on disorders of consciousness reviews the phenomenology and regulation of the wake-sleep cycle. Slow-wave sleep and paradoxical sleep are described with discussions of the anatomic centers concerned. The “wakefulness network” is then reviewed with detailed discussion of the activity of specific neuronal nuclei and tracts and the neurotransmitters involved. Complex but useful diagrams illustrating these pathways and emphasizing the pertinent neurotransmitters are well done and helpful. The chapter concludes with a discussion of effects of sleep deprivation on cognitive performance.

The chapter on craniostyosis begins with a review of normal craniofacial embryology and growth and then discusses the etiology and pathogenesis of craniostyosis. Interesting references are made to ancient manuscripts discussing these disorders. Mechanical factors and genetics that may be involved in pathogenesis are detailed. The clinical functional implications of craniostyosis are well discussed, and there is a good description of the evolution of surgical techniques for correction of these skull disorders. Historically, there has been a wide diversity of opinion with regard to the proper surgical management of some of the more common craniostyoses, so the experienced critical reader will be able to take the authors’ biases into account. The main principles of surgical techniques are discussed, including various types of fixation systems and bone substitutes. The discussions of distraction osteogenesis and spring-mediated cranioplasties are interesting. Detailed descriptions of surgical technique for the more common synostoses are provided, with excellent diagrams accompanying the text. Missing from the chapter is any discussion of positional skull abnormalities and non-surgical helmet therapy for correction of skull shape.



The technical standards section makes up nearly three-quarters of the book. The first chapter in this section covers preoperative evaluation, surgical technique, and outcome in surgical management of temporal lobe epilepsy. The epidemiology and symptomatology of this disorder are covered, along with discussion of etiology and pathology. Preoperative evaluation is extensively discussed, and neuroradiologists will be particularly interested in the extensive discussions of preoperative radiographic evaluations using MR imaging, positron-emission tomography (PET), and single-photon emission tomography (SPECT). There are discussions of volumetric MR imaging analysis of the hippocampus, functional MR imaging, and MR spectroscopy. The use of intracranial electrodes and their radiographic localization are well presented. Brief but useful discussions regarding PET and SPECT imaging are presented. Surgical technique and outcome are then discussed.

Two lengthy and detailed chapters then discuss motor-evoked potential monitoring for spinal cord and brain stem surgery and motor-evoked potential monitoring for surgery of brain tumors and vascular malformations. Detailed discussions of the techniques and uses

of motor-evoked potentials are presented. These chapters include some correlation with neuroimaging.

The next chapter covers functional neuronavigation and intraoperative MR imaging. This chapter will be of particular interest to neuroradiologists and describes one center's experience with intraoperative MR imaging with two different systems. Initially, this center (in Erlangen, Germany) worked with a low-field 0.2T scanner for intraoperative MR imaging but then later developed the use of a high-field 1.5T MR scanner for intraoperative use. The integration of magnetoencephalography and functional MR imaging data into the anatomic imaging is discussed. A well-written, thoughtful, and useful review of their experience with various diseases by using these techniques is presented, with discussion of the advantages and disadvantages of the low-field and high-field intraoperative MR imaging systems. Excellent illustrations accompany the discussion.

The final chapter presents a detailed description of the insula, a frequently neglected anatomic region. The anatomic descriptions are accompanied by excellent radiographic illustrations. Certainly, many neurosurgeons can learn from this chapter, and neuroradiologists will also find it quite useful.

Overall, this book is well written and continues in the excellent and practically useful tradition of this series. In general, the text is clear, and the chapters are extremely well referenced. The book is liberally illustrated with a good combination of diagrams, radiographic images, and intraoperative photographs. Although this book is directed mainly to neurosurgeons, both young and experienced, it should also be of interest to neuroradiologists. The neuroradiologist will see how the imaging is directly used as a tool in surgical management. With such an understanding, the neuroradiologist becomes a much more effective member of the team caring for the patient.