

Are your **MRI contrast agents** cost-effective?

Learn more about generic **Gadolinium-Based Contrast Agents**.



**FRESENIUS
KABI**

caring for life

AJNR

Neuroradiology: The Requisites

AJNR Am J Neuroradiol 2005, 26 (1) 191-192

<http://www.ajnr.org/content/26/1/191>

This information is current as
of April 19, 2024.

Neuroradiology: The Requisites

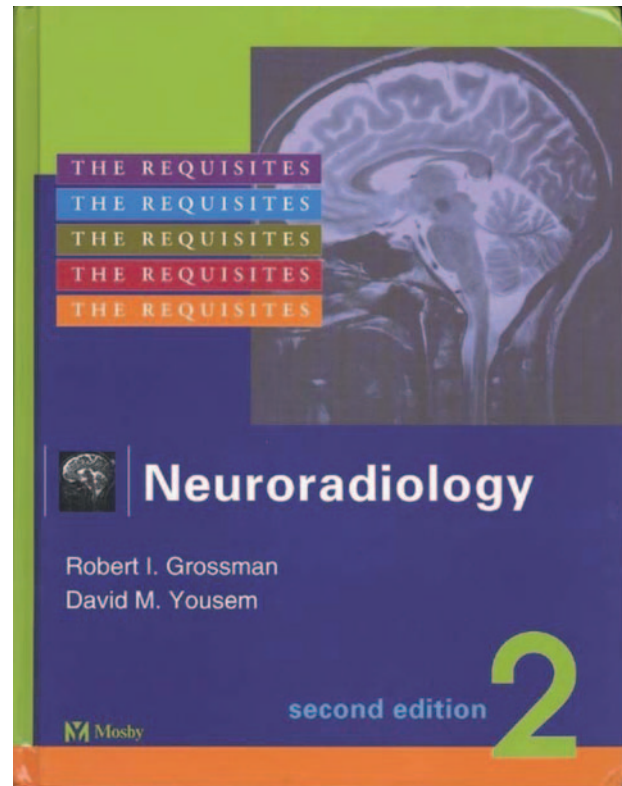
Robert I. Grossman and David M. Yousem. 2nd ed. St. Louis, MO: Mosby; 2003. 908 pages, 730 illustrations. \$95.00.

A new edition of any highly successful medical textbook is always welcome, because rapid changes in technology tend to render first editions out of date. With the concept that a new edition should disclose significant and important new information, the second edition of Grossman and Yousem's *Neuroradiology: The Requisites* was reviewed.

Let me begin by saying that I considered the first edition, published in 1994, to be the single best textbook in diagnostic neuroradiology. It covered the entire field in a clearly written, informative, well-illustrated, attention-grabbing format. I considered the volume to be the best source of information for residents and fellows and a perfect reference for practicing radiologists looking for direct and authoritative answers to questions.

Now this new edition is available, and it is important to highlight what is new and why I consider it to be the wisest purchase of a textbook in the entire field of diagnostic neuroradiology. First, the book is close to 400 pages longer than the first edition, nearly doubling its original size. When looking at the table of contents, one notices just two new chapters ("CNS Anatomy: Sella/Central Skull Base" and "Mucosal Disease of the Head and Neck"). This, however, belies the fact that each of the other chapters is more abundantly illustrated and expansive, in terms of both critical information and new techniques. All expected areas of neuroradiology are thoroughly covered. Throughout, the authors have not lost their unique touch of humor, cogent phrases, pointed limericks, and memorable wording. Fortunately for the reader, that "mold-breaking" style is pervasive throughout this new edition.

Some specifics: In the "Techniques" chapter, as one would expect, the MR imaging section is greatly expanded, with new sections on diffusion-weighted imaging, perfusion scanning, functional MR imaging, magnetization transfer, and MR spectroscopy. For those who prefer not to read about the physics of MR imaging but realize the need to understand the basic principles of MR imaging, this 17-page summary will fit the bill. Techniques are described without mathematical formulas, and these descriptions are sufficient to give one a working knowledge of how the studies are performed. Because of the recent publication of this book, the newest twists in MR angiography, MR spectroscopy, diffusion-weighted imaging, and so forth are covered. Be assured that more than MR imaging and CT are contained in this text; one also receives an overview of angiography, contrast and contrast reactions, myelography, sonography, and nuclear scanning. In fact, the appendix of this chapter devotes two pages to the step-by-step management of



various contrast reactions. This is worth copying and making it accessible in multiple locations for immediate reference. In all chapters, the first page includes an outline of what is contained in the chapter—this makes hunting down a specific topic easy, without having to flip back to the index.

The "Cranial Anatomy" chapter contains detailed vascular anatomy, excellent, and large line drawing of the structures of the brain and the relationships of these structures to various cerebral functions. The cranial nerves with their areas of origin and the structures innervated are well described. Although obviously there is no "new anatomy" shown, the pathways, the gyri, and how they relate or may relate to functional MR imaging are simply and entertainingly described—readers will have to see for themselves what areas of the brain are "lost" in adolescence. For most neuroradiologists, this chapter will serve as a review of what they learned at one time, or what they have forgotten (this reviewer included).

From the third chapter on, we get into the meat of the matter, starting with the pathology and the correlative imaging in "Neoplasms of the Brain." Here the imaging is of a high quality and all the important disease categories and specific diagnoses are covered.

The multiple tables in this chapter and throughout the entire book are important, concise, and packed with information. For instance, one table shows 15 criteria used to separate lymphoma from toxoplasmosis, and another succinctly differentiates the imaging criteria of different temporal lobe tumors. In every area of this book, tables like these are accurate, complete, and are an excellent source of vital information. The chapter on brain tumors—and likewise with other chapters—has an abundant number of figures that demonstrate all the critical routine imaging (CT and MR) findings. That the authors were able to cull virtually all of these cases from their own personal experience is remarkable in itself. Although this book is intended to describe basic neuroradiology, a suggestion for the next edition (although the senior author swears there will be no next edition) would be to integrate more advanced techniques (diffusion-weighted, MR spectroscopy, perfusion, chemical shift imaging, and so forth) into these chapters. What is “advanced” today will be basic tomorrow.

It is not my intent to describe the positive attributes of each chapter; doing so would make this review too long and it would fill too many journal pages. Nonetheless, there are many outstanding areas to highlight, keeping in mind that these comments are snapshots of just portions of the book. In the chapter on vascular diseases of the brain (besides the intriguing limericks), the theory and uses of diffusion and perfusion imaging are beautifully and simply explained and illustrated, the vasculitides along with the causes of venous occlusive diseases are well summarized and, of course, the theories of MR imaging signal intensity abnormalities in the various stages of intracerebral hemorrhage are explained. As an example of how this textbook strives to give a complete view of neurora-

diology, the authors even summarize some of the current concepts in the treatment of cerebral ischemia.

Following consecutively after the chapters on brain tumors and vascular disease are chapters on head trauma, infection and inflammatory diseases, white matter disease, neurodegenerative disorders, congenital abnormalities of the brain and spine, the orbit, skull base abnormalities, the temporal bone, sinonasal disease, diseases of the neck, degenerative and nondegenerative spine disease (why is spine always at the end of neuroradiology textbooks?), and a final chapter on the approaches to neuroradiology.

The head and neck chapters could easily stand on their own as a separate text, but fortunately the authors kept all this material in one, albeit heavy, book. If a reader forgets the staging of various tumors of the neck or needs a refresher on temporal bone anatomy or pathology, here is the place to look up material. This recommendation pertains to all areas of concern to neuroradiologists.

I often test the completeness of a text by looking up some rare or infrequently encountered abnormality to see whether and how well it is covered. I could not trick this book—I found everything. This is the text recommended over all others, no matter one's degree of experience or training. This book is unique in its approach, complete in its content, and profuse in its illustrative and tabular material.

Now to turn the tables on Drs. Grossman and Yousem, I end with the following summary:

The wit and humor are clever.

Does the reader ever get bored?—*Never!*

You can learn your neuro,

With teaching that's thorough,

And make it a pleasant endeavor.