

The **next generation** GBCA
from Guerbet is here

Explore new possibilities >

Guerbet | 

© Guerbet 2024 GUOB220151-A

AJNR

MR Imaging Findings of Intracranial Dural Arteriovenous Fistulas: Relations with Venous Drainage Patterns

Bae Ju Kwon, Moon Hee Han, Hyun-Seung Kang and Kee-Hyun Chang

This information is current as of September 17, 2024.

AJNR Am J Neuroradiol 2005, 26 (10) 2500-2507
<http://www.ajnr.org/content/26/10/2500>

MR Imaging Findings of Intracranial Dural Arteriovenous Fistulas: Relations with Venous Drainage Patterns

Bae Ju Kwon, Moon Hee Han, Hyun-Seung Kang, and Kee-Hyun Chang

BACKGROUND AND PURPOSE: Venous drainage patterns are a major determinant of clinical outcome in intracranial dural arteriovenous fistula (DAVF) patients. In this study, we sought to identify MR imaging finding differences between DAVF types classified on the basis of venous drainage patterns.

METHODS: Twenty-seven patients diagnosed as having DAVFs by conventional angiography were included. Medical records ($n = 27$), and MR imaging ($n = 27$) and MR angiography (MRA; $n = 11$) findings were retrospectively reviewed. MR imaging findings included flow void cluster, engorged ophthalmic vein/proptosis, white matter hyperintensity, intracranial hemorrhage, dilated leptomeningeal or medullary vessels, venous pouch, and leptomeningeal or medullary vascular enhancements. MRA findings included identifiable fistula, venous flow-related enhancement, and prominent extracranial vessels. Patients' presentations and MR imaging findings were compared among angiographic type I, II, and III cases (according to Borden's classification), and MRA findings were compared between cases with and without retrograde leptomeningeal venous drainage (RLVD).

RESULTS: Patient presentations were aggressive in one (13%) of the type I cases, 5 (50%) of the type II cases, and 8 (100%) of the type III cases ($P = .002$). Aggressive presentations included hemorrhage, focal neurologic deficits, seizures, intracranial hypertension, and an altered mental status. MR images showed significantly higher frequencies of dilated leptomeningeal or medullary vessels in a higher type [0 in type I, 5 (42%) in type II, and 7 (100%) in type III], and leptomeningeal or medullary vascular enhancements [0 in type I, 4 (33%) in type II, and 7 (100%) in type III]. By using MRA, fistulas were identified only in cases with RLVD (5 [83%]). Venous flow-related enhancement was present in 10 cases (91%). A sole false-negative case on MRA, as compared with conventional angiography, resulted from nonvisualization of the slow venous flow (8%). No false-positive fistula was found at the other intracranial sites in all cases. Overall, MRA assessment for DAVF was adequate for both fistula and venous flow-related enhancement in 10 cases (91%) and inadequate in a remaining case because of the fistular location out of field.

CONCLUSION: MR imaging demonstration of leptomeningeal or medullary vascular dilation and enhancements may be associated with features that are considered predictors of a poor outcome and indicates a need for urgent therapy in intracranial dural AVF patients. MRA is a complementary tool for the identification of dural AVF with venous flow-related enhancement.

Intracranial dural arteriovenous fistula (DAVF) is a unique vascular malformation that is supplied by dural arteries and drains into venous sinuses or meningeal veins. It differs from pial arteriovenous malformation, in that "nidus" is not present in the

parenchyma and feeders should include the dural arteries. Although its pathogenesis remains unclear, a relation with venous sinus thrombosis has been repeatedly reported (1–4). One possible explanation for DAVF formation is that it develops as a result of a process of thrombosed sinus recanalization (1, 2).

Received December 29, 2004; accepted after revision May 13, 2005.

From the Department of Radiology, Seoul National University College of Medicine (B.J.K., M.H.H., K.H.C.), Seoul, Republic of Korea; Department of Neurosurgery, Konkuk University Hospital (H.S.K.), Seoul, Republic of Korea; Seoul National University Hospital, Clinical Research Institute (M.H.H., K.H.C.), Seoul, Republic of Korea; and Seoul National University Medical Research

Center, Institute of Radiation Medicine (M.H.H., K.H.C.), Seoul, Republic of Korea.

Address correspondence to Moon Hee Han, MD, Department of Radiology, Seoul National University College of Medicine, 28 Yongon-dong, Chongno-gu, Seoul 110-744, Republic of Korea.

© American Society of Neuroradiology

It is generally believed in DAVF patients that intracranial hemorrhages or other aggressive CNS symptoms—including focal neurologic deficits, seizures, intracranial hypertension, and altered mental status—are attributable to leptomeningeal venous drainage or passive venous hypertension (3, 5–10). Previous studies on DAVF classifications (5, 8, 11) have been based on venous drainage patterns evaluated by conventional angiography and showed that high-graded types with retrograde leptomeningeal venous drainage (RLVD) were related to aggressive neurologic symptoms. Contrary to numerous angiographic studies that have dealt with the involved vascular anatomy, or its pathogenesis and prognosis, relatively few investigations have reported MR imaging findings of intracranial DAVFs in the English-language literature (12–15). Moreover, available studies did not detail their findings or indicate how frequent these findings were. In addition to clarifying the MR imaging findings of DAVFs, it may also be clinically helpful to determine aggressiveness by MR imaging, because this may guide urgent angiography and prompt therapy to avoid intracranial hemorrhage or quickly recover this possibly treatable disease. For these reasons, we studied the MR imaging and MRA findings of DAVFs and sought to identify features predictive of the aggressive type.

Methods

The study population consisted of 27 intracranial DAVF patients who were diagnosed by conventional angiography and underwent MR imaging. There were 12 men and 15 women, ranging in age from 17 to 77 years, with a mean age of 52 years. We retrospectively reviewed the medical records, catheter angiographies, and the MR images of all 27 patients.

Medical records were reviewed with respect to demographic characteristics and presentations, which were characterized as aggressive or benign. Hemorrhage, focal neurologic deficits, seizures, intracranial hypertension, and altered mental status were considered aggressive presentations, and an isolated headache or ocular symptom was considered benign.

Catheter angiographies were thoroughly evaluated to determine DAVF location and to type DAVFs according to a previously proposed system (11)—ie, type I, venous sinus or meningeal vein outflow only; type II, venous sinus or meningeal vein outflow and RLVD; type III, RLVD only. All angiographies were performed in at least 2 orthogonal planes.

MR images were obtained with 1T ($n = 1$), 1.5T ($n = 25$), and 3T ($n = 1$) machines. Image acquisition was performed in at least 2 planes in all patients and with contrast enhancement in 25 patients. T1-weighted images were obtained by using the following parameters: repetition time (TR) of 500–800 msec and echo time (TE) of 15–30 msec, field of view of 18–24 cm, section thickness 3–5 mm, and a matrix of 256×256 or 256×192 . T2-weighted images were obtained by using the following parameters: TR/TE, 3500–5000/90–130; field of view, 18–24 cm; section thickness, 3–5 mm; matrix, 256×256 or 256×192 . Fluid-attenuated inversion recovery (FLAIR) or proton-attenuation sequences were available in some cases.

MRA was performed by using 3D time of flight (TOF; $n = 10$) or contrast-enhanced ($n = 1$) techniques after spin-echo (SE) imaging. The imaging parameters used for 3D TOF technique were as follows: TR/TE, 25–45/6.4–7.2 msec; flip angle, 20 or 25; field of view, 21 cm; partitions, 64; section thickness, 1.2–1.6 mm; matrix, 256×192 or 256×512 . Some of the contrast-enhanced MRA parameters were recorded on copy

films, all of which were TR/TE of 3.8/1.3 msec, field of view of 17.5×28 cm, section thickness of 1.6 mm, and matrix of 256×192 . Imaging processing was done by using the maximum-intensity-projection (MIP) algorithm. MRA evaluations were initially performed by using MIP collapsed orthogonal and oblique views.

The variables evaluated on examinations were as follows: on catheter angiograms, locations, and types; on MR imaging, flow void cluster near the dural venous sinus (Fig 1A, -B), engorged ophthalmic vein or proptosis (Fig 1C, -D), white matter hyperintensity (Fig 1E, -F), intracranial hemorrhage, dilated leptomeningeal or medullary vessels (Fig 1G, -H), venous pouch (Fig 1I, -J), and leptomeningeal or medullary vascular enhancements (Fig 1K, -L); and on MRA, identifiable fistula defined as a focal vascular tangle of flow-related enhancement near the dural venous sinus, venous flow-related enhancement, and prominent extracranial vessels (Fig 2A, -D). MR imaging and MRA were reviewed in a blinded fashion for DAVF locations and shunt amounts. These evaluations were performed by 2 neuroradiologists (B.J.K., M.H.H.), and discrepancies were resolved by discussion and consensus. Presentations and MR imaging findings of the type I, II, and III cases were compared, and MRA findings were compared between cases with and without RLVD (χ^2 test).

Results

Presentations were ocular symptoms ($n = 11$), tinnitus ($n = 5$), hemorrhage ($n = 8$), seizure ($n = 2$), focal neurologic deficit ($n = 3$), altered mentality ($n = 2$), and intracranial hypertension ($n = 1$). Combined presentations were also observed: ocular symptoms and tinnitus in 2, ocular symptoms and hemorrhage in one, hemorrhage and altered mentality in one, and hemorrhage and focal neurologic deficit in 2. One case was incidentally found by conventional angiography, which was performed as a preoperative examination for olfactory groove meningioma. In total, aggressive symptoms were present in 14 (52%) patients. One patient with intracranial hypertension presented with a progressively reducing visual acuity, for which the patient had consulted physicians several times, but intracranial hypertension was not diagnosed for 2 years, when a retinal examination showed papilledema (Fig 2E, -F).

DAVFs were solitary in 26 cases; these were located in the cavernous sinus ($n = 11$), transverse or sigmoid sinus ($n = 8$), superior sagittal sinus ($n = 2$), anterior skull base ($n = 1$), tentorium ($n = 2$), superior petrosal sinus ($n = 1$), and foramen magnum ($n = 1$). One multiple DAVF case had fistulas in the superior petrosal sinus, transverse-sigmoid sinus, and jugular bulb. By conventional angiography, 8 cases were type I, 12 type II, and 7 type III. In the multiple DAVF case, the transverse-sigmoid sinus fistula related to the presentation was chosen for typing. The cavernous sinus was the most common site for type I (75%) and type II (42%) cases. Three transverse-sigmoid sinus cases, 2 tentorial cases, one anterior skull base case with a varix, and one foramen magnum case with a varix belonged to type III. DAVF locations are illustrated with types in Table 1.

The time interval between MR imaging and conventional angiography was variable (range, 0–60 days; mean, 15 days) and was 7 days or fewer in 16

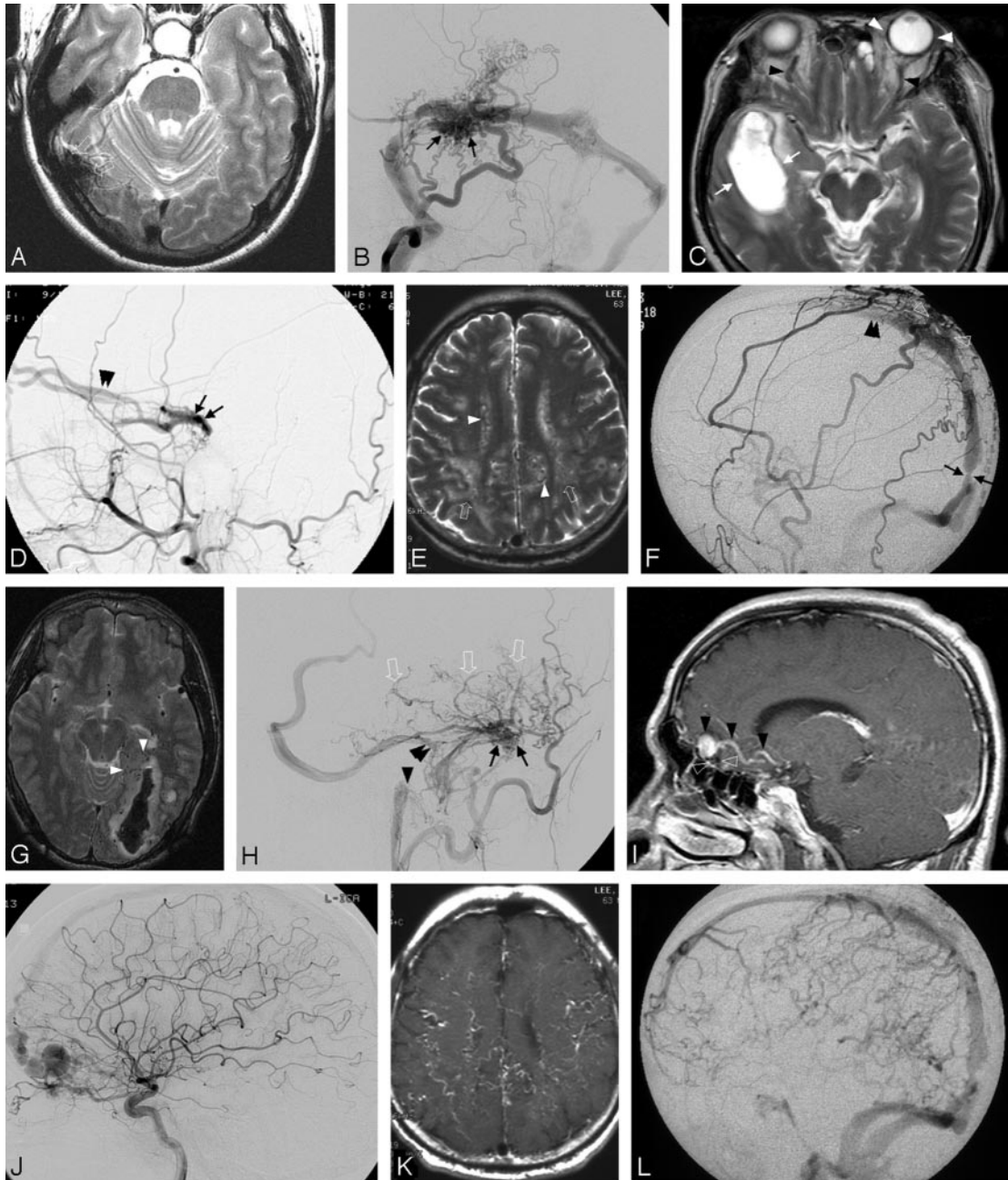


FIG 1. Various MR imaging findings of several intracranial dural arteriovenous fistulas.

A and B, T2-weighted axial image (A) shows a flow void cluster near the right transverse sinus (*open arrows*). The flow void cluster corresponds to a dural arteriovenous fistula itself (*black arrows*) on an oblique occipital arteriogram projection (B).

C and D, T2-weighted axial image (C) shows a subacute hematoma in the right temporal lobe (*white arrows*), engorged ophthalmic veins (*black arrowheads*), and proptosis on the left side (*white arrowheads*). Lateral projection of right external carotid angiogram (D) obtained a month after MR imaging reveals a cavernous dural arteriovenous fistula (*black arrows*) with only an anterior drainage pathway (*double arrowheads*) and no leptomeningeal venous drainage associated with hemorrhage. A posthemorrhagic spontaneous leptomeningeal venous regression may have occurred to show no leptomeningeal venous drainage despite the hemorrhagic event.

E and F, White matter hyperintensity (*open arrows*) is seen with dilated leptomeningeal or medullary vessels (*white arrowheads*) on T2-weighted image (E). Lateral projection of an external carotid angiogram reveals a superior sagittal sinus fistula (*open arrowheads*) fed by the superficial temporal, middle meningeal, and occipital arteries. The retrograde venous flow (*double arrowheads*) may be related to the stenotic segment just above the torcula herophilli (*black arrow*).

G and H, Acute occipital hematoma with adjacent dilated vessels (*white arrowheads*) is seen on T2-weighted image (G). Multiple dural arteriovenous fistulas are identified on occipital angiogram (H), which are present at the jugular bulb (*black arrowhead*), superior petrosal sinus (*double arrowheads*), and sigmoid sinus (*black arrows*). The fistula related to the occipital hematoma seems to be a sigmoid fistula because it develops multiple leptomeningeal venous reflux (*open arrows*).

I and J, Postcontrast T1-weighted sagittal image (I) shows an enhancing leptomeningeal vein with a varix (*black arrowheads*). Just below the varix a flow void cluster is also seen (*open arrowheads*). Internal carotid angiogram (J) reveals an anterior skull base fistula fed by the ethmoid artery and draining to the cortical veins and superior sagittal sinus.

K and L, These images belong to the same patient as panels E and F. Postcontrast T1-weighted axial image (K) shows prominent tortuous enhancing vessels. External carotid angiogram in the delayed phase (L) reveals severe cortical venous refluxes.

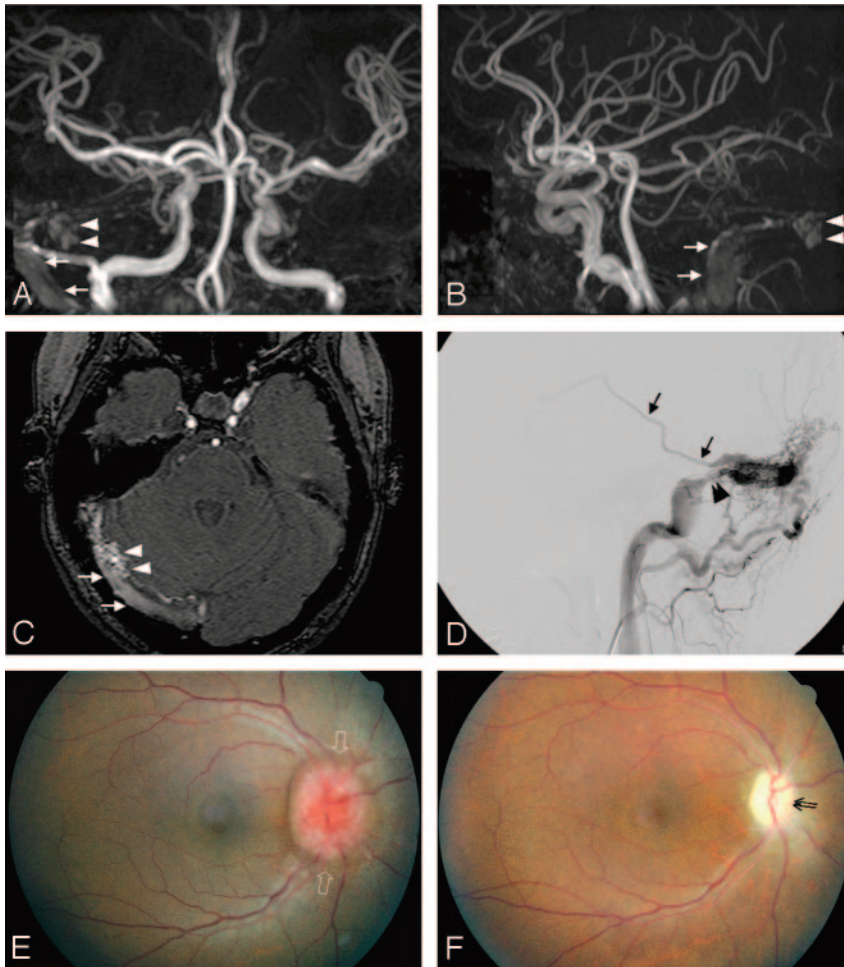


FIG 2. MR angiographic findings of dural arteriovenous fistula in a 41-year-old woman with progressive visual disturbance.

Flow-related enhancement of a fistula (white arrowheads) and the sigmoid sinus (white arrows) are seen on frontal and lateral 3-D TOF MRA maximum-intensity-projection views (A and B). Source image of MR angiography (C) well visualizes the fistula (white arrowhead) and sinus (white arrows) with flow-related enhancement. Lateral projection occipital angiogram (D) reveals a sigmoid sinus fistula with transosseous dural feeders (arrowheads), leptomeningeal venous drainage (black arrow), and sinus stenosis (double arrowheads). A fundoscopic examination obtained 3 months before (E) and after (F) the first session of endovascular treatment reveals papilledema (open arrows) and optic disk atrophy (double arrows). This patient eventually lost ipsilateral visual acuity and kept the contralateral visual acuity unchanged.

TABLE 1: Dural arteriovenous fistula location according to angiographic type

Dural Venous Sinus	Type I	Type II	Type III
Cavernous	6	5	—
Transverse/sigmoid	2	4	3
Superior sagittal	—	2	—
Superior petrosal	—	1	—
Tentorial	—	—	2
Anterior skull base	—	—	1
Foramen magnum	—	—	1

Note.—numerals indicate patient numbers.

cases, and >1 week in 11 cases. Of these 11 cases, 8 were symptomatically stationary during the time intervals and 3 already had intracranial hemorrhage on MR images and were stationary with conservative treatment during the interval.

Flow void clusters were observed in 22 (82%) by MR imaging. In 5 (18%) cases without flow void clusters, 2 were type I, 2 were type II, and 1 was type III. Engorged ophthalmic vein or proptosis was present in 8 (30%) cases on MR imaging, 7 of which were present in the cavernous sinus and one in the transverse-sigmoid sinus. The frequencies of the remaining findings were as follows: white matter hyperintensity, 4 (15%); intracranial hemorrhage, 8 (30%);

dilated leptomeningeal or medullary vessels, 12 (44%); venous pouch, 2 (7%); and leptomeningeal or medullary vascular enhancements, 11 (41%). On MRA the fistula was demonstrable in 5 (45%) cases, venous flow-related enhancement in 10 (91%), and prominent extracranial vessels in 4 (36%). Only a single case was false-negative on MIP MRA images, because it was determined by venous flow-related enhancement (8%). By contrast, no false-positive dural AVF was found at the other intracranial sites in all cases. Overall, MRA assessment for dural AVF was adequate for both fistula and venous flow-related enhancement in 10 cases (91%) and inadequate in a remaining case with contrast-enhanced MRA because of the fistular location out of field. In a false-negative case on MIP MRA images, source images of MRA were available and revealed venous flow-related enhancement. This case was of a cavernous sinus fistula with low flow and small amount of shunt by conventional angiography (Fig 3).

Aggressive presentations were more frequent with increasing type ($P = .002$): one (12%) in type I, 6 (50%) in type II, and 7 (100%) in type III. The MR imaging findings that were significantly different among types were dilated leptomeningeal or medullary vessels ($P < .001$) and leptomeningeal or medullary vascular enhancements ($P < .001$). Engorged ophthalmic vein or

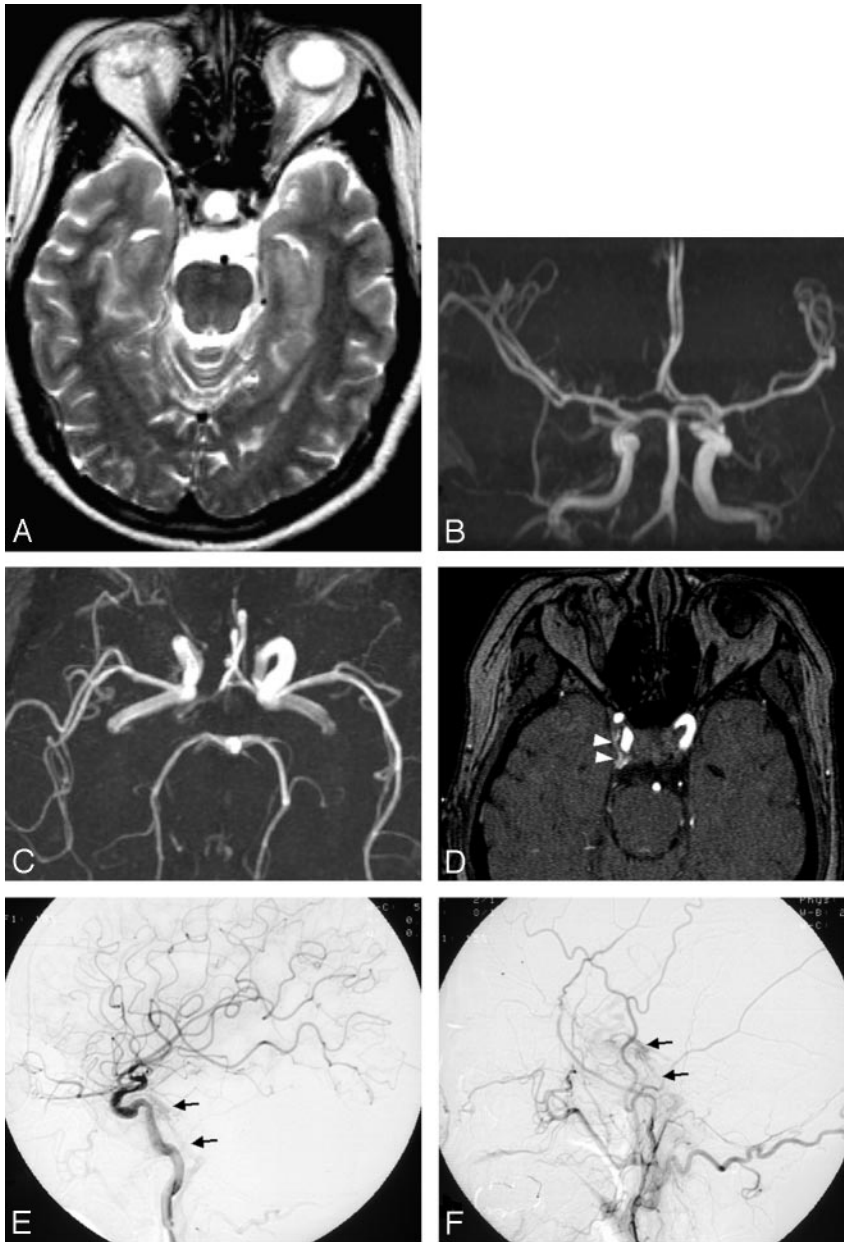


FIG 3. A false-negative case on MRA maximum-intensity-projections; 57-year-old woman with diplopia and ptosis.

T2-weighted axial (A), and frontal (B) and superior (C) 3D TOF MRA maximum-intensity-projections show no evidence of dural arteriovenous fistula. Only MRA source image (D) reveals the fistula with flow-related enhancement of the right cavernous sinus (white arrowheads). The cavernous and inferior petrosal sinuses (black arrows) are demonstrated with slowly shunted, faint contrast filling on lateral projections of internal and external carotid angiographies (E and F).

ptosis was most frequent (6 cases) in type II (50%), 5 of which were located in the cavernous sinus. This, however, was not seen at all in type III. White matter hyperintensity ($n = 4$) always accompanied dilated cortical or medullary vessels ($n = 12$) and leptomeningeal or medullary vascular enhancements ($n = 11$). These results are summarized in Table 2. Only an identifiable fistula by MRA was found to be significantly frequent ($P = .015$) and to be present only in cases with RLVD (67%). Prominent extracranial vessels also showed marginal significance ($P = .061$). MRA findings are summarized in Table 3.

Discussion

Intracranial DAVF, a treatable vascular disease, accounts for 10%–15% of all intracranial vascular malformations (16). Although several studies have

reported spontaneous regression or rare conversion to aggressive type in a benign DAVF (17–19), a DAVF with RLVD and aggressive neurologic symptoms necessitates a prompt treatment. Despite its reversibility by various treatment modalities—including conservative (20), endovascular (21), surgical (22), radiation (23), or combined (24) therapies—it may be difficult to diagnose DAVF at an early stage in clinical practice because of its nonspecific clinical and imaging findings. The clinical features of DAVFs range from mild complaints such as headache, vertigo, or tinnitus to disabling neurologic deficits or a life-threatening intracranial hemorrhage (8). Likewise, the spectrum of MR imaging findings is also variable, ranging from no demonstrable lesion to intracranial hemorrhage or venous infarction (12, 13). A high index of suspicion for the possibility of a DAVF is warranted when one is confronted with an

TABLE 2: Presentations and MR imaging findings of intracranial dural arteriovenous fistula according to angiographic type*

	Type I (n = 8)	Type II (n = 12)	Type III (n = 7)
Presentations*			
Aggressive	1 (12)	6 (50)	7 (100)
Nonaggressive	7 (88)	6 (50)	0
MR imaging findings			
Flow void clustering	6 (75)	10 (83)	6 (86)
Engorged OV/proptosis	2 (25)	6 (50)	0
WM hyperintensity	0	1 (8)	3 (43)
Hemorrhage	1 (13)	4 (33)	3 (43)
Dilated vessels*	0	5 (42)	7 (100)
Venous pouch	0	0	2 (29)
Vascular enhancement*	0	4 (33)	7 (100)

Note.—Types as classified by Borden et al (11). OV indicates ophthalmic vein; WM, white matter. Numbers in parentheses are percentages.

* $P < .05$.

TABLE 3: MR angiographic findings of intracranial dural arteriovenous fistula with and without retrograde leptomeningeal venous drainage

	RLVD Absence (n = 5)	RLVD Presence (n = 6)
Identifiable fistula*	0	5 (83)
Flow-related enhancement	4 (80)	6 (100)
Prominent extracranial vessel	0	4 (67)

Note.—RLVD indicates retrograde leptomeningeal venous drainage. Numbers in parentheses indicate percentages.

* $P < .05$.

unexplainable constellation of neurologic complaints and deficits.

To the best of our knowledge, no large-scale analysis of the MR imaging features of DAVFs is available in the English-language literature. De Marco et al (12), in a 12-case study, concluded that dilated cortical veins without a parenchymal nidus on MR images are suggestive of DAVF with venocclusive disease. They also described that dilated cortical veins were observed on MR imaging in all angiographically proved cases but failed to directly identify the fistula by MR imaging. In addition, they described venous infarct, hemorrhage, or hydrocephalus as DAVF-related complications. In other words, DAVF might not be detected without the presence of a dilated cortical vein, hemorrhage, or parenchymal change on MR imaging. These findings seem to be more directly associated with complications of venous hypertension than DAVF. Unlike De Marco et al (12), Chen et al (13) pointed out that a fistula was directly visualized by MR imaging in 4 and by MRA in 6 of 7 patients. They regarded the fistula as a slightly irregular region of flow voids on MR imaging or as flow-related enhancement along the involved sinus on MRA, and confirmed this by conventional angiography. Our results also show high frequencies of direct fistula visualization regardless of DAVF type (75%–86%). We should, however, add that this may have been related to the fact that our reviewers were informed in ad-

vance of the presence of DAVFs. Nevertheless, our results suggest that any suspicious flow void cluster around the dural venous sinus should alert one to the possibility of DAVF, and lead to further work-up—ie, MRA and conventional angiography.

RLVD has been reported to be associated with aggressive symptoms in DAVF patients (3, 6, 7–11). This association was also validated by a single-center study that tested the validities of 2 proposed classification schemes based on venous drainage patterns (25). Our results are also in accord with these previous observations. Type II and III cases with RLVD showed aggressive symptoms more frequently than type I cases—ie, 6 (50%) and 7 (100%) versus one (12%). All 6 aggressive type II cases were noncavernous sinus fistulas, and the 5 remaining nonaggressive cases were cavernous sinus fistulas. Therefore, all cavernous sinus DAVFs resulted in nonaggressive presentations, even in type II. The variable anatomies of cavernous sinus drainage routes—which include orbital, inferior petrosal, or midline-crossing venous drainages—may explain the nonaggressive presentations of cavernous sinus DAVFs. Orbital venous drainage and the ensuing ocular symptoms may lead to the early detection of DAVFs before venous hypertension develops through the RLVD system; moreover, the presence of various drainage routes may reduce venous hypertension by dividing venous outflow. In addition, the fact that our cases had no superior petrosal sinus drainage might have played a role in the nonaggressive presentations of all cavernous sinus cases, because CNS symptoms in cavernous DAVFs are highly associated with superior petrosal sinus drainage (26).

It is generally more efficacious to detect and treat DAVF before aggressive symptoms manifest than to recover DAVF patients with aggressive presentations. In our cases, there was such a case of type II superior sagittal sinus DAVF. The chief complaints in this case were of tinnitus and palpable cordlike lesions in the scalp; no aggressive symptoms or signs were present. Conventional angiography showed a type II superior sagittal sinus DAVF. MR imaging was normal but showed a flow void cluster in the vicinity of the superior sagittal sinus. After one session of transvenous endovascular treatment, the fistula disappeared and the patient became asymptomatic without any complication. In contrast with this case, all other type II noncavernous and type III cases were diagnosed when they presented with aggressive symptoms.

Our study shows that the MR imaging findings of DAVFs are closely related to type, and, the higher the type, the more common the findings such as white matter hyperintensity, hemorrhage, dilated vessels, venous pouch, and vascular enhancement; however, only 2 of these findings—namely, dilated vessels and prominent vascular enhancements—were found to be significantly frequent in increasing type. Although all type II and III cases, particularly with aggressive symptoms, had at least one of the above findings, most type I and II cases with nonaggressive symptoms showed only flow void clustering, an engorged oph-

thalmic vein, or proptosis. Therefore, if dilated vessels or prominent vascular enhancements are present on MR imaging, there is a high probability of type II or III with RLVD, and the patient concerned requires a prompt examination by conventional angiography.

We believe that dilated leptomeningeal or medullary vessels may be RLVDs or congested medullary veins related to venous hypertension. The medullary veins on MR imaging may be associated with a pseudophlebitic pattern on conventional angiography, which is seen during the venous phase and reflects venous congestion and is related to an aggressive presentation and white matter T2 hyperintensity (27). Had our study population been larger, white matter hyperintensity might have been identified as a distinguishing feature among type I, II, and III cases, but it had marginal significance only in the present study ($P = .06$). White matter hyperintensity seems to be a relatively late-presenting feature because all white matter hyperintensity cases ($n = 4$) had dilated vessels ($n = 12$) and prominent vascular enhancements ($n = 11$) on MR imaging, but not vice versa.

The role of MRA in diagnosing DAVFs is to improve noninvasive screening by detecting flow-related enhancement (13, 14). In addition, phase-contrast MRA may enable the more confident identification of dural sinus stenosis or of occlusion with low-velocity encoding and may provide an effective way of assessing venous flow reversal with phase reconstruction (14). We analyzed flow-related enhancement in 2 separate parts—ie, the fistula and venous structure—and identified a fistula in about a half of all cases. Fistular flow-related enhancement was not present in type I cases but was found in some type II or III cases with RLVD and was the only statistically significant finding capable of distinguishing cases with and without RLVD. This significance might be related to a confounding factor because cavernous sinus DAVFs with relatively low flow shunts and fine feeders were more frequent in cases without RLVD than in cases with RLVD (80% vs 17%). In contrast to the fistular flow-related enhancement, venous flow-related enhancement was observed in most cases (91%) and in all cases if additionally evaluated by using MRA source images. The lack of venous flow-related enhancement in one case was presumed to be associated with a low flow status in the cavernous sinus DAVF. Therefore, regardless of location, DAVFs would be better appreciated on MRA by detecting venous flow-related enhancement.

With the advent of more advanced interventional devices and techniques during the past decade, increasing reliance is being placed on endovascular therapy as a first-line treatment. DAVF is a treatable disease, but is undetectable in some cases and this eventually leads to irreversible disease because of the diagnostic delay. In light of a high index of suspicion, MR images should be scrutinized for a flow void cluster and for flow-related enhancement, which are the most common MR imaging and MRA findings, respectively. In particular, if dilated leptomeningeal or medullary vessels and prominent vascular en-

hancements are present on MR images, prompt conventional angiography and endovascular treatment, if indicated, should be performed.

References

1. Chaudhary MY, Sachdev VP, Cho SH, et al. **Dural arteriovenous malformation of the major venous sinuses: an acquired lesion.** *AJNR Am J Neuroradiol* 1982;3:13–19
2. Graeb DA, Dolman CL. **Radiological and pathological aspects of dural arteriovenous fistulas.** *J Neurosurg* 1986;64:962–967
3. Awad IA, Little JR, Akrawi WP, Ahl J. **Intracranial dural arteriovenous malformations: factors predisposing to an aggressive neurological course.** *J Neurosurg* 1990;72:839–850
4. Mullan S. **Reflections upon the nature and management of intracranial and intraspinal vascular malformations and fistulae.** *J Neurosurg* 1994;80:606–616
5. Djindjian R, Merland JJ, Theron J. **Superselective arteriography of the external carotid artery.** New York: Springer-Verlag;1977: 606–628
6. Malik GM, Pearce JE, Ausman JJ, Mehta B. **Dural arteriovenous malformations and intracranial hemorrhage.** *Neurosurgery* 1984; 15:332–339
7. Lasjaunias P, Chiu M, ter Brugge K, et al. **Neurological manifestations of intracranial dural arteriovenous malformations.** *J Neurosurg* 1986;64:724–730
8. Cognard C, Gobin YP, Pierot L, et al. **Cerebral dural arteriovenous fistulas: clinical and angiographic correlation with a revised classification of venous drainage.** *Radiology* 1995;194:671–680
9. Tsai LK, Jeng JS, Liu HM, et al. **Intracranial dural arteriovenous fistulas with or without cerebral sinus thrombosis: analysis of 69 patients.** *J Neurol Neurosurg Psychiatry* 2004;75:1639–1641
10. Biondi A, Casasco A, Houdart E, et al. **Evolution of angiographic signs of venous hypertension and clinical signs of intracranial hypertension in intracranial dural arteriovenous fistulas.** *J Neuro-radiol* 1999;26:49–58
11. Borden JA, Wu JK, Shucart WA. **A proposed classification for spinal and cranial dural arteriovenous fistulous malformations and implications for treatment.** *J Neurosurg* 1995;82:166–179
12. De Marco JK, Dillon WP, Halbach VV, Tsuruda JS. **Dural arteriovenous fistulas: evaluation with MR imaging.** *Radiology* 1990; 175:193–199
13. Chen JC, Tsuruda JS, Halbach VV. **Suspected dural arteriovenous fistula: results with screening MR angiography in seven patients.** *Radiology* 1992;183:265–271
14. Cellerini M, Mascialchi M, Mangiafico S, et al. **Phase-contrast MR angiography of intracranial dural arteriovenous fistulae.** *Neuroradiology* 1999;41:487–492
15. Panasci DJ, Nelson PK. **MR imaging and MR angiography in the diagnosis of dural arteriovenous fistulas.** *Magn Reson Imaging Clin N Am* 1995;3:493–508
16. Newton TH, Cronqvist S. **Involvement of dural arteries in intracranial arteriovenous malformation.** *Radiology* 1969;93:1071–1078
17. Luciani A, Houdart E, Mounayer C, et al. **Spontaneous closure of dural arteriovenous fistulas: report of three cases and review of the literature.** *AJNR Am J Neuroradiol* 2001;22:992–996
18. Olutola PS, Eliam M, Molot M, Talalla A. **Spontaneous regression of a dural arteriovenous malformation.** *Neurosurgery* 1983; 12:687–690
19. Satomi J, van Dijk JMC, ter Brugge KG, et al. **Benign cranial dural arteriovenous fistulas: outcome of conservative management based on the natural history of the lesion.** *J Neurosurg* 2002;97:767–770
20. Halbach VV, Higashida RT, Hieshima GB, et al. **Dural fistulas involving the cavernous sinus: results of treatment in 30 patients.** *Radiology* 1987;163:437–442
21. Dawson RC 3rd, Joseph GJ, Owens DS, Barrow DL. **Transvenous embolization as the primary therapy for arteriovenous fistulas of the lateral and sigmoid sinuses.** *AJNR Am J Neuroradiol* 1998;19:571–576
22. Sundt TM Jr., Piepgras DG. **The surgical approach to arteriovenous malformations of the lateral and sigmoid dural sinuses.** *J Neurosurg* 1983;59:32–39
23. O'Leary S, Hodgson TJ, Coley SC, et al. **Intracranial dural arteriovenous malformations: results of stereotactic radiosurgery in 17 patients.** *Clin Oncol (R Coll Radiol)* 2002;14:97–102
24. Friedman JA, Pollock BE, Nichols DA, et al. **Results of combined**

- stereotactic radiosurgery and transarterial embolization for dural arteriovenous fistulas of the transverse and sigmoid sinuses. *J Neurosurg* 2001;94:886–891**
25. Davies MA, ter Brugge K, Willinsky R, et al. **The validity of classification for the clinical presentation of intracranial dural arteriovenous fistulas.** *J Neurosurg* 1996;85:830–837
26. Stiebel-Kalish H, Setton A, Nimii Y, et al. **Cavernous sinus dural arteriovenous malformations: patterns of venous drainage are related to clinical signs and symptoms.** *Ophthalmology* 2002; 109:1685–1691
27. Willinsky R, Goyal M, ter Brugge K, Montanera W. **Tortuous, engorged pial veins in intracranial dural arteriovenous fistulas: correlations with presentation, location, and MR findings in 122 patients.** *AJNR Am J Neuroradiol* 1999;20:1031–1036