AJNR

This information is current as of October 11, 2024.

Bifid Mandibular Condyle: CT and MR Imaging Appearance in Two Patients: Case Report and Review of the Literature

Jabi Shriki, Raisa Lev, Brian F. Wong, Michael J. Sundine and Anton N. Hasso

AJNR Am J Neuroradiol 2005, 26 (7) 1865-1868
http://www.ajnr.org/content/26/7/1865

AJNR Am J Neuroradiol 26:1865–1868, August 2005

Case Report

Bifid Mandibular Condyle: CT and MR Imaging Appearance in Two Patients: Case Report and Review of the Literature

Jabi Shriki, Raisa Lev, Brian F. Wong, Michael J. Sundine, and Anton N. Hasso

Summary: We describe two cases of a bifid mandibular condyle. The first case is a 48-year-old woman with headaches and a pain and clicking sensation in her right jaw during mastication. The second case is an asymptomatic 17-year-old woman with a history of bilateral microtia and hemifacial microsomia. In both patients, the bifid condyle was first identified by CT and affected the temporomandibular joint. The imaging findings of both patients' bifid mandibular condyles led us to conclude that both patients likely had an abnormal development of the mandibular condyles. We believe that an intervening fibrous or vascular structure may have split the condyle into two heads.

The presence of a bifid mandibular condyle is a rare condition (1–5), most commonly reported as an incidental, unilateral finding (1, 6–8). More cases have been identified on autopsy than in clinical settings (6). Reported cases of the bifid mandibular condyles in living subjects have been reported in asymptomatic patients and in association with temporomandibular joint (TMJ) ankylosis (7, 8). Our review of literature identified only 56 cases of this rare anomaly (Table). There has been only one case report of a bifid mandibular condyle in association with the hemifacial microsomia, which was identified in our second patient (9).

Herein, we report two subjects with a bifid mandibular condyle. CT identified duplication of the condylar head in both cases; furthermore, MR imaging was used to further characterize the meniscus of the affected TMJ.

Cases of bifid condyles reported in literature

	Living Cases	Cadaveric Cases
Hrdlicka (1941) (1)		21
Sicher (1948) (2)	1	
Moffett (1966) (3)		1
Stadnicki (1971) (15)	1	1
Lysell and Oberg (1975) (4)	1	
Farmand (1981) (5)	1	
Forman and Smith (1984) (6)	2	
Balciunas (1986) (12)	1	
Thomason and Yusuf (1986) (11)	2	
Gundlach et al (1987) (7)	4	1
Zohar and Laurian (1987) (9)	1	
Sahm and Witt (1989) (16)	1	
Szenpetery et al (1990) (8)		7
Phillips and Delzer (1992) (17)	1	
Antoniades et al (1993) (18)	1	
Fields and Frederiksen (1993) (19)	1	
Cowan and Ferguson (1993) (20)	1	
Stephanou et al (1998) (21)	4	
Garcia-Gonzalez et al (2000) (22)	1	
Totals	24	32

Case Reports

Case 1

The patient was a 45-year-old woman with a history of headache that lasted several hours in duration and occurred multiple times a week for several years. She described poorly localized pain, which radiated throughout her head. During a particularly severe episode, the patient presented to an emergency department and underwent head CT imaging. The study revealed a right mandible with two condylar processes with a side-by-side orientation, one medially and the second laterally. The patient was asked to return for further imaging. Follow-up axial (Fig 1*A*) and coronal (Fig 1*B*) images of the mandible better demonstrated the medial and lateral condylar heads of the affected side. These images further demonstrated the two articulating facets in the right temporomandibular fossa, each articulating with one of the condylar processes. On further questioning, the patient revealed that she experienced a clicking sensation near the right TMJ with chewing. The patient also recalled intermittent TMJ pain following meals requiring excessive mastication. She described bilateral pain, more severe on the right. The patient also admitted to favoring her left side during chewing. The patient denied any history of bruxism or problems swallowing. Review of the family history and discussion with family members failed to elucidate similar symptoms in other members of the family.

The additional MR imaging study identified atrophy and fatty replacement of the muscles of mastication, including both of the pterygoid muscles, the masseter, and the lower temporalis muscles on the right side, as compared with the unaffected, contralateral side (Fig 1*C*). Marrow edema was seen in the duplicated right condylar heads but was more prominent in the lateral head. The meniscus of the affected TMJ was T-shaped with a separate limb for each of the condylar heads. A third limb of the meniscus was seen interdigitating between the two mandibular heads (Fig 1*D*).

Received June 7, 2004; accepted October 7.

From the Departments of Radiological Sciences (J.S., R.L., A.N.H.), Otolaryngology/Head and Neck Surgery (B.F.W.), and Plastic Surgery (M.T.S.), University of California, Irvine Medical Center, Irvine, CA.

Address correspondence to Anton N. Hasso, MD, Department of Radiological Services, University of California at Irvine Medical Center, 101 City Drive South, Route 140, Orange, CA 92668-3298.

© American Society of Neuroradiology

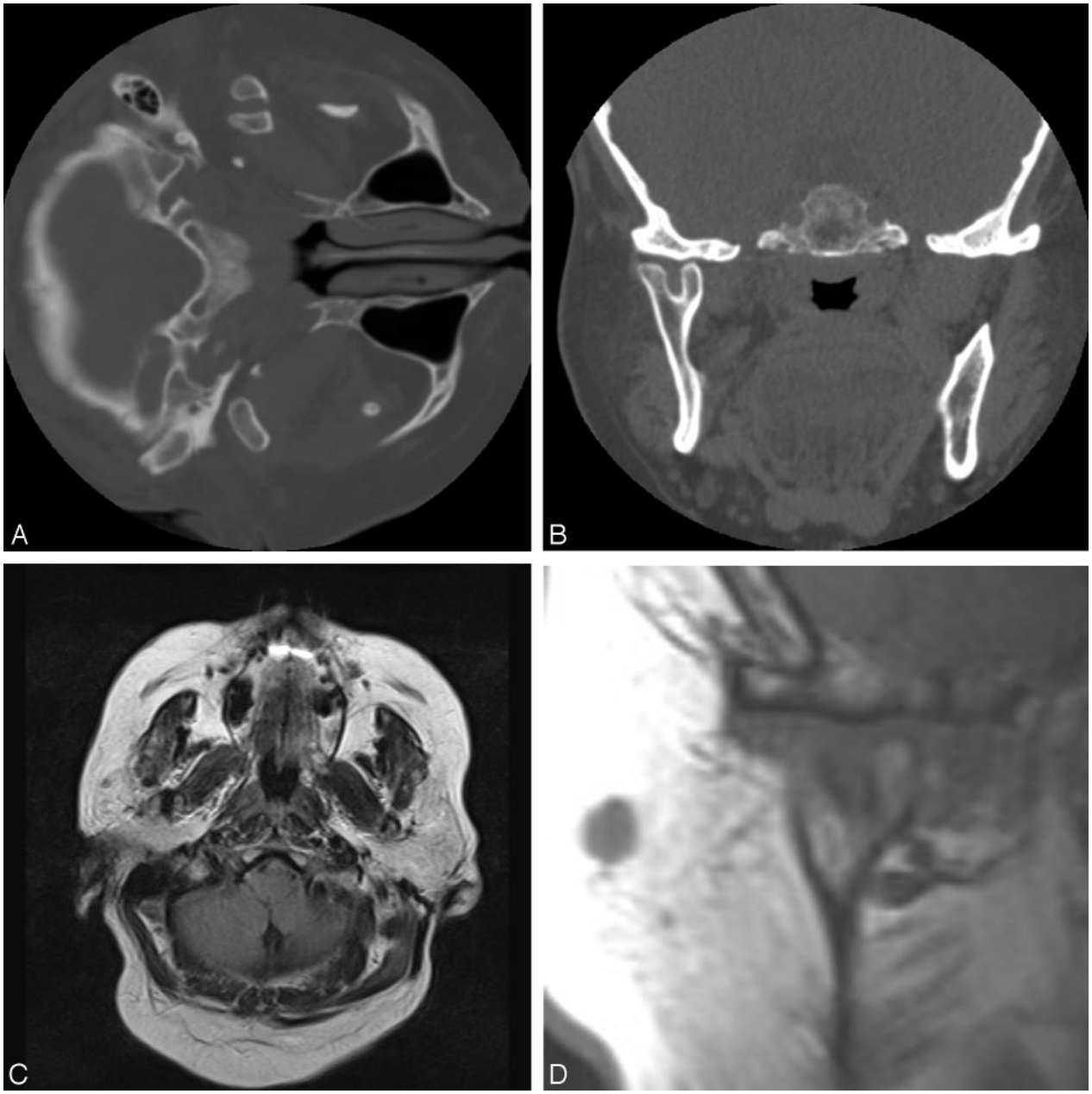

FIG 1. Axial (*A*) and coronal (*B*) thin-cut CT images through the mandible demonstrate a bifid mandibular condyle on the right side with mediolaterally oriented heads.

C, Axial, T1-weighted MR imaging demonstrates the bifid mandibular condyle on the right side, but also demonstrates subtle fatty atrophy of the muscles of mastication ipsilaterally.

D, Coronal T1-weighted MR imaging images demonstrate the bifid condyle on the right side and also demonstrate that the meniscus has the shape of a T, with a third limb interdigitating between the two mandibular heads.

Case 2

The second patient was a 17-year-old woman from Bolivia with left hemifacial microsomia and bilateral microtia, who sought treatment for her facial asymmetry. CT of the temporal bones was requested for the surgical planning. The left mandibular condyle was noted to have an aberrant small medial condyle in addition to a larger, lateral condyle (Figs 2*A–D*). Further questioning failed to elicit any symptoms referable to her TMJ. Additional CT findings included the bilateral, complete atresia of the external auditory canals with abnormalities of the middle ear structures, including the opacified mastoid air cells, a small epitympanic recess, and the malformed, hypoplastic ossicles.

The patient's past surgical history was significant for prior auricular reconstructions in 1992 and 1994 and also mandibular distraction osteogenesis. The limited records and operative reports from Bolivia made no specific mention of any mandibular abnormalities.

Discussion

Duplication of the mandibular condyle is exceptionally rare. The study of 1,882 cadaveric skulls by Szentpetery et al found the incidence of this anomaly to be 0.48% (8). Two differing theories have been

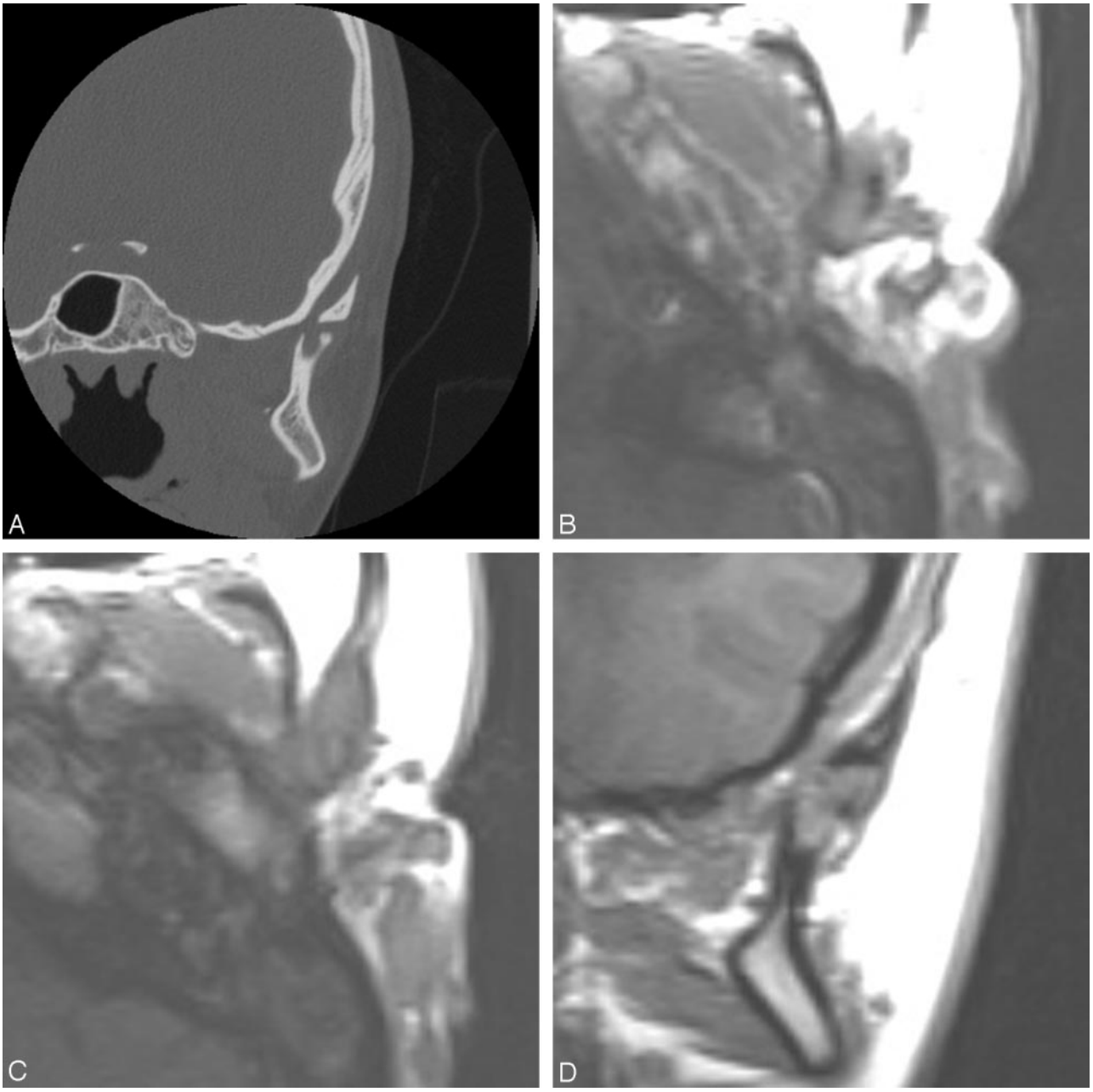

FIG 2. *A,* Coronal thin-cut CT images demonstrate that the left mandibular condyle is bifid, with mediolaterally oriented heads. Although both mandibular heads are small and deformed, the left is much smaller than the right.

B and *C,* Axial, T1-weighted MR imaging images again demonstrate the bifid mandibular condyle.

D, Coronal images demonstrate the mediolaterally oriented heads and also show the T-shaped meniscus, with the descending limb of the T interdigitating between the mediolaterally oriented heads.

postulated to account for the pathogenesis of the mandibular condyle duplication. Blackwood (10) and Moffett (3) have suggested that a retained fibrous septum or a vascular structure impede ossification of the mandible, splitting the condyle into two heads. By contrast, Thomason and Yusuf (11) have suggested prior trauma as a cause; however, the duplication has been described in patients without any antecedent identifiable traumatic event (1–3, 6).

The orientation of the mandibular head has been used as a differentiating factor. The mediolateral orientation is presumed to result from a developmental cause; however, a sagittal split with anteroposterior orientation has been associated with an antecedent identifiable, traumatic event (2, 6, 8, 12). Yao et al, however, demonstrated experimentally that a fracture of the mandibular condyle could result in mediolateral (13) as well as anteroposterior orientation (14) of the mandibular condyles.

We tend to support the hypothesis that a bifid condyle with mediolateral heads is likely to be related to a developmental phenomenon rather than trauma. Neither patient in this study had identifiable traumatic injury or duplicated condylar heads with me-

diolateral orientation. The association of the anomaly in the second patient with a rare hemifacial microsomia also prompts us to conclude that the cause for her duplicated condylar head is likely to be developmental.

In the past, duplication of the mandibular condyle had been described on conventional radiographs, mostly panorex views (4, 6, 8, 15). The panorex views often demonstrated the two mandibular heads with either anteroposterior orientation, as in the case of traumatically induced bifid mandibular condyle, or mediolateral in the setting of a presumed developmental abnormality. Conventional radiographs of the mandible were not available for either of our patients, because of their clinical histories and presentations. To the best of our knowledge, this report is the first description of a T-shaped meniscus and the first depiction of the MR imaging appearance of the bifid mandibular condyle in the English-language medical literature.

According to the Blackwood's postulate, a band of vascular or fibrous tissue should have been identified between the two condylar heads on MR imaging (10). The lack of MR imaging visualization of a fibrous band or of an abnormal vascular structure would contradict this hypothesis. The fibrous or vascular tissue, however, may have been present in the embryonic period before the ossification of the mandibular condyle but regressed later in the development.

Conclusion

We believe this case report to be only the second reported association of hemifacial microsomia and the bifid mandibular condyle (9). Further cases may be identified with a more systematic imaging approach to patients with hemifacial microsomia. In the future, the mandibular condyle may come under closer scrutiny during the reviews of these imaging studies.

We have herein reported two patients with a bifid mandibular condyle. A study of a series of patients with hemifacial microsomia would be helpful to evaluate the true prevalence of the bifid mandibular condyle as part of a syndromic association or predisposition. Although, the panorex views have been traditionally used for diagnosis, With CT imaging becoming more common, CT scans rather than conventional radiographs were used to diagnose our patients. We believe that special attention should be given to the mandible in patients with any referable symptoms. MR imaging evaluation in the identified patients may reveal other variants of the meniscal shape or potentially confirm the T-shaped meniscus, seen in our patient, as a common finding in patients with a bifid condyle.

References

1. Hrdlicka A. **Lower jaw: double condyles.** *Am J Phys Anthropol* 1941;28:75–89
2. Sicher MBA. **The temporomandibular joint: a consideration of its probable functional and dysfunctional sequelae and report: condyle-double head—in a living person.** *Dent Items Interest* 1948;70:1100
3. Moffett B. **The morphogenesis of the mandibular joint.** *Am J Orthod* 1966;52:401–415
4. Lysell G, Oberg T. **Unilateral doubling of mandibular condyle.** *Dentomaxillofac Radiol* 1975;4:95–98
5. Farmand M. **Mandibular condyle head duplication.** *J Maxillofac Surg* 1981;9:59–60
6. Forman GH, Smith NJD. **Bifid mandibular condyle.** *Oral Surg* 1984;57:371–373
7. Gundlach KKH, Furman A, Beckmann-Van derVen G. **The double-headed mandibular condyle.** *Oral Surg Oral Med Oral Pathol* 1987;64:249–253
8. Szentpetery A, Gabor K, Marcsik A. **The problem of the bifid mandibular condyle.** *J Oral Maxillofac Surg* 1990;48:1254–1257
9. Zohar Y, Laurian N. **Bifid condyle of the mandible with associated polythelia and manual anomalies.** *J Laryngol Otol* 1987;101:1315–1319
10. Blackwood HJJ. **The double-headed mandibular condyle.** *Am J Phys Anthropol* 1957;15:1–8
11. Thomason JM, Yusuf H. **Traumatically induced bifid mandibular condyle: report of two cases.** *Br Dent J* 1986;161:291–293
12. Balciunas BA. **Bifid mandibular condyle.** *J Oral Maxillofac Surg* 1986;44:324–325
13. Yao J, Zhou J, Hu M. **Comparative experimental study between longitudinal fracture and transverse fracture of mandibular condyle.** *Zhonghua Kou Qiang Yi Xue Za Zhi* 1999;34:178–180
14. Wang Y, Yao J, Zhou J, et al. **Experimental study of sagittal fracture of the mandibular condyle.** *Chin J Dent Res* 1999;2:38–43
15. Stadnicki G. **Congenital double condyle of the mandible causing temporomandibular ankylosis: report of case.** *J Oral Surg* 1971;29:208–211
16. Sahm G, Witt E. **Long-term results after childhood condylar fractures: a computer-tomographic study.** *Eur J Orthod* 1989;11:154–160
17. Phillips JD, Delzer DD. **Unilateral bifid mandibular condyle.** *Gen Dent* 1992;40:425
18. Antoniades K, Karakasis D, Elephtheriades J. **Bifid mandibular condyle resulting from a sagittal fracture of the condylar head.** *Br J Oral Maxillofac Surg* 1993;31:124–126
19. Fields R, Frederiksen NL. **Facial trauma confusing the diagnosis of a bifid condyle.** *Dentomaxillofac Radiol* 1993;22:216–217
20. Cowan DF, Ferguson MM. **Bifid mandibular condyle.** *Dentomaxillofac Radiol* 1993;227:70–73
21. Stefanou EP, Fanourakis IG, Vlaskos K, Katerelou J. **Bilateral bifid mandibular condyles: report of four cases.** *Dentomaxillofac Radiol* 1998;27:186–188
22. Garcia-Gonzalez D, Martin-Granizo R, Lopez P. **Imaging quiz case 4: bifid mandibular condyle.** *Arch Otolaryngol Head Neck Surg* 2000;126:798–789