

**Are your MRI contrast agents cost-effective?**

Learn more about generic Gadolinium-Based Contrast Agents.



**FRESENIUS  
KABI**

caring for life

**AJNR**

**Comparison of Technetium Tc 99m  
Hexamethylpropyleneamine Oxime  
Single-Photon Emission Tomograph with  
Stump Pressure During the Balloon  
Occlusion Test of the Internal Carotid Artery**

This information is current as  
of April 10, 2024.

Noriaki Tomura, Koichi Omachi, Satoshi Takahashi, Ikuo  
Sakuma, Takahiro Otani, Jiro Watarai, Kazuo Ishikawa,  
Hiroyuki Kinouchi and Kazuo Mizoi

*AJNR Am J Neuroradiol* 2005, 26 (8) 1937-1942

<http://www.ajnr.org/content/26/8/1937>

# Comparison of Technetium Tc 99m Hexamethylpropyleneamine Oxime Single-Photon Emission Tomograph with Stump Pressure During the Balloon Occlusion Test of the Internal Carotid Artery

Noriaki Tomura, Koichi Omachi, Satoshi Takahashi, Ikuo Sakuma, Takahiro Otani, Jiro Watarai, Kazuo Ishikawa, Hiroyuki Kinouchi, and Kazuo Mizoi

**BACKGROUND AND PURPOSE:** Measuring blood pressure (stump pressure) in the distal internal carotid artery during occlusion of the internal carotid artery is reportedly a reliable safety index with which to predict ischemia following permanent occlusion of the internal carotid artery. We compared the stump pressure during occlusion of the internal carotid artery with single-photon emission CT (SPECT) using technetium Tc 99m hexamethylpropyleneamine oxime (HMPAO).

**METHODS:** Twenty-seven patients underwent the balloon occlusion test. After occlusion of the internal carotid artery was performed by a balloon catheter, technetium Tc 99m HMPAO was injected, and then the balloon remained inflated for 15 minutes. The stump pressure was continuously monitored for those 15 minutes. After the balloon catheter was deflated and removed, SPECT was performed. Sixty-four symmetric pairs of regions of interest were set on both sides of the cerebral hemisphere. The radioactivity count ratio (L/n ratio) of the occluded side to the contralateral normal side was calculated. We defined hypoperfusion as an area with an L/n ratio  $<0.8$ . The minimum mean stump pressure (minMSP) during the balloon occlusion test and the pressure ratio of the minMSP to the mean systemic pressure were compared with the hypoperfusion area on SPECT.

**RESULTS:** The number of regions of interest with hypoperfusion was significantly ( $P < .001$ ) greater in patients with a minMSP  $<40$  mm Hg (mean  $[\pm SD] = 31.5 \pm 13.7$ ) than in patients with a minMSP  $\geq 40$  mm Hg ( $5.1 \pm 4.0$ ). The number of regions of interest with hypoperfusion was also significantly ( $P < .001$ ) greater in patients with a pressure ratio  $<0.5$  ( $26.7 \pm 15.8$ ) than in patients with a pressure ratio  $\geq 0.5$  ( $4.5 \pm 3.5$ ).

**CONCLUSION:** The minMSP during the balloon test occlusion reflects the extent of the hypoperfused area measured by SPECT using technetium Tc 99m HMPAO.

Occlusion of the internal carotid artery is often necessary to treat inoperable internal carotid aneurysms, stenotic or ulcerative carotid disease, and tumors invading the internal carotid artery (1–3). The balloon occlusion test of the internal carotid artery has been

used to predict whether a patient can tolerate temporary or permanent occlusion of the internal carotid artery. Previous reports have proposed various techniques to predict the likelihood of ischemia following occlusion of the internal carotid artery, such as dynamic CT (4), measurement of cerebral blood flow, measurement of stump pressure, monitoring of somatosensory-evoked potentials (5), Doppler analysis (6), and perfusion MR imaging (7).

Measurement of cerebral blood flow has been performed by the intracarotid xenon-133 method (8, 9), stable xenon CT (10–16), single-photon emission CT (SPECT) (17–26), and positron emission tomography (PET) (27, 28). Measuring blood pressure (stump pressure) through the angiographic catheter in the

Received December 19, 2004; accepted after revision March 27, 2005.

From the Departments of Radiology (N.T., K.O., S.T., I.S., T.O., J.W.), Otorhinolaryngology (K.I.), and Neurosurgery (H.K., K.M.), Akita University School of Medicine, 1-1-1, Hondo, Akita City, Akita 010-8543, Japan.

Address correspondence to Noriaki Tomura, Department of Radiology, Akita University School of Medicine, 1-1-1, Hondo, Akita City, Akita 010-8543, Japan.

© American Society of Neuroradiology

distal internal carotid artery during occlusion of the internal carotid artery has also been reported as a safety index with which to predict ischemia following permanent occlusion of the internal carotid artery. In the present study, we compared the stump pressure during occlusion of the internal carotid artery with SPECT using technetium Tc 99m hexamethylpropyleneamine oxime (HMPAO).

### Methods

Twenty-seven patients (13 men; 14 women; mean age, 60.7 years; age range, 19–75 years) underwent a balloon occlusion test following diagnostic cerebral angiography. Their clinical diagnoses comprised aneurysm of the internal carotid artery ( $n = 8$ ), carcinoma of the thyroid gland ( $n = 2$ ), meningioma of the skull base ( $n = 4$ ), carcinoma of the hypopharynx ( $n = 4$ ), carcinoma of the oropharynx ( $n = 1$ ), carcinoma of the oral cavity ( $n = 3$ ), tumor of the parotid gland ( $n = 2$ ), giant cell tumor of the skull base ( $n = 1$ ), lymph node metastasis ( $n = 1$ ), and carotid body tumor ( $n = 1$ ). All patients required treatment by internal carotid artery occlusion. Informed consent for the balloon occlusion test was obtained from all patients. No patient had neurologic abnormalities or abnormal findings on brain CT or MR imaging. Symptomatic patients during the initial occlusion of the internal carotid artery following diagnostic angiography were excluded.

After diagnostic cerebral angiography was first performed using a 5F catheter, a 5F or 7F double-lumen balloon catheter was placed into the internal carotid artery of the affected side. One lumen is used for inflation of the balloon, and the second lumen is a distal lumen beyond the balloon connecting to a pressure transducer and pressure monitor. Another 5F catheter was introduced into the common carotid artery of the affected side. After the balloon was inflated, the patient was neurologically examined for several minutes, and the balloon catheter was deflated. The balloon catheter was then inflated again, and angiography of the internal carotid artery of the normal side ( $n = 21$ ) and vertebral artery ( $n = 13$ ) was performed to evaluate the circle of Willis. To prevent embolic events during inflation of the balloon, we intermittently infused saline with heparin through the distal lumen beyond the balloon and through the catheter placed in the proximal common carotid artery.

Because technetium Tc 99m HMPAO cannot be injected in the angiographic suite by law, the patient was transported to the nuclear medicine department with the balloon deflated. Reocclusion of the internal carotid artery was performed under fluoroscopy. An intravenous injection of 740 MBq of technetium Tc 99m HMPAO was administered a few minutes after occlusion, and then the balloon remained inflated for 15 minutes. The stump pressure was continuously monitored for these 15 minutes. Systemic brachial blood pressure was also monitored using an automatic sphygmomanometer at 3-minute intervals. The balloon catheter was deflated and removed. SPECT was performed using a triple-head gamma camera (Multispect3, Siemens Medical Systems, Erlangen, Germany) equipped with fanbeam collimators. Data were acquired by 120 views and reconstructed using a Butterworth filter. Attenuation correction was performed by Chang's method. The reconstructed section thickness was 4.9 mm for the transverse planes.

Sixty-four symmetric pairs of regions of interest were set manually on both sides of the cerebral surface including the cortices, lentiform nuclei, and thalami. Each region of interest was round and 10-mm in diameter. The radioactivity count ratio of the occluded side to the contralateral normal side was calculated and defined as L/n ratio. In the present study, we defined hypoperfusion as an area with an L/n ratio  $< 0.8$ . The minimum mean stump pressure (minMSP) during the balloon occlusion test and the pressure ratio of the minMSP to the

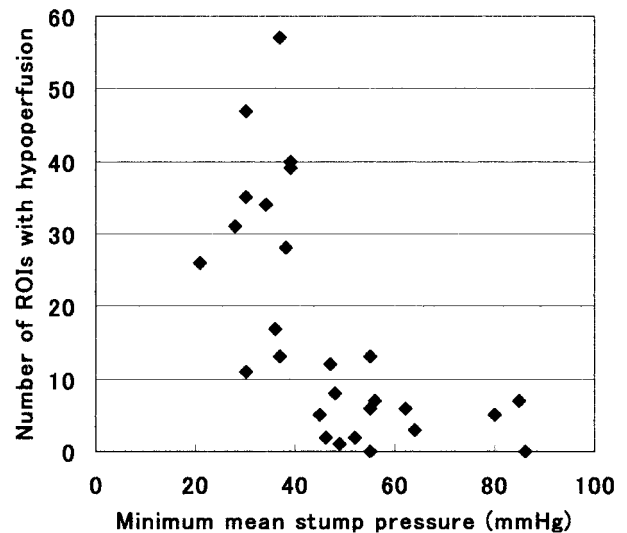


FIG 1. Graph shows the relationship between the minimum mean stump pressure and number of regions of interest (ROIs) with hypoperfusion. There was a significant correlation ( $P < .005$  by Spearman rank correlation).

mean systemic pressure (measured at the same time as the minMSP) were compared with hypoperfusion areas on SPECT. The relationship between mean L/n ratio and minMSP was also compared.

### Results

In total, the minMSP during occlusion of the internal carotid artery ranged from 21 to 86 mm Hg with a mean ( $\pm$ SD) of  $47.3 \pm 17.2$ . The L/n ratio ranged from 0.54 to 1.41 with a mean of  $0.93 \pm 0.16$ . Angiographic evidence of cross-filling through the circle of Willis was shown via the anterior communicating artery in 21 of 23 patients and via the posterior communicating artery in 12 of 15 patients. The minMSP in 5 patients without angiographic evidence of cross-filling via the anterior communicating artery or the posterior communicating artery (42.0 mmHg in average) was lower than that in the other patients (48.5 mm Hg in average); however, there was no significant difference between them.

The relationship between the number of regions of interest with hypoperfusion and minMSP is shown in Fig 1. There was a significant correlation between them ( $P < .005$  by Spearman rank correlation). The number of regions of interest with hypoperfusion was significantly ( $P < .001$  by the Mann-Whitney  $U$  test) greater in patients with a minMSP  $< 40$  mm Hg (mean =  $31.5 \pm 13.7$ ) than in patients with a minMSP  $\geq 40$  mm Hg ( $5.1 \pm 4.0$ ) (Figs 2, 3, 4). If the cut-off value of the minMSP is set at 50 mm Hg, the  $P$  value is 0.0024. The relationship between the number of regions of interest with hypoperfusion and the pressure ratio of minMSP to the mean systemic pressure is shown in Fig 5. The number of regions of interest with hypoperfusion was significantly ( $P < .001$  by the Mann-Whitney  $U$  test) greater in patients with a pressure ratio  $< 0.5$  ( $26.7 \pm 15.8$ ) than in patients with a pressure ratio  $\geq 0.5$  ( $4.5 \pm 3.5$ ) (Fig 6). If the cut-off

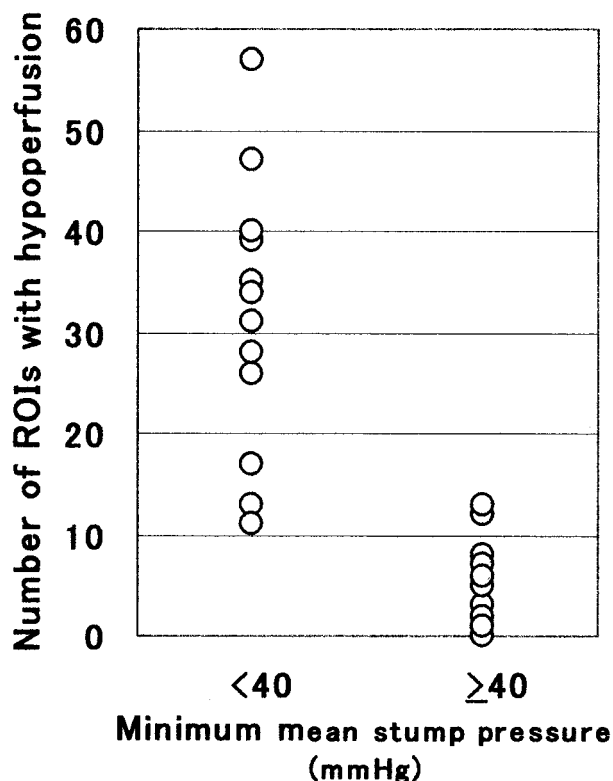


FIG 2. Graph shows that the number of regions of interest (ROIs) with hypoperfusion was significantly ( $P < .001$  by Mann-Whitney U test) greater in patients with a minMSP  $<40$  mm Hg ( $31.5 \pm 13.7$ ) than in patients with minMSP  $\geq 40$  mm Hg ( $5.1 \pm 4.0$ ).

value of the pressure ratio is 0.4 or 0.6, the  $P$  value is 0.0019 or 0.0409, respectively. Figure 7 shows a significant positive relationship between mean L/n ratio and minMSP (linear regression analysis;  $y = \text{mean L/n ratio}$ ,  $x = \text{minMSP}$ ;  $y = 0.71 + 0.005x$ ;  $r = 0.497$ ,  $P = .0084$ ).

There were 6 patients who showed a gradual decrease of MSP after occlusion. The number of regions of interest with hypoperfusion in these 6 patients ( $25.5 \pm 21.9$ ) was not significantly greater than that in other patients ( $14.4 \pm 13.7$ ). However, 4 of these 6 patients showed a minMSP  $<40$  mm Hg.

In 5 of 14 patients who underwent surgery, ligation of the internal carotid artery with bypass surgery ( $n = 2$ ) and transient occlusion of internal carotid artery ( $n = 12$ ) were performed. Infarction appeared in 1 of 2 patients who underwent ligation of the internal carotid artery after bypass surgery between the middle cerebral artery and common carotid artery. In that patient, the MSP during the balloon test occlusion was 38 mm Hg, and 28 regions of interest had hypoperfusion on SPECT.

### Discussion

Patients with aneurysms of the internal carotid artery or tumors invading the internal carotid artery at the neck or base of the skull often require permanent sacrifice or transient occlusion of the internal carotid

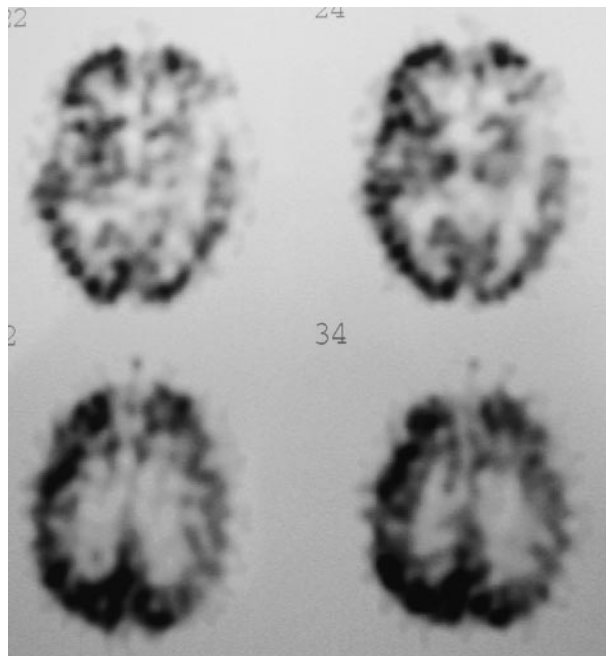


FIG 3. In a 73-year-old man with hypopharyngeal carcinoma on the left side, the minMSP was 30 mm Hg during balloon test occlusion of the left internal carotid artery. SPECT using technetium Tc 99m HMPAO showed hypoperfusion of the cerebral hemisphere on the left side.

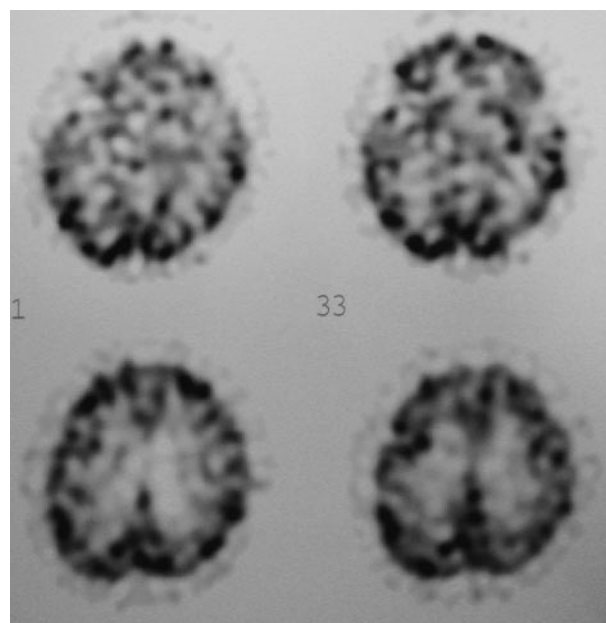


FIG 4. In a 64-year-old man with meningioma invading the left internal carotid artery, the MSP was 64 mm Hg during balloon test occlusion of the left internal carotid artery. SPECT using technetium Tc 99m HMPAO showed no hypoperfusion areas of the cerebral hemisphere on the left side.

artery. SPECT has been widely available for evaluating cerebral blood flow, and the use of SPECT for the balloon test occlusion has been reported (17–26). Technetium Tc 99m HMPAO is converted to a hydrophilic compound and remains fixed in the brain (10). The brain activities of technetium Tc 99m HMPAO reflect cerebral blood flow within a few minutes

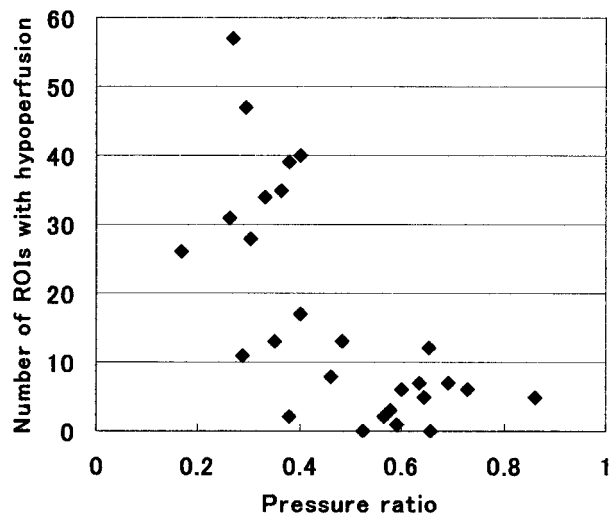


Fig 5. Graph shows the relationship between the number of regions of interest (ROIs) with hypoperfusion and the pressure ratio of the minMSP to the minimum mean systemic pressure.

after injection. In the present study, the balloon remained inflated for 15 minutes after injection, which is long enough to evaluate cerebral blood flow. On the other hand, measuring the stump pressure during the balloon test occlusion is easy to perform.

Several authors have reported the relationship between stump pressure and cerebral blood flow during the balloon test occlusion (17, 21–23, 26). Kurata et al (22) and Morishima et al (23) reported that the mean ratios of the initial MSP to the preocclusion mean arterial pressure of 60% is useful as an index of symmetrical cerebral blood flow on SPECT using technetium Tc 99m HMPAO. As they reported, the MSP has a tendency to fall immediately after occlusion. This was also indicated by Baker et al (10), who compared the change in MSP during the balloon test occlusion with cerebral blood flow measured by stable xenon CT. However, they reported that the MSP often gradually increased after occlusion.

In the present study, 6 patients showed a gradual decrease of MSP after occlusion. Previous studies used the average of MSP, the initial MSP, or the final MSP during the balloon occlusion test. We used the minMSP during the balloon test occlusion because the minMSP during the balloon occlusion test might be closely related to the risk of ischemia. The minMSP could be found by monitoring stump pressure throughout the 15-minute period. The minMSP did not often occur initially or finally after occlusion. The usefulness of systolic or diastolic stump pressure should be further studied. We compared the ratio of the minMSP to the mean systemic pressure measured at the same time as the minMSP with hypoperfusion areas on SPECT and found that a pressure ratio of more than 50% was a useful index of symmetrical cerebral blood flow.

We excluded symptomatic patients following initial occlusion of the internal carotid artery. If symptomatic patients undergo sacrifice of the internal carotid artery, they then require bypass graft or anastomosis

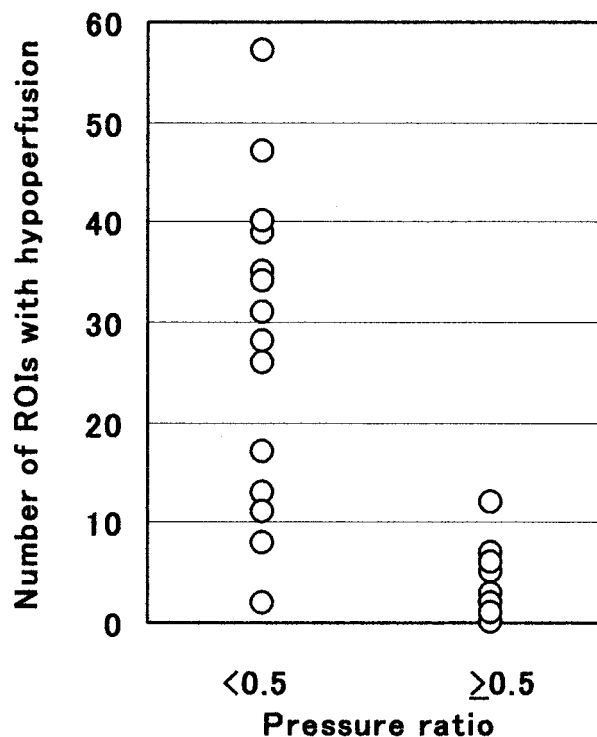


Fig 6. Graph shows that the number of regions of interest (ROIs) with hypoperfusion was significantly ( $P < .001$  by Mann-Whitney U test) greater in patients with a pressure ratio  $<0.5$  ( $26.7 \pm 15.8$ ) than in patients with a pressure ratio  $\geq 0.5$  ( $4.5 \pm 3.5$ ).

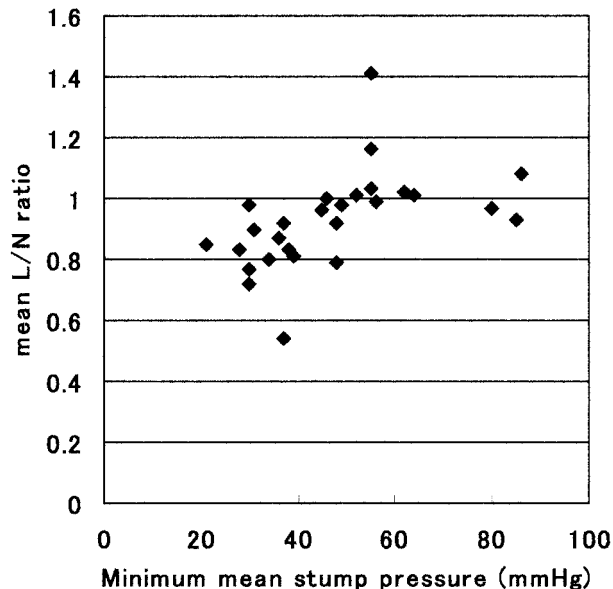


Fig 7. Graph shows the relationship between the minMSP and the mean L/N ratio (the radioactivity count of the occluded side / the radioactivity count of the contralateral normal side). There was a significant positive relationship (linear regression analysis;  $y = \text{mean L/N ratio}$ ,  $x = \text{minMSP}$ ;  $y = 0.71 + 0.005x$ ;  $r = 0.497$ ,  $P = .0084$ ).

surgery to supply blood flow to the distal portion of the internal carotid artery without brief occlusion of the internal carotid artery.

Okudaira et al (14) measured MSP and cerebral blood flow using stable xenon CT during balloon test



occlusion with and without acetazolamide activation and found a significant correlation between the increase in cerebral blood flow caused by acetazolamide and MSP. They also found no cerebral blood flow increase when MSP was <40 mmHg, and they noted that 40 mmHg appeared to be the lower autoregulatory limit. Although the methodology of their investigation was quite different from ours, it is interesting that the lower threshold of MSP during occlusion of the ICA was the same as that in the present study. In the present study, we defined hypoperfusion as an area with an L/n ratio <0.8. Although this value of the ratio is controversial, in previous reports concerning the balloon test occlusion, most authors qualitatively evaluated technetium Tc 99m HMPAO as an indicator of ischemic change.

Knudsen et al (17) performed SPECT using technetium Tc 99m HMPAO during carotid cross-clamping and found correlation between the stump pressure and asymmetry in the middle cerebral arterial territory semiquantitatively calculated by SPECT. Although they did not clearly define the lower threshold of the stump pressure, the figure in their report suggested that cases with a stump pressure <40 mm Hg had hemispheric asymmetry of more than 10%. A change in asymmetry with carotid clamping exceeding 10% is significant (17, 25).

Sugawara et al (25) reported the usefulness of SPECT using technetium Tc 99m ethylcysteinate dimer during the balloon test occlusion, and their criterion for moderate or severe hypoperfusion was an L/n ratio of <0.9. The definition of hypoperfusion in the present study, an L/n ratio <0.8, is more rigid, though the semiquantitative evaluation of technetium Tc 99m HMPAO applied in the present study is simple and does not yield an absolute cerebral blood flow value. Evaluation of absolute cerebral blood flow value by other methods such as  $^{133}\text{Xe}$ -SPECT, Iodine-123 iodoamphetamine-SPECT, and  $\text{H}_2^{15}\text{O}$ -PET might produce more accurate results.

Angiographic evaluation of the circle of Willis appears necessary for the collateral circulation; however, it cannot measure the collateral blood flow quantitatively. The stump pressure during occlusion of the internal carotid artery may quantitatively reflect the degree of collateral flow via the circle of Willis. In the present study, the minMSP in 5 patients without angiographic evidence of cross-filling via the anterior communicating artery or posterior communicating artery (42.0 mm Hg on average) was lower than that in the other patients (48.5 mm Hg on average).

Whether measuring stump pressure can be omitted by performing SPECT remains controversial. Although stump pressure cannot yield the location of risk for hypoperfusion, SPECT can give us the location of hypoperfused areas during the balloon test occlusion. It may not actually be necessary to measure stump pressure during balloon test occlusion when SPECT can be performed. However, the results of the present study would be useful at surgery because only stump pressure can be used as an index to predict

ischemia when a transient occlusion is performed at surgery. In addition, stump pressure should be monitored in patients whose SPECT does not show significant hypoperfusion before surgery. This study is still preliminary and should be performed in a greater number of patients.

## Conclusion

Patients with a minMSP of  $\geq 40$  mm Hg and patients with a pressure ratio of  $\geq 0.5$  show relatively symmetric cerebral perfusion on SPECT using technetium Tc 99m HMPAO during the balloon test occlusion. The minMSP during the balloon test occlusion reflects the extent of the hypoperfused area measured by SPECT using technetium Tc 99m HMPAO.

## References

1. Berenstein A, Ransohoff J, Kupersmith M, Flamm E, Graeb D. Transvascular treatment of giant aneurysms of the cavernous carotid and vertebral arteries. *Surg Neurol* 1984;21:3-21
2. Bavinszki G, Killer M, Ferraz-Leite H, Gruber A, Gross CE, Richling B. Endovascular therapy of idiopathic cavernous aneurysms over 11 years. *AJNR Am J Neuroradiol* 1998;19:559-565
3. Coley SC, Pandya H, Hodgson TJ, Jeffree MA, Deasy NP. Endovascular trapping of traumatic carotid-cavernous fistulae. *AJNR Am J Neuroradiol* 2003;24:1785-1788
4. Terada T, Nishiguchi T, Hyotani G, et al. Assessment of risk of carotid occlusion with balloon Matas testing and dynamic computed tomography. *Acta Neurochir (Wien)* 1990;103:122-127
5. Gigli GL, Caramia M, Marciani MG, Zarola F, Lavaroni F, Rossini PM. Monitoring of subcortical somatosensory evoked potentials during carotid endarterectomy: comparison with stump pressure levels. *Electroencephalogr Clin Neurophysiol* 1987;68:424-432
6. Takeuchi Y, Numata T, Konno A, et al. Evaluation of brain collateral circulation by the transcranial color Doppler-guided Matas' test. *Ann Otol Rhinol Laryngol* 1993;102:35-41
7. Michel E, Liu H, Remley KB, et al. Perfusion MR neuroimaging in patients undergoing balloon test occlusion of the internal carotid artery. *AJNR Am J Neuroradiol* 2001;22:1590-1596
8. Marshall RS, Lazar RM, Young WL, et al. Clinical utility of quantitative cerebral blood flow measurements during internal carotid artery test occlusions. *Neurosurgery* 2002;50:996-1005
9. Gupta DK, Young WL, Hashimoto T, et al. Characterization of the cerebral blood flow response to balloon deflation after temporary internal carotid artery test occlusion. *J Neurosurg Anesthesiol* 2002;14:123-129
10. Baker DW, Jungreis CA, Horton JA, Pentheny S, Lemley T. Balloon test occlusion of the internal carotid artery: change in stump pressure over 15 minutes and its correlation with xenon CT cerebral blood flow. *AJNR Am J Neuroradiol* 1993;14:587-590
11. Witt JP, Yonas H, Jungreis C. Cerebral blood flow response pattern during balloon test occlusion of the internal carotid artery. *AJNR Am J Neuroradiol* 1994;15:847-857
12. Kofke WA, Brauer P, Policare R, Pentheny S, Baker D, Horton J. Middle cerebral artery blood flow velocity and stable xenon-enhanced computed tomographic blood flow during balloon test occlusion of the internal carotid artery. *Stroke* 1995;26:1603-1606
13. Mathis JM, Barr JD, Jungreis CA, et al. Temporary balloon test occlusion of the internal carotid artery: experience in 500 cases. *AJNR Am J Neuroradiol* 1995;16:749-754
14. Okudaira Y, Arai H, Sato K. Cerebral blood flow alteration by acetazolamide during carotid balloon occlusion: parameters reflecting cerebral perfusion pressure in the acetazolamide test. *Stroke* 1996;27:617-621
15. Barr JD, Lemley TJ, McCann RM. Carotid artery balloon test occlusion: combined clinical evaluation and xenon-enhanced computed tomographic cerebral blood flow evaluation without patient transfer or balloon reinflation: technical note. *Neurosurgery* 1998;43:634-638
16. Field M, Jungreis CA, Chengelis N, Kromer H, Kirby L, Yonas H. Symptomatic cavernous sinus aneurysms: management and out-

- come after carotid occlusion and selective cerebral revascularization. *AJNR Am J Neuroradiol* 2003;24:1200–1207
17. Knudsen L, Vorstrup S, Olsen KS, Videbaek C, Schroeder TV. Tomographic cerebral blood flow measurement during carotid surgery. *Eur J Vasc Surg* 1994;8:552–555
  18. Lorberboym M, Pandit N, Machac J, et al. Brain perfusion imaging during preoperative temporary balloon occlusion of the internal carotid artery. *J Nucl Med* 1996;37:415–419
  19. Chen HJ, Chen HY. Use of Tc-99m HMPAO brain SPECT to evaluate cerebral collateral circulation during Matas test. *Clin Nucl Med* 1995;20:346–351
  20. Palestro CJ. Temporary balloon occlusion, SPECT and carotid artery sacrifice. *J Nucl Med* 1996;37:419–420
  21. Ryu YH, Chung TS, Lee JD, et al. HMPAO SPECT to assess neurologic deficits during balloon test occlusion. *J Nucl Med* 1996;37:551–554
  22. Kurata A, Miyasaka Y, Tanaka C, Ohtomo T, Yada K, Kan S. Stump pressure as a guide to the safety of permanent occlusion of the internal carotid artery. *Acta Neurochir (Wien)* 1996;138:549–554
  23. Morishima H, Kurata A, Miyasaka Y, Fujii K, Kan S. Efficacy of the stump pressure ratio as a guide to the safety of permanent occlusion of the internal carotid artery. *Neurol Res* 1998;20:732–736
  24. Yamamoto Y, Nishiyama Y, Toyama Y, Satoh K, Irie K, Ohkawa M. Preliminary results of Tc-99m ECD SPECT to evaluate cerebral collateral circulation during balloon test occlusion. *Clin Nucl Med* 2002;27:633–637
  25. Sugawara Y, Kikuchi T, Ueda T, et al. Usefulness of brain SPECT to evaluate brain tolerance and hemodynamic changes during temporary balloon occlusion test and after permanent carotid occlusion. *J Nucl Med* 2002;43:1616–1623
  26. Okada Y, Shima T, Yamada T, et al. Evaluation of Matas test by CBF studies, angiographic cross-filling and stump pressure in CEA patients [in Japanese]. *No To Shinkei* 1994;46:647–653
  27. Katano H, Nagai H, Mase M, Banno T. Measurement of regional cerebral blood flow with  $H_2^{15}O$  positron emission tomography during Matas test. *Acta Neurochir (Wien)* 1995;135:70–77
  28. Tanaka F, Nishizawa S, Yonekura Y, et al. Changes in cerebral blood flow induced by balloon test occlusion of the internal carotid artery. *Eur J Nucl Med* 1995;22:1268–1273