

Are your MRI contrast agents cost-effective?

Learn more about generic Gadolinium-Based Contrast Agents.



**FRESENIUS
KABI**

caring for life

AJNR

**Neurodegenerative Diseases: Neurobiology,
Pathogenesis and Therapeutics**

AJNR Am J Neuroradiol 2006, 27 (5) 1157-1158-a
<http://www.ajnr.org/content/27/5/1157.1>

This information is current as
of March 24, 2025.

BOOK REVIEW

Imaging of the Head and Neck, 2nd ed.

Edited by Mahmood F. Mafee, Galdino E. Valvassori, and Minerva Becker. Stuttgart, Germany: Thieme Medical Publishers; 2005, \$249.95.

This volume is the latest edition of Valvassori's popular textbook. It is a combined effort mainly of the 3 esteemed editors and includes contributions from 3 other authors: Drs. Lewin, Nour, and Weber. The new edition has been extensively revised and provides a comprehensive review of state-of-the-art head and neck imaging.

A major improvement in this edition is the reorganization of the book into 6 main sections, each of which is subdivided into chapters based on anatomic regions. Chapters have been expanded to include additional pathologies and cases. Many of the images from the first edition have been replaced with updated images and better examples, with added emphasis on MR imaging.

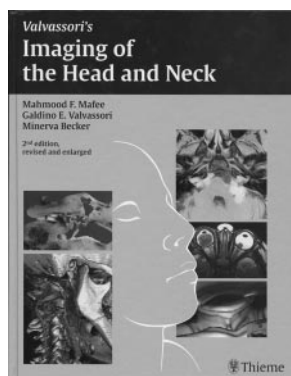
All the chapters are well written and informative and have a uniform style. Each chapter begins with an overview of embryology, discusses pertinent anatomy and imaging techniques that are used in current practice, and provides the reader with a thorough review of pathologic conditions and their varied radiologic manifestations.

The section on the temporal bone begins by describing detailed macrosectional temporal bone anatomy and the corresponding microradiographs and CT images. The high-quality color plates of the macrosections depict the anatomy exquisitely. These and the line drawings in the remainder of the chapter help the reader visualize the correlative CT anatomy of the various pathologic conditions. As one would expect, more emphasis is placed on MR imaging in this edition because this technique now plays a larger role in the imaging of temporal bone anatomy.

The orbital, ocular imaging, and skull base chapters of section 2 are superb. The updated MR images and tables of differential diagnoses are new and appealing.

The next section deals with the nasal cavity and paranasal sinuses. The high quality state-of-the-art high-resolution CT images depicting normal sinonasal anatomy are particularly useful.

The fourth section features a new chapter on temporomandibular joint imaging that was not addressed in the previous edition and another chapter on maxillofacial diseases. The author brings the reader up-to-date information about new imaging techniques and the potential usefulness of CT and state-of-the-art MR imaging over conventional radiography in the diagnosis and treatment of temporomandibular joint disorders. Of great value in both of these chapters are the excellent CT and MR correlative images of



the various pathologic conditions. Particularly useful for the oromaxillofacial surgeon is the information about a tool for planning dental surgery, DentaScan (GE Healthcare, Milwaukee, Wis) at the end of the chapter.

Like the other sections, the last 2 on the suprahyoid and infrahyoid neck are well written, thorough, and extremely well illustrated. The author touches briefly on the usefulness of interventional MR imaging techniques in the diagnosis and ablation of head and neck cancer. The larynx has been covered extensively, and the surgicopathologic and imaging correlation of the various laryngeal lesions is excellent.

This delightful book is well organized, with virtually no glaring weaknesses. The greatest attributes of this book are the layout and descriptive text, variety of cases, and excellent quality of the CT and MR images. The images are well integrated into the text, the legends are well written, and the references are current.

Overall, the book fulfills its intended purpose of providing updated anatomic and clinicopathologic information and review of radiologic imaging findings in various commonly encountered disease entities in the head and neck.

In summary, this is a superb clinically relevant reference textbook. It covers all aspects of head and neck imaging that neuroradiologists and clinicians dealing with this subject would find useful. The authors are to be congratulated on this outstanding job of organizing the essentials of head and neck imaging in an easy and readable manner.

BOOK REVIEW

Neurodegenerative Diseases: Neurobiology, Pathogenesis and Therapeutics

Edited by M. Flint Beal, Anthony E. Lang, and Albert Ludolph. Cambridge, UK: Cambridge University Press; 2005, \$324.

In the disorders resulting in cerebral neurodegenerative disease, neuroimaging assumes a key role; and because imaging has evolved to more than pattern recognition on routine MR imaging (or CT), a basic understanding of the pathophysiologic processes involved in degenerative disease is a requisite. This 985-page book, edited by Drs. Beal, Lang, and Ludolph with 122 contributors, serves to broaden our understanding of these diseases because neuroradiologists will be increasingly asked to analyze, for example, tract morphology on diffusion tensor imaging (DTI) or biochemical alterations on chemical shift imaging, or areas of diminished cerebral perfusion on perfusion-weighted imaging (PWI) in these abnormalities.

The book is divided into 10 parts, encompassing 62 chapters. The parts are the following: "Basic Aspects of Neurodegeneration," "Neuroimaging in Neurodegeneration," "Therapeutic Approaches in Neurodegeneration," "Normal Aging," "Alzheimer Disease," "Other Dementias," "Parkinson's and Related Movement Disorders," "Cerebellar Degenerations," "Motor Neuron Diseases," and "Other Neurodegenerative Diseases."