

Generic Contrast Agents

Our portfolio is growing to serve you better. Now you have a *choice*.



[VIEW CATALOG](#)

AJNR

Gadolinium Use in Spine Procedures for Patients with Allergy to Iodinated Contrast—Experience of 127 Procedures

Y. Safriel, M. Ali, M. Hayt and R. Ang

AJNR Am J Neuroradiol 2006, 27 (6) 1194-1197

<http://www.ajnr.org/content/27/6/1194>

This information is current as of May 5, 2025.

ORIGINAL
RESEARCH

Y. Safriel
M. Ali
M. Hayt
R. Ang

Gadolinium Use in Spine Procedures for Patients with Allergy to Iodinated Contrast—Experience of 127 Procedures

BACKGROUND AND PURPOSE: To review the safety and efficacy of gadolinium as a contrast agent in spine pain management procedures in patients who are at high risk for a contrast reaction and are therefore unacceptable candidates for the use of standard nonionic contrast.

METHODS: We reviewed our records over a 4-year period of interlaminar and foraminal epidural steroid injections, nerve blocks, facet injections, intercostal blocks, and diskograms in the lumbar, thoracic, and cervical spine for cases in which patients had allergies that made them unsuitable candidates for standard nonionic contrast and where gadolinium was used to confirm needle tip placement before injection of medication.

RESULTS: Ninety-two patients underwent 127 procedures. A spinal needle was used in all but 7 procedures. All patients were outpatients and all were discharged without complication after 20 to 45 minutes with follow-up instructions. No delayed complications were reported. Gadolinium was visualized by using portable C-arm fluoroscopy in vivo allowing for confirmation of needle tip location. For epidural steroid injection, the gadolinium dose ranged from 1 to 5 mL, nerve blocks from 0.2 to 1 mL per level, facet injections from 0.2 to 0.5 mL per level, intercostal blocks used 0.5 mL, and diskograms from 1.5 to 7.5 mL per level. The highest dose received by 1 patient was an intradiskal 15.83 mL during a 3-level diskogram.

CONCLUSION: Gadolinium seems to be a safe alternative to standard nonionic contrast in spine pain management procedures in those patients considered to be at high risk for a contrast reaction.

The use of epidural injections for the treatment of back pain was first described by Evans in 1930.¹ Since then, a growing body of evidence has documented the need for fluoroscopic confirmation of needle placement^{2,3} by using x-ray attenuating contrast. Most commonly, this involves nonionic contrast. A small but significant group of patients exhibit allergic symptoms to contrast. Contrast reactions have been documented in the setting of vascular injections. A vascular injection is a recognized complication of spinal pain management procedures.² Vascular injections should be avoided because they may result in injection of particulate steroid and local anesthetic to the systemic circulation with possible embolic effects and arrhythmias, respectively. In a series by Katayama et al,⁴ adverse drug reaction with the intravenous use of nonionic contrast was noted at 1.2% to 3.13%, of which 0.02% to 0.04% were severe. Therefore, some patients should not receive iodinated ionic or nonionic contrast. Another common potential complication of epidural injections is inadvertent intrathecal injections. This carries a risk of spinal anesthesia with subsequent hypotension in patients who may have limited cardiovascular reserve as well as adhesive arachnoiditis induced by some classes of steroids.^{5,6} Very little work has been published in the literature regarding the use of gadolinium in the intrathecal space^{7,8} because there are few clinical applications. As needle misplacement is the most common complication of

percutaneous spinal injections, it is essential to use a contrast agent to determine the exact position of the needle tip in all patients. We therefore present our collective findings on the use of gadolinium as an effective contrast agent in percutaneous outpatient image-guided spine procedures demonstrating it as a safe alternative in those patients who are otherwise not candidates for contrast use.

Materials and Methods

We performed a retrospective record search in our computerized data system from 2001 to 2004 (4 years) of our records of percutaneous outpatient spinal interventions. The search included all interlaminar and foraminal epidural steroid injections, nerve blocks, facet injections, intercostal blocks, and diskograms in the lumbar, thoracic, and cervical spine where gadolinium/gadodiamide (Omniscan; GE Healthcare, Little Chalfont, Buckinghamshire, UK) was used. Gadolinium was used for needle tip location confirmation in cases where contraindications existed to the routine use of iohexol 240 (Omnipaque; GE Healthcare). Contraindications to iodinated contrasts were defined as a documented history of adverse reactions after injection of iodinated contrast media, patients in or with a history of renal failure, diabetics with increased creatinine levels as determined by the reference ranges at the local laboratory, and patients taking metformin (Glucophage) or glyburide/metformin (Glucovance) who had taken their medication in the 48 hours leading up to the procedure.

All procedures were performed on an outpatient basis using portable C-arm fluoroscopy (OEC 9600 or OEC 9800; General Electric, Milwaukee, Wis). The patients signed informed consent for the procedure and were given the alternatives of rescheduling the procedure after steroid premedication, the use of saline or air in place of contrast, or aborting the procedure. All procedures were performed as part of routine clinical care and not as part of a research study. As is the clinical routine in our facility, all patients were observed for at least 30

Received July 14, 2005; accepted after revision November 1.

From the Center for Diagnostic Imaging, Waite Park, Minn (Y.S., R.A.); Neuroradiology Section, Department of Radiology, Yale University School of Medicine, New Haven, Conn (Y.S.); Radnet Management Inc, Los Angeles, Calif (M.A.); and Center for Diagnostic Imaging, Winter Park, Fla (M.H.).

Address correspondence and reprint requests to Yair Safriel, MD, Neuroradiology Section (CB30), Dept. of Radiology, 333 Cedar St, Yale University School of Medicine, New Haven, CT 06520.

Procedure type, location, and contrast amounts			
Procedure	Patients	Procedures	Gadolinium Amounts (cc/level)
Diskogram (total)	11	35	
Lumbar	10	32	1.5–7.5
Thoracic	1	3	1.5–1.8
Epidural injection (interlaminar) (total)	53	53	
Cervical	16	16	2.0–5.0
Thoracic	1	1	1.0–1.0
Lumbar	36	36	1.0–5.0
Epidural Injection (transforaminal) (total)	7	7	
Lumbar	7	7	1.0–3.0
Facet injection (total)	6	13	
Cervical	1	2	0.2–0.2
Lumbar	5	11	0.2–0.5
Intercostal injection (total)	1	3	
	1	3	0.5–0.5
Nerve block (total)	14	16	
Cervical	5	5	0.2–0.5
Lumbar	9	11	0.2–5.0
Grand total	92	127	

minutes after the procedure and were given standard instructions to call the radiologist on call in the event of an adverse reaction. The procedures were performed under sterile conditions with the patient taking nothing by mouth between 1 and 4 hours before the start. Under fluoroscopic guidance, a spinal needle (or, in some cases in the cervical spine, a Whitacre needle) was guided into position. The gadolinium was drawn into a syringe (5 or 10 mL) from a 20-mL container that had been opened for less than 24 hours and stored in a dark cupboard at temperatures between 15 and 30°C according to the manufacturer's recommendations. A gadolinium test injection was then performed to confirm correct location of the needle and to exclude vascular or intrathecal injection. The procedure was performed, at the discretion of the operator, by using local anesthesia but without conscious sedation. After needle localization, depending on the procedure type, the patients were administered with a combination of steroid and local anesthetic, steroid alone or, in the case of diskograms after pain response was determined, local anesthetic only.

Results

We identified 92 patients who underwent 127 procedures. Table 1 provides a breakdown of the type of procedures and contrast amounts. A spinal needle was used in 120 procedures. The remaining procedures used a Whitacre needle. All patients were outpatients and all were discharged without complication after 20 to 45 minutes. No delayed complications were reported. Gadolinium was visualized by using portable C-arm fluoroscopy in vivo allowing for confirmation of needle tip location and excluding vascular or intrathecal location.

Although gadodiamide was less conspicuous than iohexol 240, there was sufficient visualization of the contrast material (Figs 1, 2, and 3). For epidural steroid injections, gadodiamide dose ranged from 1 to 5 mL, nerve blocks from 0.2 to 1 mL per level, facet injections from 0.2 to 0.5 mL per level, intercostal blocks used 0.5 mL, and diskograms used from 1.5 to 7.5 mL per level. The highest dose received by a single patient was an intradiskal 15.83 mL during a 3-level diskogram.

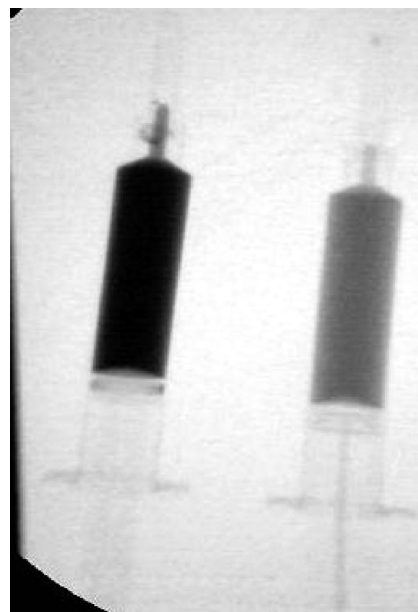


Fig 1. Visualization of iohexol 240 and gadodiamide using fluoroscopy. 5 mL of iohexol 240 (Omnipaque; left) and gadodiamide (Omniscan; right) were drawn into a 5-mL syringe and a snapshot image was obtained with the use of a portable C-arm (GE 9600) at 0.6 mA and 46 Kv.

Discussion

Degenerative back disease is a growing health care problem as the number of aged patients increases. Furthermore, there is a growing trend to use percutaneous image-guided spinal interventions to alleviate or palliate pain^{9,10} and as a prelude to surgery both in determining whether surgery is necessary and in determining the operative levels.^{11,12} To date, however, no article in the medical literature guides physicians in the use of gadolinium in the event a patient is considered an unsuitable candidate for iodinated contrast in image-guided spinal procedures. As part of the informed consent process required for such procedures, one of the basic tenets is giving the patient a complete overview of the risks and benefits. This article addresses that gap in the literature.

There is a significant body of evidence attesting to the safety of gadolinium compounds injected intravenously, with doses as high as 60 mL for CT angiography¹³ and for MR studies.¹⁴⁻¹⁶ No overdose of gadodiamide has been reported.¹⁷ Mild-to-moderate side effects occurred in less than 1% of patients when administered intravenously.¹⁸⁻²³ Nausea or vomiting and headache are the most common adverse effects, with a frequency ranging from 0.26% to 0.42%.²⁰ Other rare reactions reported after the IV administration of gadolinium products include paresthesias, dizziness, focal convulsions, urticaria, mucosal reactions, generalized flushing, cardiovascular reactions (eg, tachycardia, arrhythmia), generalized seizures, laryngospasm, and anaphylactic shock.¹⁸⁻²³ A study in an animal model that used low intrathecal doses of gadolinium did not reveal such alterations.²⁴ A large multicenter study of 95 patients showed no deleterious effects of up to 5 mL of a gadolinium compound (Magnevist; Schering, Berlin, Germany) injected into the lumbar subarachnoid space,⁸ whereas another study demonstrated safety of gadolinium injected directly into the ventricles.²⁵

Although our study did not include a formal control group,

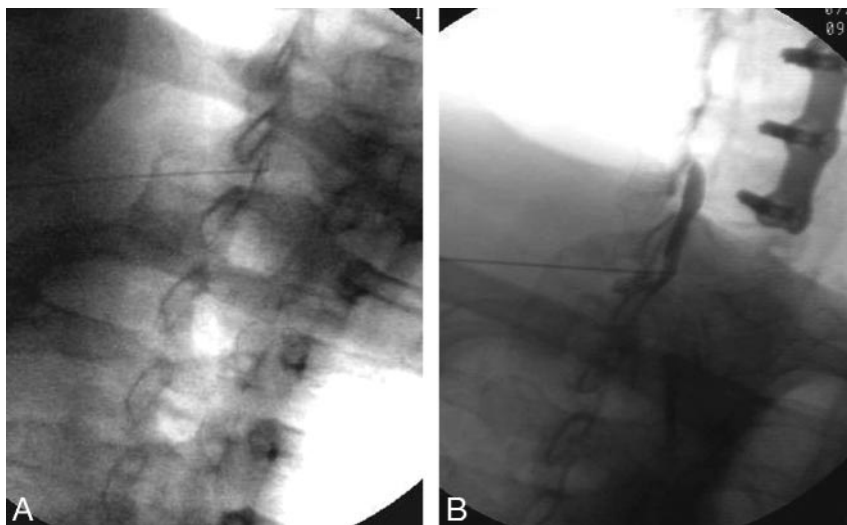


Fig 2. Cervical interlaminar epidurography using gadodiamide (a) and iohexol 240 (b).

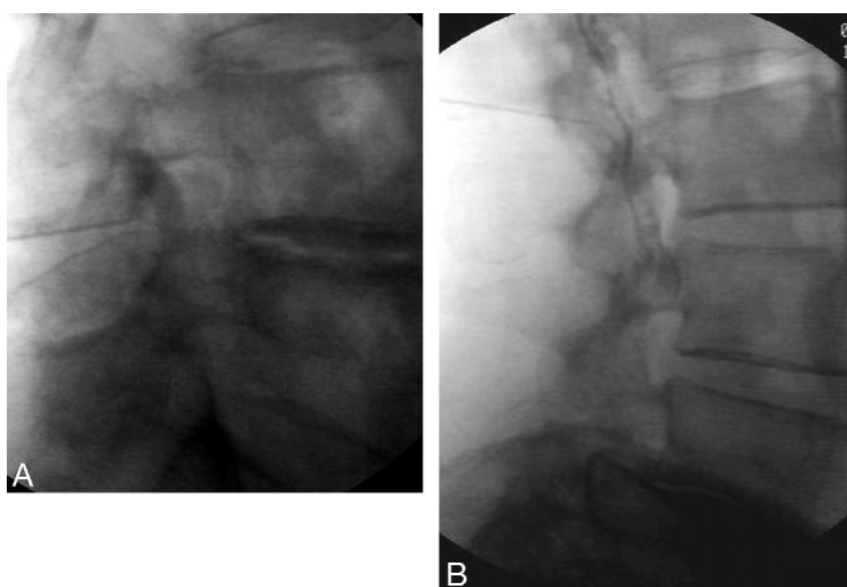


Fig 3. Lumbar interlaminar epidurography using gadodiamide (a) and iohexol 240 (b).

as suggested by Johnson,²⁶ the practice of epidural spinal injections is now so widely entrenched in routine clinical medicine that there is no need for a formal control group. The risks and complications of image-guided spinal procedures using iodinated contrast have been published by members of our group as well as others and have been well documented.^{2,9,10} Between the authors of this article (excluding the authors' partners/colleagues), we perform approximately 60 such procedures per day with iohexol 240. Interpolating that to the thousands of physiatrists and pain specialists in the United States, innumerable instances of these procedures are performed daily. Therefore, the "control" is the routine standard of care. Furthermore, our injection techniques are identical to those in the original article by our colleagues, who reviewed 5334 cases² and that are currently the standard of care with a known and accepted safety profile.

We used gadodiamide because it was the gadolinium preparation available in our institutions. We recognize that there are several other widely available gadolinium-based contrast agents that are often used interchangeably in clinical practice. Therefore, our study is strictly applicable only to gadodiamide

(Omniscan). Future larger studies may also include other gadolinium agents.

We chose to include all image-guided pain management procedures for this study because the potential for intrathecal or intravenous administration exists with all procedures. A previous series of gadolinium diskography used gadopentetate dimeglumine (Magnevist; Schering) at low concentrations (1:250) for MR diskography.²⁷ For this unusual application of diskography, such low doses suffice. However, for routine diskography and other percutaneous spine interventions, such low doses would

not attenuate the x-ray beam sufficiently to be visualized; therefore, higher doses would have to be used.

The importance of defining the exact position of the needle tip cannot be understated and is difficult to achieve without some form of contrast injection.³ The main danger in imprecise needle position is intrathecal administration of injectate, which may result in steroid-induced adhesive arachnoiditis and anesthetic-induced spinal anesthesia, which can cause hypotension.^{5,6} Vascular injection may result in particulate steroid material entering and embolizing in the circulation and arrhythmias because of vascular local anesthesia. The only method of confirming nonvascular location is via a contrast injection, because saline and/or air would not opacify the small perispinal vessels.² In the end, even if blind needle placement does not result in an adverse event, it has been shown that a blind approach does not result in correct placement of therapeutic material^{2,3,28,29} in up to 30% of instances. Although this may not hurt the patient, it would not benefit them either and would result in an essentially ineffective procedure for which the patient was charged a fee. Therefore, contrast injection in the performance of image-guided spinal interventions is a necessity and not a luxury.

Conclusion

Gadolinium seems to be a safe alternative to iodinated contrast for percutaneous image guided outpatient procedures in patients who are deemed unsuitable candidates for the use of iodinated contrast.

Acknowledgment

The authors are grateful to Tamara Frink, Center for Diagnostic Imaging, St. Cloud, Minn, for her assistance in preparing this manuscript.

Author's Note

Since the submission of our original paper, the authors have amassed an additional 400 procedures. In this larger cohort, we had one documented inadvertent intrathecal injection in the lumbar spine, without complication. One patient undergoing cervical interlaminar epidurography and another undergoing a two level cervical diskogram on the same day experienced an adverse event that included seizures and necessitated ICU admission. Both patients were discharged without complications after 3 days. Because both reactions happened at the same center within an hour of each other, because both procedures were at the hand of a very experienced radiologist, and because these were the only adverse events in the entire study, we cannot exclude the possibility that the gadolinium batch was tainted. Based on our wider experience, we think that gadolinium is safe for use in the lumbar spine. The indication for gadolinium use in cervical needle-guided spine procedures are less clear, and use of a blunt-tip needle should be considered. These patients, as well as the rest of our larger cohort, will be the subject of a follow-up paper.

References

1. Evans W. Intracanal epidural injection therapy in the treatment of sciatica. *Lancet* 1930;2:1225–29
2. Johnson BA, Schellhas KP, Pollei SR, et al. Epidurography and therapeutic epidural injections: technical considerations and experience with 5334 cases. *AJNR Am J Neuroradiol* 1999;20:697–705
3. Bartynski WS, Grahovac SZ, Rothfus WE. Incorrect needle position during lumbar epidural steroid administration: inaccuracy of loss of air pressure resistance and requirement of fluoroscopy and epidurography during needle insertion. *AJNR Am J Neuroradiol* 2005;26:502–05
4. Katayama H, Yamaguchi K, Kozuka T, et al. Adverse reactions to ionic and nonionic contrast media. A report from the Japanese Committee on the Safety of Contrast Media. *Radiology* 1990;175:621–28
5. Abram SE, O'Connor TC. Complications associated with epidural steroid injections. *Reg Anesth* 1996;21:149–62
6. Nelson DA. Intraspinal therapy using methylprednisolone acetate: twenty-three years of clinical controversy. *Spine* 1993;18:278–86
7. Skälpe IO. Is it dangerous to inject magnetic resonance contrast media into the subarachnoid space? *Eur Radiol* 1998;8:427
8. Tali ET, Ercan N, Krumina G, et al. Intrathecal gadolinium (gadopentetate dimeglumine) enhanced magnetic resonance myelography and cisternography: results of a multicenter study. *Invest Radiol* 2002;37:152–59
9. Botwin KP, Gruber RD, Bouchlas CG, et al. Fluoroscopically guided lumbar transformational epidural steroid injections in degenerative lumbar stenosis: an outcome study. *Am J Phys Med Rehabil* 2002;81:898–905
10. Lynch MC, and Taylor JF. Facet joint injection for low back pain. A clinical study. *J Bone Joint Surg Br* 1986;68:138–41
11. Riew KD, Yin Y, Gilula L, et al. The effect of nerve-root injections on the need for operative treatment of lumbar radicular pain. A prospective, randomized, controlled, double-blind study. *J Bone Joint Surg Am* 2000;82:1589–93
12. Kaplan M, Dreyfuss P, Halbrook B, et al. The ability of lumbar medial branch blocks to anesthetize the zygapophysial joint. A physiologic challenge. *Spine* 1998;23:1847–52
13. Henson JW, Nogueira RG, Covarrubias DJ, et al. Gadolinium-enhanced CT angiography of the circle of Willis and neck. *AJNR Am J Neuroradiol* 2004;25:969–72
14. Filippi M, Rovaris M, Capra R, et al. A multi-centre longitudinal study comparing the sensitivity of monthly MRI after standard and triple dose gadolinium-DTPA for monitoring disease activity in multiple sclerosis. Implications for phase II clinical trials. *Brain* 1998;121:2011–20
15. Youssry I, Filippi M, Walther E, et al. Serial gadolinium-DTPA of spinal cord MRI in multiple sclerosis: triple vs. single dose. *Magn Reson Imaging* 2000;18:1183–86
16. Okada S, Katagiri K, Kumazaki T, et al. Safety of gadolinium contrast agent in hemodialysis patients. *Acta Radiol* 2001;42:339–41
17. Omniscan [package insert]. Little Chalfont, Buckinghamshire, UK: GE Healthcare; 2005
18. Niendorf HP, Hausteiner J, Cornelius I, et al. Safety of gadolinium-DTPA: extended clinical experience. *Magn Reson Med* 1991;22:222–28
19. Niendorf HP, Hausteiner J, Louton T, et al. Safety and tolerance after intravenous administration of 0.3 mmol/kg Gd-DTPA: results of a randomized, controlled clinical trial. *Invest Radiol* 1991;26:S221–S223
20. Goldstein HA, Kashanian FK, Blumetti RF, et al. Safety assessment of gadopentetate dimeglumine in US clinical trials. *Radiology* 1990;174:17–23
21. Tardy B, Guy C, Barral G, et al. Anaphylactic shock induced by intravenous gadopentetate dimeglumine. *Lancet* 1992;339:494
22. Harbury OL. Generalized seizure after IV administration of gadopentetate dimeglumine. *AJNR Am J Neuroradiol* 1991;12:666
23. Tishler S, Hoffman JC Jr. Anaphylactoid reactions to IV gadopentetate dimeglumine. *AJNR Am J Neuroradiol* 1990;11:1167
24. Skälpe IO, Tang GJ. Magnetic resonance imaging contrast media in the subarachnoid space. A comparison between gadodiamide injection and gadopentetate dimeglumine in an experimental study in pigs. *Invest Radiol* 1997;32:140–48
25. Siebner HR, Graf von Einsiedel H, Conrad B. Magnetic resonance ventriculography with gadolinium DTPA: report of two cases. *Neuroradiology* 1997;39:418–22
26. Johnson DW. Back to the future: epidurography. *AJNR Am J Neuroradiol* 1998;20:537
27. Wagner AL. Gadolinium diskography. *AJNR Am J Neuroradiol* 2004;25:1824–27
28. Renfrew DL, Moore TE, Kathol MH, et al. Correct placement of epidural steroid injections: fluoroscopic guidance and contrast administration. *AJNR Am J Neuroradiol* 1991;12:1003–07
29. White AH, Derby R, Wynne G. Epidural injections for the diagnosis and treatment of low-back pain. *Spine* 1980;5:78–86