

Are your MRI contrast agents cost-effective?

Learn more about generic Gadolinium-Based Contrast Agents.



**FRESENIUS
KABI**

caring for life

AJNR

**Endovascular Treatment of Intracranial
Vertebral Artery Dissections with Stent
Placement or Stent-assisted Coiling**

J.Y. Ahn, I.B. Han, T.G. Kim, P.H. Yoon, Y.J. Lee, B.-H. Lee, S.H. Seo, D.I. Kim, C.K. Hong and J.Y. Joo

This information is current as
of April 10, 2024.

AJNR Am J Neuroradiol 2006, 27 (7) 1514-1520
<http://www.ajnr.org/content/27/7/1514>

ORIGINAL RESEARCH

J.Y. Ahn
I.B. Han
T.G. Kim
P.H. Yoon
Y.J. Lee
B.-H. Lee
S.H. Seo
D.I. Kim
C.K. Hong
J.Y. Joo

Endovascular Treatment of Intracranial Vertebral Artery Dissections with Stent Placement or Stent-assisted Coiling

BACKGROUND AND PURPOSE: Endovascular treatment with stent placement or stent-assisted coiling was recently introduced as an alternative to parent artery occlusion in intracranial vertebral artery dissections. We describe the efficacy and limitations of this method.

METHODS: Fourteen patients with intracranial vertebral artery dissection were treated with stent placement (10 patients) or stent-assisted coiling (4 patients). Double overlapping stents were deployed in 4 of 10 patients with stent placement alone. Angiographic follow-up at 6 to 12 months was available in 13 patients.

RESULTS: In 13 patients with dissecting aneurysm, immediate angiographic outcomes were complete occlusion (1 patient), nearly complete (2 patients), and incomplete (10 patients). Follow-up angiograms of 12 of these patients showed complete occlusion (6 patients) and incomplete (6 patients; 1 unstable and 5 stable). Complete occlusion rates in follow-up angiograms were superior in double stent placement (75%) or stent-assisted Guglielmi detachable coil (GDC) embolization to stent placement alone (0%). There were no instances of postprocedural ischemic attacks, new neurologic deficits, and no new minor or major strokes before patient discharge. On the modified Rankin scale applied in follow-up, all patients were assessed as functionally improved or of stable clinical status.

CONCLUSIONS: Intracranial vertebral artery dissections were acceptably treated with stent placement or stent-assisted coiling, and the patency could be preserved at follow-up. However, the efficiency of stent placement alone for intracranial vertebral artery dissecting aneurysm was limited. Stent-assisted coil embolization or double stent placements are a viable alternative for complete occlusion of dissecting aneurysms.

Intracranial vertebral artery (VA) dissection is not a common diagnosis, although with increased use of MR imaging as a diagnostic tool in acute stroke settings, it has been more frequently identified. It may lead to significant arterial stenosis, occlusion, pseudoaneurysm formation with subsequent hemodynamic and embolic infarctions, or subarachnoid hemorrhage (SAH). Unruptured VA dissections usually have a benign nature, but the natural course of this lesion remains poorly understood.^{1,2} Dissection is a dynamic process, and though the angiographic appearance may worsen during the acute phase of dissection, ~90% of stenoses eventually resolve and ~66% of occlusions are recanalized. Ischemic symptoms occur in more than 90% of patients in whom a VA dissection is diagnosed and may involve the brain stem as well as the thalamus and the cerebral or cerebellar hemispheres.^{3,4} Imaging studies suggest that more than 90% of infarcts due to dissection are thromboembolic rather than hemodynamic in origin.^{5,6} To prevent VA occlusion or distal embolization, anticoagulation and antiplatelet therapy have gained widespread acceptance, although, because reported series are too small, it is difficult to establish firmly the benefits of any particular therapeutic technique.^{3,4} Nevertheless, anticoagulation is not innocuous and may be contraindicated or be ineffective

to prevent symptomatic progression.^{3,7} On the other hand, in cases presenting with SAH, the rerupture rate during the acute stage is high.^{8,9} Therefore, it has been proposed that patients initially with SAH should undergo early repair of the aneurysm by open surgery or obliteration of the aneurysm by endovascular procedures.^{10,11} Treatment with a combination of stents and coils or with a stent or coils alone has recently been described in a small number of patients.¹²⁻¹⁷ This method, which can preserve the parent artery, may be an alternative to parent artery occlusion, especially for patients with high risks of complications after parent artery occlusion. However, its therapeutic effect and long-term validity need to be considered, because there are few reported data. We describe the efficacy and limitations of stent placement or stent-assisted coiling in the treatment of intracranial VA dissections.

Methods

Patients

We obtained approval from our institutional review board to study the use of stent placement or stent-assisted coiling to treat the intracranial VA dissections. Only arterial dissections involving the VA above C2 were included in this study.

Between March 1996 and March 2005, 42 consecutive patients with VA dissection underwent endovascular treatment at our institution. All patients were evaluated by 2 neurosurgeons and 2 neuroradiologists—all members of the endovascular team. For the first 3 years of this period (1996–1999), deconstructive endovascular procedures (proximal occlusion or occlusion at the dissection site) were used as the treatment of choice. At the beginning of 2000, when the coronary stent system became available in our department, we preferentially performed reconstructive procedures (stent placement or

Received August 17, 2005; accepted after revision November 13.

From the Departments of Neurosurgery (J.Y.A., C.K.H., J.Y.J.) and Diagnostic Radiology (S.H.S., D.I.K.), Yonsei University College of Medicine, Seoul, South Korea; Departments of Neurosurgery (I.B.H., T.G.K.) and Diagnostic Radiology (P.H.Y., Y.J.L.), Pochon CHA University, Sungnam, South Korea; and Department of Diagnostic Radiology (B.-H.L.), Eulji University Hospital, Daejeon, South Korea.

Address correspondence to Jung Yong Ahn, MD, Department of Neurosurgery, Yongsong Severance Hospital, Yonsei University College of Medicine, 146-92, Dogok-dong, Kangnam-gu, Seoul, 135-720, South Korea; e-mail: jyahn@yumc.yonsei.ac.kr

Table 1: Summary of the clinical characteristics in 16 patients with vertebrobasilar dissections treated with stents and/or coils

Patient No./ Age (y)/Sex	Clinical Presentations	MRS on Admission	Angiographic Sign	Location
1/52/F	Vertebrobasilar insufficiency	1	Fusiform dilation	Left VA proximal to PICA
2/33/M	Infarction, medullary	2	String sign	Left VA across PICA
3/55/F	Infarction, pontine	1	Pearl and string sign	Right VA distal to PICA
4/54/M	Infarction, cerebellar	1	Pearl and string sign	Left VA across PICA
5/37/M	Headache	1	Pearl and string sign	Left VA distal to PICA
6/46/M	Headache	1	Pearl and string sign	Right VA proximal to PICA
7/50/F	Headache	1	Fusiform dilation	Left Va distal to PICA
8/67/M	Infarction, medullary	2	Pearl and string sign	Right Va proximal to PICA
9/55/F	Subarachnoid hemorrhage	3	Fusiform dilation	Right VA distal to PICA
10/64/M	Headache	1	Pearl and string sign	Left VA across PICA
11/52/M	Vertebrobasilar insufficiency	1	Fusiform dilation	Right VA across PICA
12/48/F	Headache	1	Fusiform dilation	Left Va proximal to PICA
13/53/M	Subarachnoid hemorrhage	3	Pearl and string sign	Left VA across PICA
14/48/F	Infarction, pontine	1	Pearl and string sign	Right VA proximal to PICA

Note:—MRS indicates modified Rankin Scale; VA, vertebral artery; PICA, posterior inferior cerebellar artery.

stent-assisted coil embolization). Deconstructive endovascular procedures were only considered in cases of failed stent placement or high risk of stent placement procedure according to angiographic findings. Patients who underwent stent placement for angioplasty-induced intimal dissection, which occurred during endovascular treatment of atherosclerotic stenosis, were excluded in the study group. Twenty-eight were treated with proximal occlusion of the parent artery or occlusion at the dissection site. The remaining 14 patients, who were treated with stent placement or stent-assisted coiling, were included in our study. There were 8 men and 6 women in the study group, with age ranging from 33 to 67 years (mean age, 51 years). Demographic and clinical presentation data of the patient population are shown in Table 1. At presentation, 2 patients had SAH, 8 had thromboembolic or ischemic events, and 5 had headache.

Angiographic Findings and Indications for Stent Placement or Stent-Assisted Coiling

Angiograms were assessed for size, shape, and locations of the dissections with respect to the major branches and collaterals (ie, the presence or absence of the contralateral VA). Each lesion was examined for evidence of extension of the dissection into adjacent arterial segments, including the posterior inferior cerebellar artery (PICA) and basilar artery. Dissections were diagnosed if one or both of the following conditions were met: 1) The aneurysm was associated with angiographic features described below and 2) MR confirmed a false lumen involving the parent artery. The angiographic features in this study were divided into the following 4 groups: “pearl and string sign” (corresponding to a fusiform dilation associated with proximal or distal narrowing; 8 dissections), “string sign” (corresponding to an isolated irregular narrowing; 1 dissection), and fusiform dilation (5 dissections).

Patients were considered eligible for stent therapy, with or without adjunctive Guglielmi detachable coil (GDC) placement only if their dissecting aneurysm presented with SAH, they were unable to undergo anticoagulation, or if they had no other therapeutic option of acceptably low risk. The indications used to focus on arterial dissection included the presence of transient ischemic deficits (TIAs) or vertebrobasilar insufficiency (VBI) despite anticoagulant or antiplatelet therapy, contraindication to anticoagulant, contralateral vertebral occlusion or stenosis in a patient who was neurologically unstable or had clinical evidence of hemodynamic insufficiency, and documented poor collateral circulation.

Stent Placement or Stent-Assisted Coiling Procedures

Patients scheduled for elective procedures received oral acetylsalicylic acid (100 mg) and oral clopidogrel (75 mg) for 3 days before the stent procedure, and patients undergoing emergency procedures for acute SAH underwent combined antiplatelet therapy (oral clopidogrel 300 mg) on the day of surgery. All patients were kept on a regimen of both medications for 3 months, after which clopidogrel was no longer given.

The patients were placed in a state of local anesthesia and light neuroleptic anesthesia to allow continuous neurologic monitoring. After standard Seldinger puncture, a 6F or 7F introducer sheath was placed in the right femoral artery. After placement of a 6F or 7F guiding catheter (Envoy Max ID Multipurpose 90 cm; Cordis, Johnson and Johnson Medical, Miami Lakes, Fla) in the proximal VA, full systemic heparinization was achieved by administering a 2000–4000 IU bolus followed by hourly boluses of 1000 IU to maintain an activated clotting time of greater than 250 seconds. In patients who presented with acute SAH, heparinization started after first coil placement. Stents were positioned across diseased segments to have overlap on each side of the dissection orifice. For stent placement alone (11 patients), we used balloon-expandable stents currently applied in interventional cardiology, such as S670 (Medtronic AVE, Santa Rosa, Calif), Driver (Medtronic AVE), and Flexmaster (Jomed International, Helsingborg, Sweden), to achieve appropriate luminal diameter and sufficiently narrow strut size to occlude dissecting aneurysms. Four of these 11 patients underwent double overlapping stent placement to minimize the perforation size. For stent-assisted coiling (4 patients), a S670 or Neuroform stent (Boston Scientific/Target Therapeutics, Natick, Mass) was deployed after placement of a microcatheter (Prowler 14; Cordis, Johnson and Johnson Medical, or Excel 10; Boston Scientific/Target Therapeutics) in the dissecting aneurysm, and then coiling with GDCs (Boston Scientific/Target Therapeutics) was performed. After the final check angiogram, the catheter was removed and the sheath was left in the groin. The patient was moved to the neurosurgery intensive care unit for monitoring and received heparin 1000 IU/h for the next 24 hours. Heparinization was discontinued 24 hours after treatment but was not reversed.

Evaluations and Follow-Up

The technical feasibility of stent placement or stent-assisted coiling procedure was evaluated. Resolution of stenosis and occlusion of dissecting aneurysm after stent placement were evaluated. The grades of

Table 2: Summary of treatment options, complication related to treatment, and angiographic and clinical outcomes

Patient No.	Treatment	Stent Type and Size (mm)	Complications	Immediate AO	Follow-up AO at 6–12 Months	Follow-up MRS
1	SPA	AVE S670 4.0 × 24	None	Incomplete	Incomplete (stable)	1
2	SPA	AVE S670 3.5 × 30	None	Complete	Complete	1
3	SAC	AVE S670 3.5 × 24	None	Complete	Complete	0
4	SPA*	AVE S670 3.0 × 9, 3.0 × 12	None	Incomplete	Complete	1
5	SPA*	AVE S670 3.0 × 12, 3.5 × 12	None	Incomplete	Complete	0
6	SPA	AVE S670 4.0 × 30	None	Incomplete	Incomplete (stable)	1
7	SPA	AVE S670 3.0 × 24	None	Incomplete	Incomplete (stable)	0
8	SPA	AVE Microdrive 3.5 × 24	None	Incomplete	Incomplete (stable)	1
9	SAC	BS Neuroform 3.5 × 15	None	Incomplete	Incomplete (unstable)	2
10	SAC	BS Neuroform 4.0 × 20	None	Near complete	Complete	1
11	SAC	BS Neuroform 4.0 × 20	None	Incomplete	Complete	0
12	SPA*	AVE Microdrive 3.0 × 12, 3.5 × 12	None	Incomplete	Complete	1
13	SPA*	JOSTENT Flexmaster 2.75 × 19	Temporary vasospasm	Incomplete	Incomplete (stable)	1
		AVE Microdrive 2.75 × 24				
14	SPA	AVE Microdrive 3.5 × 24	None	Near complete	ND	1

Note:—AO indicates angiographic outcome; MRS, modified Rankin Scale; SPA, stent placement alone; SAC, stent-assisted coiling; AVE, Arterial Vascular Engineering; BS, Boston Scientific; ND, not done.

*Double stent method.

aneurysmal occlusion subsequent to coiling procedure were divided as complete (100% occluded), nearly complete ($\geq 95\%$ occluded), and incomplete ($<95\%$ occluded). These grades were determined by consensus of the reviewers (J.Y.A. and P.H.Y.).

The safety of this procedure was evaluated by the incidence of any procedure-related complications, including rupture of the aneurysm or parent vessel, and thromboembolic or hemorrhagic event during the procedure or within 30 days after the procedure.

Follow-up was determined by phone interview or from the most recent office note, and modified Rankin score (mRS) was assigned. Overall outcomes were defined as excellent, mRS 0–1; good, mRS 2; poor, mRS 3–4; or death, mRS 5. Follow-up angiography in 13 patients was performed at 6–12 months to determine whether the affected segment was smaller or healed. Further examination was obtained yearly if needed.

Results

Endovascular treatments are summarized in Table 2. All parent arteries of the patient who underwent the successful procedure were preserved. Stent release and positioning were considered optimal in 13 (92.9%) and suboptimal in 1. One patient (patient 13) had temporary vasospasm, which resulted in underestimation of the dissection and required a longer second stent positioned within the first.

Patients without Subarachnoid Hemorrhage

In 11 patients with dissecting aneurysm, immediate angiographic outcomes were complete occlusion (1 patient), nearly complete occlusion (2 patients), and incomplete occlusion (8 patients). Follow-up angiograms of 10 of these patients showed complete occlusion (6 patients) and incomplete occlusion (4 patients; all aneurysms were stable), and there was no evidence of in-stent-stenosis. In 5 patients with dissecting aneurysms, patients underwent 1 stent placement only; immediate angiographic outcomes were incomplete occlusion (4 patients) and nearly complete occlusion (1 patient). However, none of them showed complete occlusion of the aneurysm on follow-up angiograms (Fig 1). Only partial resolution of the aneurysm was demonstrated on follow-up angiograms. On the other hand, 3 dissecting aneurysms in which double stent

placement was performed achieved complete occlusion despite incomplete occlusion on immediate angiograms (Fig 2). In 3 patients with dissecting aneurysms, patients underwent stent-assisted GDC embolization; immediate angiographic outcomes were complete occlusion (1 patient), nearly complete occlusion (1 patient), and incomplete occlusion (1 patient). Follow-up angiograms of these revealed complete occlusion (3 patients; Fig 3). In 1 patient with irregular luminal narrowing on initial angiogram, follow-up angiogram showed complete restoration of vessel lumen after stent placement.

In 7 patients with ischemic stroke, there were no instances of postprocedural ischemic attacks, new neurologic deficits, or minor or major strokes during the follow-up periods of 6 to 40 (mean 28.5) months. In 5 patients with chronic headache, 2 patients (40%) were improved but 3 experienced persistent symptoms. On the mRS applied in follow-up, all patients were assessed as functionally improved or of stable clinical status.

Patients with Subarachnoid Hemorrhage

In 2 patients with SAH, 1 patient underwent stent-assisted GDC embolization and the other underwent double stent placement. Immediate angiographic outcomes of all patients were incomplete occlusion. Follow-up angiograms of these revealed one complete occlusion (patient 13) but a recanalized aneurysmal sac (patient 9) required repeat GDC embolization (Fig 4).

In 2 patients with subarachnoid hemorrhage, no recurrent hemorrhage occurred during the mean follow-up period of 12 to 18 (mean 15) months regardless of incomplete occlusion. One patient (patient 9) with sixth cranial nerve palsy was unable to carry out all previous activities but was able to look after her own affairs without assistance. The other patient (patient 13) with persistent headache was able to carry out all usual duties and activities.

Discussion

Approaches to endovascular treatment of dissecting aneurysms of the intracranial VA artery can be divided into deconstructive (involving occlusion or sacrifice of the parent artery) and reconstructive (preserving blood flow through the parent

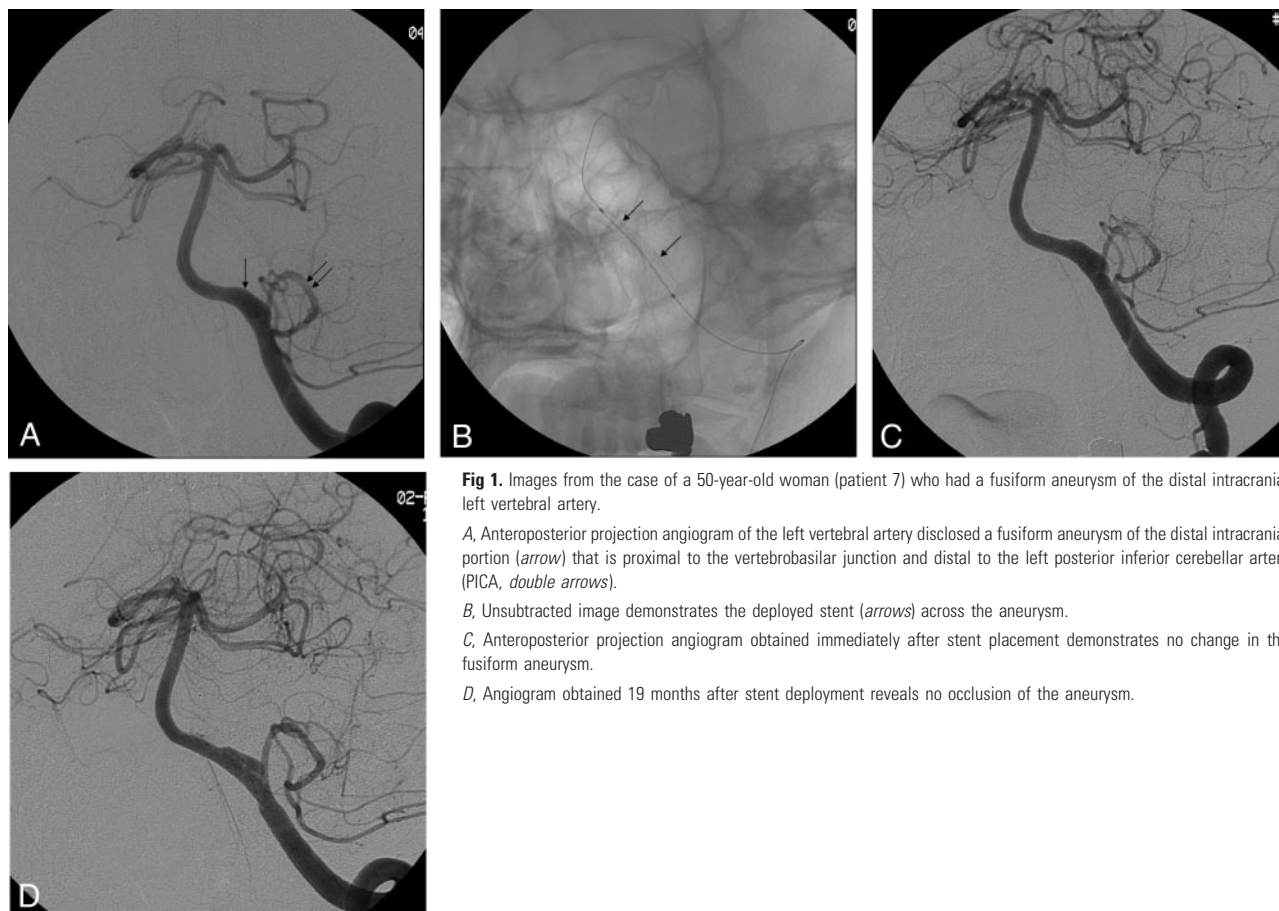


Fig 1. Images from the case of a 50-year-old woman (patient 7) who had a fusiform aneurysm of the distal intracranial left vertebral artery.

A, Anteroposterior projection angiogram of the left vertebral artery disclosed a fusiform aneurysm of the distal intracranial portion (*arrow*) that is proximal to the vertebrobasilar junction and distal to the left posterior inferior cerebellar artery (PICA, *double arrows*).

B, Unsubtracted image demonstrates the deployed stent (*arrows*) across the aneurysm.

C, Anteroposterior projection angiogram obtained immediately after stent placement demonstrates no change in the fusiform aneurysm.

D, Angiogram obtained 19 months after stent deployment reveals no occlusion of the aneurysm.

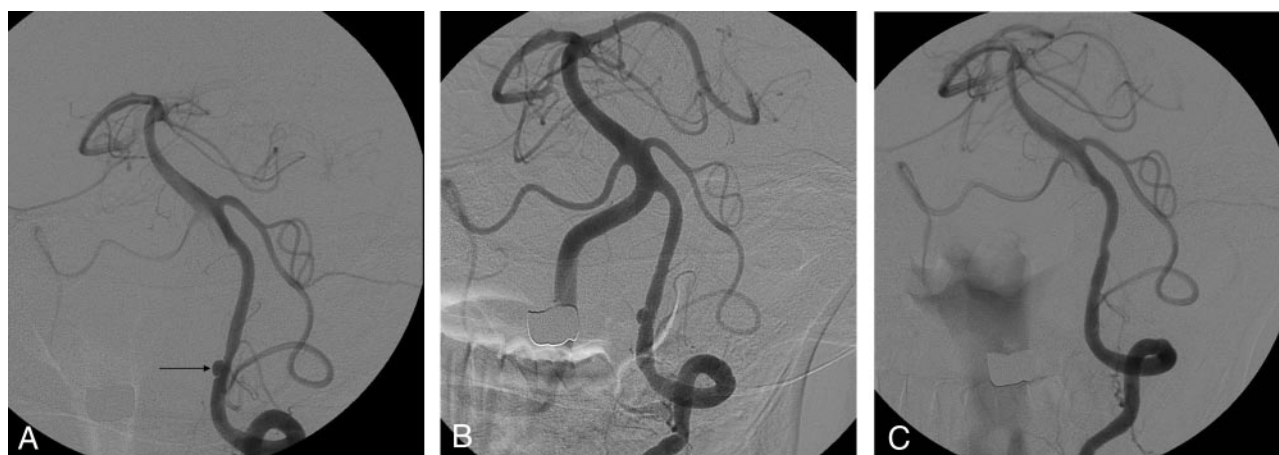

Fig 2. Angiograms in a 37-year-old man (patient 5) with dissecting aneurysm of the distal intracranial left vertebral artery treated with double stent method.

A, Anteroposterior projection shows a dissecting aneurysm of the distal intracranial left vertebral artery (*arrow*).

B, Angiogram obtained immediately after double stent placement demonstrates partial resolution of the aneurysm.

C, Angiogram obtained 6 months after double stent placement demonstrates complete healing of the aneurysm with restoration of the normal lumen.

vessel). Deconstructive endovascular techniques include proximal occlusion of the parent artery with detachable coils and/or balloons and occlusion of the dissected segment of the vessel with coils and/or balloons. Deconstructive procedures alone can be sufficient if important branch vessels are not incorporated in the segment of the vessel to be occluded, and collateral blood flow to the remainder of the posterior circulation is adequate. However, the dissected segment cannot be occluded in patients with involvement of PICA and/or a dom-

inant feeding pedicle to the anterior spinal artery in the dissected segment. The challenge also remains in those patients who are unable to tolerate parent vessel occlusion or cannot be monitored for vessel sacrifice because of their poor underlying neurologic condition secondary to the initial hemorrhage. On the contrary, reconstructive techniques preserve the parent vessel, which negates the need for revascularization when angiography reveals inadequate collateral flow or when the dissected segment involves major branch vessels. Reconstructive

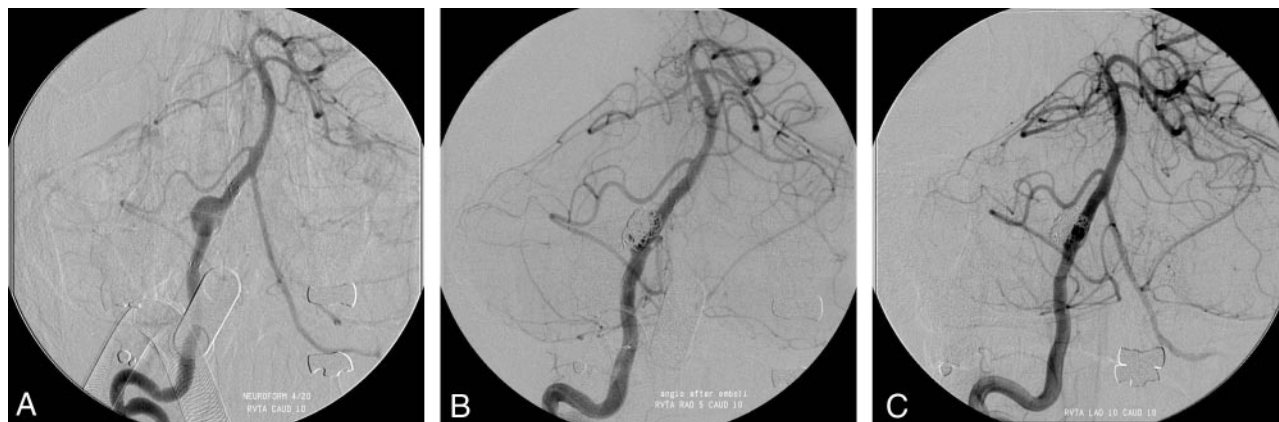

Fig 3. Angiograms in a 52-year-old man (patient 11) with dissecting aneurysm of the distal intracranial right vertebral artery treated with stent-assisted coiling.

A, The stent was placed across the aneurysm neck.

B, The aneurysm is occluded incompletely with coils.

C, Digital subtraction angiogram shows nearly completely occluded aneurysm with preservation of the parent artery.

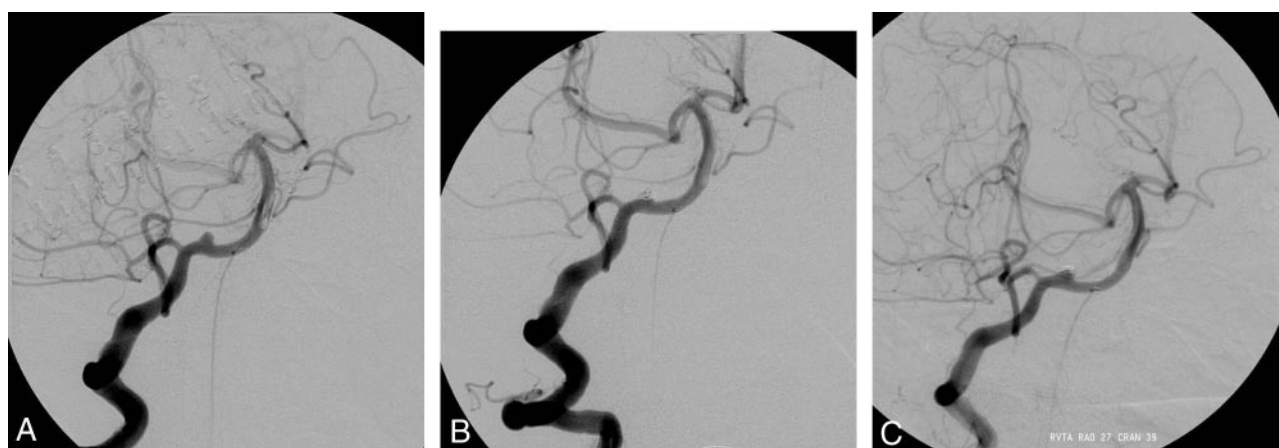


Fig 4. Images from the case of a 55-year-old woman (patient 9) who had suffered SAH from a wide-necked aneurysm of the distal intracranial right vertebral artery.

A, Anteroposterior projection angiogram of the right vertebral artery disclosed an aneurysm of the distal intracranial portion that is proximal to the vertebrobasilar junction and distal to the right posterior inferior cerebellar artery.

B, The aneurysm was occluded near completely with coils.

C, Angiogram obtained 3 months after stent-assisted coiling demonstrates recanalization of the neck.

endovascular techniques consist of stent placement, including double stent method and stent-assisted coil embolization. In theory, reconstructive procedures are more reasonable than deconstructive ones because we cannot predict the destiny of collateral vessels (such as atherosclerotic stenosis or vessel injury) for the rest of a patient's life. We thought that the more the parent artery was preserved, if possible, the better the prognosis.

Intracranial VA dissecting aneurysms usually have wide necks. There have been several reports for treatment of the wide-necked cerebral aneurysms with stent placement alone.^{12,13,18,19} Placement of a porous stent across the inflow zone alters the dynamics of blood flow, often reducing flow into the aneurysm. However, this technique has been successful clinically in only a few cases. Without complementary coils, the aneurysm generally remains open. Lanzino et al¹⁴ reported 4 patients who were originally treated with stent placement alone. In these patients, some stasis was observed angiographically, but it was insufficient for aneurysm occlusion, as observed immediately or during follow-up examinations per-

formed at 48 hours, 4 days, and 3 months after stent deployment. Five patients were treated with single stent placement alone in our series; however, none of them showed complete occlusion of the aneurysm on post-treatment or follow-up angiograms. By deploying a stent within a stent across the ostium of an aneurysm, the porosity of the stent construct can be decreased and the permeability of the stent might be significantly reduced.²⁰ This method can further alter the inflow within the aneurysm, promoting stasis and immediate thrombosis and safely allowing subsequent neointimal endothelial formation.¹² Dissecting aneurysms might be good candidates for the double stent method, because a stent might effectively tack down the torn vessel, resulting in aneurysm occlusion and no regrowth.^{13,19} However, there are some limitations in treatment for dissecting pseudoaneurysm with the double stent method. First, stent placement across the aneurysm can alter the inflow within the aneurysm, promoting intra-aneurysmal stasis; however, immediate postprocedural angiograms after double stent placement did not reveal complete obliteration of the dissecting aneurysm.^{12,13} Further-

more, it took a long time for the aneurysm to be completely obliterated. Although sufficient hemodynamic protection is at least anticipated, it may not completely prevent the ruptured dissecting aneurysm from rebleeding. Second, because of the thrombogenicity of the stent, anticoagulation and antithrombotic medications are generally required. This may contribute, at least in theory, to a delayed or absent aneurysm thrombosis and even repeated rupture in ruptured dissecting aneurysms. We treated 4 aneurysms with the double stent method and none of them showed complete occlusion of the aneurysm on the immediate post-treatment angiography. However, in 3 of 4 dissecting aneurysms, complete occlusion was achieved on follow-up angiograms despite incomplete occlusion on immediate angiograms.

Endovascular treatment by means of stents and coils has recently been applied to vertebral artery dissections.¹⁴⁻¹⁷ This method offers the advantage of parent vessel preservation, which obviates the need to consider whether collateral blood flow is sufficient to allow parent vessel sacrifice without neurologic deficit. Parent vessel preservation is also desirable because of the risk of vasospasm during the acute stage and the risk of bilateral dissection.^{16,21} This method, however, also has several technical and therapeutic limitations. First, in our method of stent deployment, recrossing the stent to gain access to the aneurysm is required. In most cases, this has not been a problem; however, significant problems may occur. Because of the low radial force of the Neuroform stent, which is close to the physiologic radial force of the intracranial arteries, vigorous microcatheter manipulation can induce stent displacement or stent folding.²² Second, stent-assisted coil placement of dissecting pseudoaneurysms may be associated with a higher risk compared with stent-assisted coil placement of saccular aneurysms because the former are friable. Their friability reflects their histology, which involves disruption of the intima, internal elastic lamina, media, and adventitia and formation of a pseudoaneurysm wall composed of fibrin, clot, and possible collagen deposition, depending on the age of the aneurysm.²³⁻²⁵ Introduction of a microcatheter and placement of coils into the ruptured dissecting aneurysm are, thus, very dangerous and carry the risk of rupture in the acute stage.²⁶ Third, in a fusiform dissecting aneurysm, stent-assisted coil embolization is usually limited. Coil loop protrusion through the stent interstices back into the parent artery may be difficult to detect because of superimposition of coils and stent meshwork. In addition, it may be difficult to adequately visualize the parent arterial lumen per se, once coils extend greater than a quarter of the vessel circumference. Finally, a number of cases of distal vertebral and basilar artery dissecting aneurysms have been treated with intravascular stent placement and coiling that had initial good angiographic appearance but later recurred, sometimes with recurrent bleeding.^{21,27} The exact mechanism of this phenomenon is not well understood, but it is probably due to the nature of vessel dissections, including the intima, the media, and the adventitia, resulting in a "pseudoaneurysm," in which there is only fibrin and thrombus at the rupture site. In our patient treated with stent-assisted coil embolization in the acute stage after SAH, the aneurysm was partially occluded; however, follow-up angiograms obtained 3 months after revealed recanalization and growth of the aneurysm. Therefore, it is impera-

tive to conduct close radiologic follow-up and monitor these patients at regular intervals to ensure that the patient is no longer at risk for recurrent aneurysm regrowth, rebleeding, and future disruption of the blood vessel at the treatment site.

Various stents can be used for restoration of luminal patency and occlusion. Stent selection must be individualized, based on factors including the characteristics and location of the lesion and the vessel diameter and geometry. We applied balloon-expandable stents (commercially multifarious) for stent placement only and used a self-expandable stent (Neuroform stent) for stent-assisted coiling. Otherwise, by deploying stent-grafts in the intracranial vasculature, the fusiform aneurysm can be sealed successfully in selective cases.²⁸ Stent-grafts represent a further therapeutic option for the treatment of direct arteriovenous fistulas, dissecting or fusiform aneurysms, or carotid blowouts caused by malignancy.^{29,30} However, the difficulty of placing these stents has been minimized as has the difficulty with crossing a major branch vessel. We are aware that stent-graft placement could be contraindicated in areas with high densities of perforating branches or in the sites of essential perforators. In addition, they have some disadvantages, such as increased thrombogenicity and inflammatory reaction with subsequent intimal hyperplasia. Of particular importance in the intracranial circulation is that they are less flexible than bare stents. However, stent technology is rapidly developing; in the future, covered stents may be used to achieve an immediate blood-tight seal across the neck of the pseudoaneurysm while preserving parent vessel patency. In addition, aneurysm coils with surface modifications intended to accelerate the thrombogenic and fibroblastic response may achieve more effective stent-assisted coil embolization in the treatment of patients with intracranial VA dissecting aneurysms.

Conclusions

Dissection-induced stenosis or pseudoaneurysms of intracranial VA were acceptably treated with stent placement or stent-assisted coiling, and the patency could be preserved at follow-up. However, the efficiency of stent placement alone for intracranial VA dissecting aneurysm was limited. Stent-assisted coil embolization and double stent placement are viable alternatives for complete occlusion of dissecting aneurysms. Therefore, the long-term efficacy and durability of stent placement for arterial dissections remains to be determined in a large series.

References

1. de Bray JM, Penisson-Besnier I, Dubas F, et al. **Extracranial and intracranial vertebrobasilar dissections: diagnosis and prognosis.** *J Neurol Neurosurg Psychiatry* 1997;63:46-51
2. Yoshimoto Y, Wakai S. **Unruptured intracranial vertebral artery dissection: clinical course and serial radiographic imagings.** *Stroke* 1997;28:370-74
3. Schievink WI. **Spontaneous dissection of the carotid and vertebral arteries.** *N Engl J Med* 2001;344:898-906
4. Fisher CM, Ojemann RG, Robertson GH. **Spontaneous dissection of cervicocerebral arteries.** *Can J Neurol Sci* 1978;5:9-19
5. Droste DW, Junker K, Stögbauer F, et al. **Clinically silent circulating microemboli in 20 patients with carotid and vertebral dissection.** *Cerebrovasc Dis* 2001;12:181-85
6. Srinivasan J, Newell DW, Sturzenegger M, et al. **Transcranial Doppler in the evaluation of internal carotid artery dissection.** *Stroke* 1996;27:1226-30
7. Martin PJ, Humphrey PR. **Disabling stroke arising five months after internal carotid artery dissection [letter].** *J Neurol Neurosurg Psychiatry* 1998;65:136-37

8. Aoki N, Sakai T. **Rebleeding from intracranial dissecting aneurysm in the vertebral artery.** *Stroke* 1990;21:1628–31
9. Mizutani S, Aruga T, Kirino T, et al. **Recurrent subarachnoid hemorrhage from untreated ruptured vertebrobasilar dissecting aneurysms.** *Neurosurgery* 1995;36:905–13
10. Kitanaka C, Sasaki T, Eguchi T, et al. **Intracranial vertebral artery dissections: clinical, radiological features, and surgical considerations.** *Neurosurgery* 1994;34:620–27
11. Kurata A, Ohmomo T, Miyasaka Y, et al. **Coil embolization for the treatment of ruptured dissecting vertebral aneurysms.** *AJNR Am J Neuroradiol* 2001;22:11–18
12. Mehta B, Burke T, Kole M, et al. **Stent-within-a-stent technique for the treatment of dissecting vertebral artery aneurysms.** *AJNR Am J Neuroradiol* 2003;24:1814–18
13. Benndorf G, Herbon U, Sollmann W, et al. **Treatment of a ruptured dissecting vertebral artery aneurysm with double stent placement: case report.** *AJNR Am J Neuroradiol* 2001;22:1844–48
14. Lanzino G, Wakhloo AK, Fessler RD, et al. **Efficacy and current limitations of intravascular stents for intracranial internal carotid, vertebral, and basilar artery aneurysms.** *J Neurosurg* 1999;91:538–46
15. Lylyk P, Cohen JE, Ceratto R, et al. **Combined endovascular treatment of dissecting vertebral artery aneurysms by using stents and coils.** *J Neurosurg* 2001;94:427–32
16. Phatouros CC, Sasaki TY, Higashida RT, et al. **Stent-supported coil embolization: The treatment of fusiform and wide-neck aneurysms and pseudoaneurysms.** *Neurosurgery* 2000;47:107–15
17. Ahn JY, Chung SS, Lee BH, et al. **Treatment of spontaneous arterial dissections with stent placement for preservation of the parent artery.** *Acta Neurochir (Wien)* 2005;147:265–73
18. Vanninen R, Manninen H, Ronkainen A. **Broad-based intracranial aneurysms: thrombosis induced by stent placement.** *AJNR Am J Neuroradiol* 2003;24:263–66
19. Doerfler A, Wanke I, Egelhof T, et al. **Double-stent method: therapeutic alternative for small wide-necked aneurysms.** *J Neurosurg* 2004;100:150–54
20. Lieber BB, Stancampiano AP, Wakhloo AK. **Alteration of hemodynamics in aneurysm models by stenting: influence of stent porosity.** *Ann Biomed Eng* 1997;25:460–69
21. Redekop G, TerBrugge K, Willinsky R. **Subarachnoid hemorrhage from vertebrobasilar dissecting aneurysm treated with staged bilateral vertebral artery occlusion: the importance of early follow-up angiography: technical case report.** *Neurosurgery* 1999;45:1258–62
22. Benitez RP, Silva MT, Klem J, et al. **Endovascular occlusion of wide-necked aneurysms with a new intracranial microstent (Neuroform) and detachable coils.** *Neurosurgery* 2004;54:1359–67
23. Endo S, Nishijima M, Nomura H, et al. **A pathological study of intracranial posterior circulation dissecting aneurysm with subarachnoid hemorrhage: report of three autopsied cases and review of the literature.** *Neurosurgery* 1993;33:732–38
24. Mizutani T, Kojima H, Asamoto S, et al. **Pathological mechanism and three-dimensional structure of cerebral dissecting aneurysms.** *J Neurosurg* 2001;94:712–17
25. Yasui T, Komiyama M, Nishikawa M, et al. **Fusiform vertebral artery aneurysms as a cause of dissecting aneurysms: report of two autopsy cases and a review of the literature.** *J Neurosurg* 1999;91:139–44
26. Sugiu K, Takahashi K, Muneta K, et al. **Rebleeding of a vertebral artery dissecting aneurysm during stent-assisted coil embolization: a pitfall of the “stent and coil” technique.** *Surg Neurol* 2004;61:365–70
27. MacKay CI, Han PP, Albuquerque FC, et al. **Recurrence of a vertebral artery dissecting pseudoaneurysm after successful stent-supported coil embolization: case report.** *Neurosurgery* 2003;53:754–61
28. Chiaradio JC, Guzman L, Padilla L, et al. **Intravascular graft stent treatment of a ruptured fusiform dissecting aneurysm of the intracranial vertebral artery: technical case report.** *Neurosurgery* 2002;50:213–16
29. Alexander MJ, Smith TP, Tucci DL. **Treatment of an iatrogenic petrous carotid artery pseudoaneurysm with a Symbiot covered stent: technical case report.** *Neurosurgery* 2002;50:658–62
30. Felber S, Henkes H, Weber W, et al. **Treatment of extracranial and intracranial aneurysms and arteriovenous fistulae using stent grafts.** *Neurosurgery* 2004;55:631–39