Are your MRI contrast agents cost-effective?
Learn more about generic Gadolinium-Based Contrast Agents.
FRESENIUS KABI
caring for life

AJNR

Inflammatory Myofibroblastic Tumor of the Nasal Cavity

V. Lai, Y.C. Wong, W.Y. Lam, W.C. Tsui and S.H. Luk

AJNR Am J Neuroradiol 2007, 28 (1) 135-137
http://www.ajnr.org/content/28/1/135

This information is current as of April 19, 2024.

CASE REPORT

Inflammatory Myofibroblastic Tumor of the Nasal Cavity

V. Lai
Y.C. Wong
W.Y. Lam
W.C. Tsui
S.H. Luk

SUMMARY: Inflammatory myofibroblastic tumor (IMT) is a rare tumor with a variable natural history and biologic behavior, ranging from completely benign to malignant with fatal outcome. We report a case of benign IMT in the left nasal cavity with radiologic features mimicking angiofibroma. We also demonstrate the hypervascular nature of this disease on angiography and the contribution of preoperative embolization in assisting surgical excision and minimizing the potential uncontrolled intraoperative bleeding.

Inflammatory myofibroblastic tumor (IMT) is an uncommon tumor that occurs most frequently in the lung, abdominal cavity, retroperitoneum, and extremities. Occurrence in the upper respiratory tract is uncommon but has been reported. To date, fewer than 30 cases had been described in the nasal cavity and paranasal sinuses.[1] It is now recognized as a neoplastic process that usually follows a rather benign clinical course after radical excision, but cases of invasive, locally recurrent, and metastatic forms have been reported.[2]

The diagnosis of IMT is difficult to establish before surgery because of its diversified radiologic manifestations. At one extreme, advanced disease is often misdiagnosed as a malignant tumor because of extensive infiltration and bony destruction.[3] At the other extreme, it simulates various benign lesions in its earliest stage when it is confined to the mucosa.[1]

Herein, we report a case of IMT in the left nasal cavity of a 13-year-old girl with imaging findings mimicking juvenile angiofibroma.

Case Report

In September 2001, a 13-year-old girl with a history of good health presented with recurrent nontraumatic left-sided epistaxis for 6 months, requiring gelatin sponge (Spongostan Standard; Johnson & Johnson, Skipton, UK) insertion for bleeding control. CT of the paranasal sinuses showed a heterogeneous enhancing soft-tissue mass in the left posterior nasal cavity with infiltration into the nasopharyngeal roof (Fig 1*A*) and widening of sphenopalatine foramen (Fig 1*B*). MR images showed that the lesion had T1-weighted hypointense and T2-weighted intermediate-signal-intensity changes (Fig 2*A*) with homogeneous contrast enhancement (Fig 2*B*). Angiography revealed the hypervascular nature of the tumor, with blood supplied by mildly hypertrophied terminal branches of the left internal maxillary artery (Fig 3*A*). There was attenuated tumor staining with slow washout during the capillary phase (Fig 3*B*), but no intratumoral arteriovenous shunt surgery was discerned. In view of the unique location involving the sphenopalatine foramen and nasopharyngeal roof, associated bone remodeling, and hypervascular nature, a presumptive diagnosis of angiofibroma was made.

With the anticipation of a great risk of bleeding and difficulty in hemostasis during operative excision, superselective embolization of the feeding arteries with Ivalon 250–355 μm (Contour, Boston Scientific, Natick, Mass) was performed 2 days before surgery. Postembolization angiograms revealed almost complete elimination of the tumor vascularity.

Transnasal excision of the left nasal mass, performed in April 2002, revealed a granular mass over the posterior end of left nasal cavity. The postoperative course was uneventful, and hemostasis was achieved with ribbon gauze coated with bismuth iodoform paraffin paste. The patient remained well and was discharged 3 days later.

Biopsy of the tumor revealed the mass to be IMT composed of a storiform array of compact spindle cells sprinkled with inflammatory cells, including lymphocytes, plasma cells, and foamy histiocytes (Fig 4). The neoplastic cells showed myofibroblastic phenotype and reacted immunologically with vimentin and alpha-smooth muscle actin. They also showed the diagnostic immunoreactivity with anaplastic lymphoma kinase. Staining for acid-fast bacilli, fungi, CD34, and S100 was negative.

In view of such findings, results of a chest radiograph, performed to rule out a possible concomitant lung lesion, were negative. Immune markers were negative. Follow-up nasoendoscopy and CT in August 2002 and December 2002, respectively, showed no evidence of recurrence. The patient remained well with no recurrence of epistaxis.

Discussion

IMT is most commonly found in the lung, abdomen, retroperitoneum, and extremities, and its occurrence in the head and neck region is less common. There is no age preference identified, with equal incidence in male and female patients.[4] It should be regarded as a soft-tissue mesenchymal tumor with low malignant potential, related to inflammatory fibrosarcoma. Whether individual IMT is a neoplastic or a reactive process is controversial, but at least a subset of IMT represents true neoplasia rather than reactive myofibroblastic proliferation.[2]

Although IMT appears to be clinicopathologically distinctive, its natural history, clinical behavior, and prognosis are highly diverse, ranging from being completely benign to malignant with fatal outcome. Histologic attributes of IMT in general do not allow prediction of the biologic behavior. Tumors with a high content of large ganglion-like tumor cells may behave more aggressively.[5] Treatment and clinical outcome are generally favorable, with the first-line treatment being surgical excision, in combination with corticosteroid therapy, radiation therapy, and/or chemotherapy. A recurrence rate of up to 37% was reported however.[1]

Sinonasal IMT has been rarely described in the literature. Indeed, confusion arises from different synonyms attached to the disease: plasma cell granuloma, inflammatory pseudotumor, mast cell granuloma, xanthogranuloma, histiocytoma,

Received October 20, 2005; accepted after revision November 30.

From the Departments of Diagnostic Radiology (V.L., Y.C.W., W.C.T., S.H.L.) and Pathology (W.Y.L.), Tuen Mun Hospital, Tuen Mun, Hong Kong, China.

Please address correspondence to: V. Lai, MBChB, Department of Diagnostic Radiology, Tuen Mun Hospital, Tuen Mun, Hong Kong, China; e-mail: vincentlai@hkcr.org

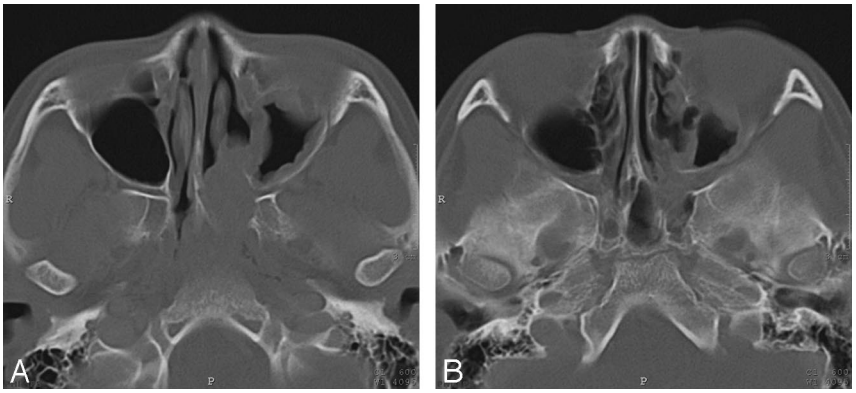

Fig 1. *A,* CT scan shows soft-tissue mass in the left nasal cavity with infiltration into the nasopharyngeal roof.

B, CT scan shows soft-tissue mass in the left posterior nasal cavity with widening of the left sphenopalatine foramen, suggestive of direct infiltration.

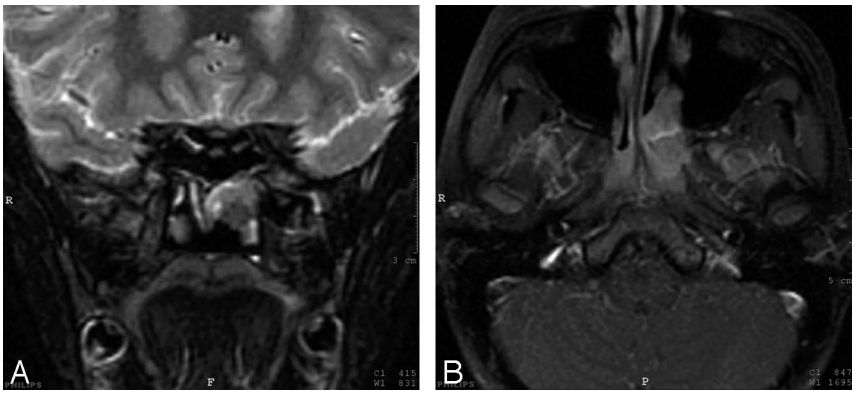

Fig 2. *A,* T2-weighted coronal image shows a soft-tissue mass of intermediate signal intensity in the left posterior nasal cavity.

B, Postcontrast T1-weighted axial image shows homogeneous enhancement of the soft-tissue mass with no internal signal-intensity void areas to suggest hypertrophied vasculature.

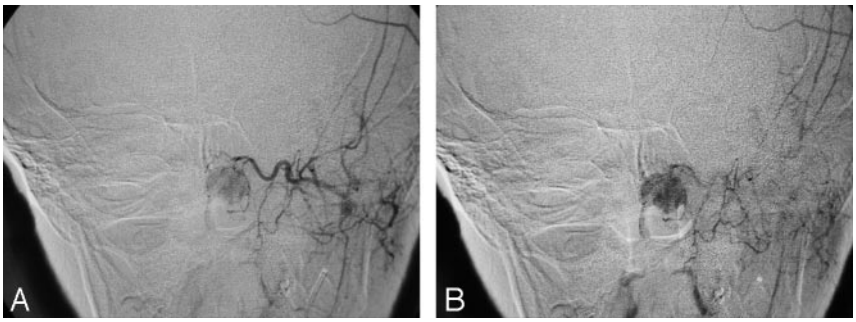

Fig 3. *A,* Angiogram reveals the hypervascular nature of the tumor, supplied by the mildly hypertrophied terminal branches of the left internal maxillary artery.

B, Capillary phase shows attenuated tumor staining with slow washout.

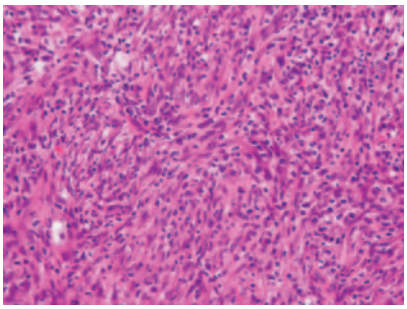

Fig 4. This nasal inflammatory myofibroblastic tumor is composed of a storiform array of plump spindle cells with a background of chronic inflammatory infiltrate (hematoxylin-eosin, original magnification × 200).

and inflammatory myofibroblastic/myofibrohistiocytic proliferation. Such diverse nomenclature illustrates the variations in histopathologic subtypes.[4,6] The symptoms are nonspecific and highly diverse, with the patient usually presenting with a nonspecific mass that has been growing over a period of months or years.[2] Associated findings may include microcytic hypochromic anemia, hypergammaglobulinemia, and high erythrocyte sedimentation rate. Fever and associated inflammatory component with reticulation of adjacent fat have also been reported.[4] To date, to our knowledge, the occurrence of epistaxis had not been mentioned in the literature.

Endoscopy may reveal a polyp or edematous mucosa, often easily misdiagnosed at an early stage. In the limited previous case reports, sinonasal osseous destruction was a constant finding. Usually at least 1 sinus wall was destroyed, with the principal site affected being the intersinonasal wall.[2] In view of its extensive infiltration and bony destruction, a preoperative diagnosis of malignant tumor is often made. At the other end of the spectrum, IMT may sometimes present in an early stage in which it is confined to mucosa without bone destruction. The morphologic appearance may thus simulate other inflammatory lesions.

In our case, the radiologic features closely resemble those of angiofibroma. These include involvement of the sphenopalatine foramen, extension to the nasopharyngeal roof, remodeling of local osseous structures, and associated hypervascularity. Although commonly found in male adolescents, angiofibroma occasionally affects young female

patients,[7-9] and female gender does not necessarily negate such diagnosis.

To our knowledge, the angiographic findings of IMT have not been described previously. Our case illustrates that IMT can be hypervascular on angiography, manifesting mainly as mildly hypertrophied feeding arteries and intense tumor staining without intratumoral arteriovenous shunt surgery. Whether such findings are characteristic of IMT has to be verified by future case reports. However, it is reasonable to believe that the rich tumor vascularity is the cause for epistaxis, which can be recurrent and intractable for large tumor. The knowledge of potential hypervascularity has important implications for overall management of this rare condition because preoperative biopsy is often required to establish the diagnosis and excision is needed for permanent cure in many cases. Especially for large tumor, the identification of tumor hypervascularity can warn us of the risk of intraoperative hemorrhage. As in our patient, preoperative selective embolization of the feeding artery can be performed to facilitate surgical excision and to reduce the potential uncontrolled bleeding and, hence, subsequent morbidity and mortality.

In conclusion, we present a rare case of sinonasal inflammatory myofibroblastic tumor with imaging findings mimicking angiofibroma. The clinical symptom of recurrent epistaxis and the associated hypervascularity documented by angiography give insight into its diversified phenotypic behavior and also alert us to the risk of intraoperative hemorrhage in similar cases.

References

1. Zhou SH, Ruan LZ, Xu YY, et al. **Inflammatory myofibroblastic tumour in the left maxillary sinus: a case report.** *Chin Med J (Engl)* 2004;117:1597–99
2. Gale N, Zidar N, Podboj J, et al. **Inflammatory myofibroblastic tumour of paranasal sinuses with fatal outcome: reactive lesion or tumour?** *J Clin Pathol* 2003;56:715–17
3. Huang DL. **Inflammatory pseudotumour of nasal cavity** [in Chinese]. *Zhonghua Er Bi Yan Hou Ke Za Zhi* 1993;28:233–35, 253
4. De Oliveira Ribeiro AC, Joshi VM, Funkhouser WK, et al. **Inflammatory myofibroblastic tumour involving the pterygopalatine fossa.** *AJNR Am J Neuroradiol* 2001;22:518–20
5. Coffin CM, Humphrey PA, Dehner LP. **Extrapulmonary inflammatory myofibroblastic tumour: a clinical and pathological survey.** *Semin Diagn Pathol* 1998;15:85–101
6. Som PM, Brandwein MS, Maldjian C, et al. **Inflammatory pseudotumour of the maxillary sinus: CT and MR findings in six cases.** *AJR Am J Roentgenol* 1994;163:689–92
7. Celik B, Erisen L, Sarayaroglu O, et al. **Atypical angiofibromas: a report of four cases.** *Int J Pediatr Otorhinolaryngol* 2005;69:415–21
8. Marcos Garcia M, Pino Rivero V, Pardo Romero G, et al. **Nasal angiofibroma in a 60 year-old female: a clinical case and literature review** [in Spanish]. *Acta Otorrinolaringol Esp* 2004;55:195–97
9. Hong Y, Liang Z, Lin P. **The diagnosis and treatment of nasopharyngeal angiofibroma** [in Chinese]. *Lin Chuang Er Bi Yan Hou Ke Za Zhi* 2004;18:33–34