

Are your **MRI contrast agents** cost-effective?

Learn more about generic **Gadolinium-Based Contrast Agents**.



AJNR

Complex Curve Microcatheters for Berry Aneurysm Endovascular Therapy

R.S. Pakbaz and C.W. Kerber

AJNR Am J Neuroradiol 2007, 28 (1) 179-180

<http://www.ajnr.org/content/28/1/179>

This information is current as of May 5, 2024.

R.S. Pakbaz
C.W. Kerber

Complex Curve Microcatheters for Berry Aneurysm Endovascular Therapy

SUMMARY: By using images created with 3D rotational angiography or CT angiography as templates, it is possible to place anatomically correct curves on microcatheters, curves that reproduce the complex 3D vascular anatomy of individual patients. Catheters so curved conform to the anatomy of arteries leading to aneurysms and are less likely to be forced out of position as coil packing progresses.

The first catheter cerebral angiograms were performed with straight, uncurved catheters and, not surprisingly, cost operators much time to complete.¹ Catheter cerebral angiography as a technique did not gain clinical acceptance until angiographers learned to place complex curves at the tip of a catheter, which resulted in faster, safer, and more selective studies.²⁻⁵ The next iteration was the invention and refinement of microcatheters (small complex catheters introduced through larger guiding catheters). These smaller catheters allowed even more selective angiography and hastened the evolution of interventional techniques.⁶⁻⁹ We now easily access and treat fourth- and fifth-order cerebral branches, despite the multiple S bends in arteries at the base of the brain.

Although it is relatively straightforward to place the tip of a microcatheter into a cerebral berry aneurysm for detachable coil delivery, as endovascular treatment of that aneurysm progresses, it is common to find the tip of the catheter being pushed out of the aneurysm, sometimes making safe or complete coil delivery impossible. Apparently, we face the same problem today that our diagnostic predecessors solved with their complex diagnostic tip shapes.

We wondered if complex 3D curves that reproduce the patient's arterial anatomy (curves that cause the microcatheter to bear on the greater curvature of the arteries leading to the aneurysm) were placed on our catheters, whether the microcatheter might be less prone to displacement out of an aneurysm sac during introduction of coils. We used 3D images created from conventional angiography to custom form catheters to fit the unique anatomies of 15 individual patients, and we used these catheters during treatment of their aneurysms.

Description of Technique

Fifteen consecutive patients with known cerebral vascular pathology were examined by catheter rotational angiography (Fig 1A, -B). These patients then underwent treatment with endovascular coils.

On the workstation, the arterial segments beginning at the aneurysm and extending proximally for the next 3 major curves were measured from greatest curvature to greatest curvature (Fig 1C). The microcatheter-forming wire was then bent in 3 dimensions to reflect those measurements (Fig 1D). The resulting curve was then exaggerated to allow for the expected straightening when the microcatheter would be introduced into the bloodstream (Fig 1E).

The forming wire was placed in the microcatheter, and these curves were set in the tip of the microcatheter with a steam generator. Figure 1F shows the finished 3D curves on the microcatheter.

Results

The time needed to reconstruct arteries on current workstations is well known and requires only minutes. Additionally, it took several minutes of repeated viewing of the rotating images to develop some understanding of the anatomy. The main measurements were then determined in less than a minute. On average, in less than 5 minutes of workstation time, we were able to make appropriate measurements, bend the forming wire, and steam shape the catheter tip to exaggerate the human carotid curves.

All 15 patients had satisfactory endovascular treatment of their aneurysms. No catheter backed out of the aneurysm and no patient suffered a complication.

Discussion

The early history of selective catheter cerebral angiography reveals what now appears to be an excessive number of technical papers describing (often eponymous) catheter curves, curves that, in each author's hands, would allow engagement of and entry into desired vessels. Early angiography teachers emphasized the need to create complex 3D curves to keep catheters in position during injection. It appears that we now have a similar need with our microcatheters.

Cerebral blood flow dynamics make it easy to enter an aneurysm, but uncurved or simply curved catheters are often easily displaced from aneurysms as treatment and packing progress.

The 3D angiogram (or a 3D CT angiogram) allows accurate measurements to be made for placing 3D curves on catheters. When these curves permit a catheter to bear on arterial curvatures, it appears, at least in our early experience, that the microcatheter does not back out of the aneurysm during treatment. However, not all microcatheters tolerate the bending process equally well. Kiyosue and coworkers have studied currently available microcatheters and have found (in some) unacceptable wall irregularities that have appeared after steam shaping, irregularities that could lead to difficulty in coil delivery.¹⁰

Not all catheters are easily shaped. Braided catheters are especially difficult to shape adequately (and for this reason we overdo the bends; see Fig 1E), but we have found that lengthened times (up to 30–40 seconds) in steam followed immediately by a cold water quench in sterile saline allows even these catheters to hold the complex curves.

Some operators have found it difficult to bring complex curved catheters into the aneurysm; for example, when a catheter lies 1 cm or so proximal to the aneurysm orifice, the final bend points in the wrong direction (ie, away from the orifice). We have found that leading the catheter with a guidewire until

Received March 8, 2006; accepted after revision June 2.

From the Department of Radiology, UCSD Medical Center, San Diego, Calif.

Address correspondence to Charles Kerber, MD, UCSD Medical Center, 200 W. Arbor Dr, San Diego, CA 92103-8756; e-mail: kaos@ucsd.edu

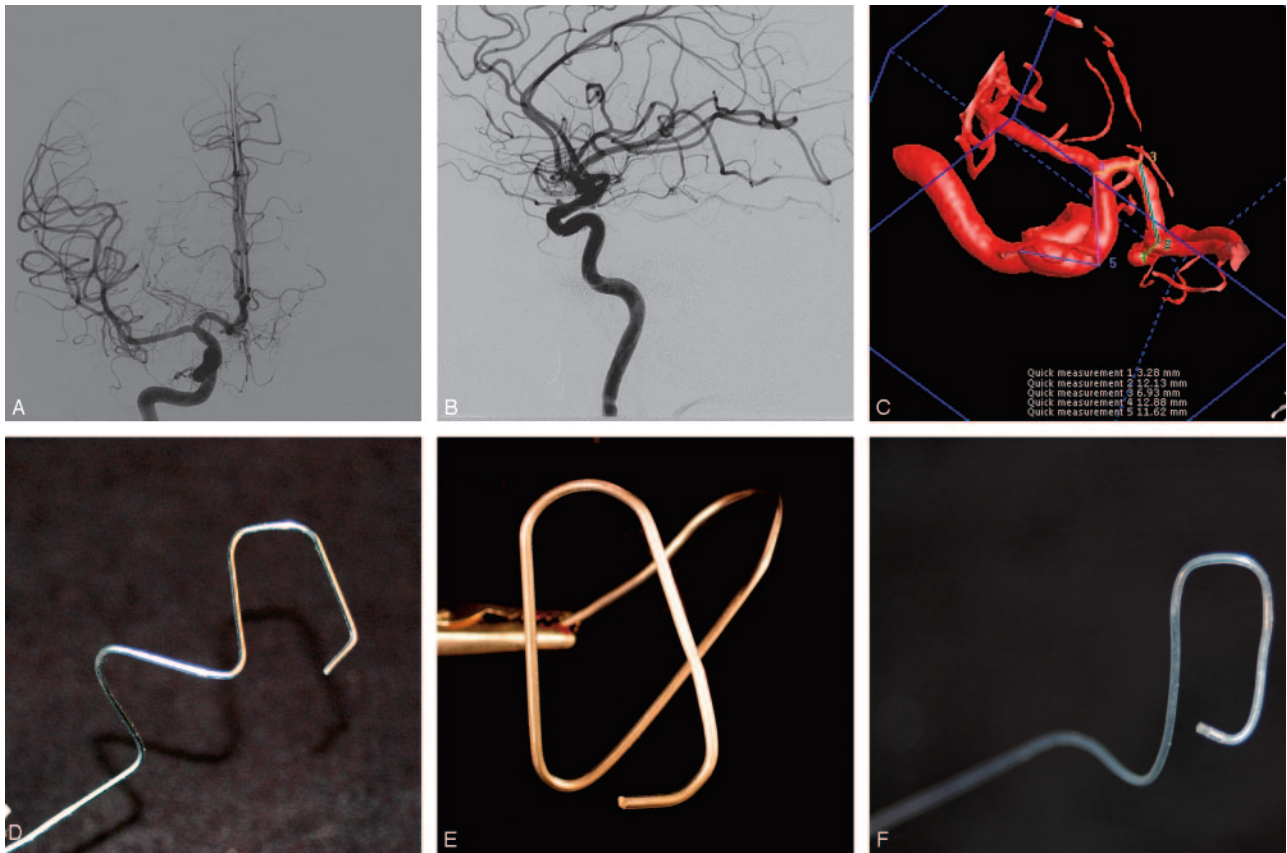


Fig 1. Steps used to analyze and create the correct catheter configuration.

- A, Frontal angiographic arterial phase angiogram.
- B, Lateral angiographic arterial phase angiogram.
- C, Workstation image, from above, showing the major measurements.
- D, Forming wire bent to conform to the measurements seen on the workstation.
- E, Curved accentuation of the forming wire. The shape is made simply by taking the original angles and doubling them.
- F, Microcatheter after steaming and removal of the forming wire.

the tip is just beyond the orifice, and only then removing the guidewire, will allow the tip to enter the aneurysm.

Because these compound curves hold the catheter into the aneurysm with some force, one risk becomes immediately apparent. If the catheter distal tip is allowed to bear on (to place an axial load on) a weakened portion of the aneurysm (eg, into the point of rupture), we would expect an increased risk of aneurysm perforation as the coils exit the tip of the catheter. We are therefore careful to measure and bend the distal curve of the catheter so that the tip does not end within the dome of the aneurysm, but instead lies within the midportion of the aneurysm.

References

1. Radner S. Intracranial angiography via the vertebral artery. Preliminary report on a new technique. *Acta Radiol* 1947;28:838–42
2. Hanafee W. Axillary artery approach to carotid, vertebral, abdominal aorta, and coronary angiography. *Radiology* 1963;81:559–67
3. Mani RL. A new double curve catheter for selective femorocerebral angiography. *Radiology* 1970;94:607–11
4. Newton TH. The axillary artery approach to arteriography of the aorta and its branches. *Am J Roentgenol Radium Ther Nucl Med* 1963;89:275–83
5. Rosch J. Superselective arteriography in a diagnosis of abdominal pathology: technical considerations. *Radiology* 1969;92:1008–13
6. Serbinenko FA. Catheterization and occlusion of major cerebral vessels and prospects for the development of vascular neurosurgery. *Vopr Neurokhir* 1971; 35:17–27 [in Russian]
7. Kerber C. Balloon catheter with a calibrated leak. *Radiology* 1976;120:547–50
8. Rufenacht DMJ. A new and original microcatheter system for hyperselective catheterization and endovascular treatment without risk of arterial rupture. *J Neuroradiol* 1986;13:44–54
9. Komiyama M, Yasui T, Fu Y, et al. A new microcatheter system for a vascular treatment of cerebral arteriovenous malformations. *Surg Neurol* 1989;32: 91–97
10. Kiyosue H, Hori Y, Matsumoto S, et al. Shapability, memory, and luminal changes in microcatheters after steam shaping: a comparison of 11 different microcatheters. *AJNR Am J Neuroradiol* 2005;26:2610–16