

Generic Contrast Agents

Our portfolio is growing to serve you better. Now you have a *choice*.



[VIEW CATALOG](#)

AJNR

Effect on Partial Pressure of Oxygen in Arterial Blood in Percutaneous Vertebroplasty

A. Uemura, Y. Numaguchi, M. Matsusako, N. Kobayashi, Y. Saida and M. Rahman

This information is current as of May 8, 2025.

AJNR Am J Neuroradiol 2007, 28 (3) 567-569
<http://www.ajnr.org/content/28/3/567>

A. Uemura
Y. Numaguchi
M. Matsusako
N. Kobayashi
Y. Saida
M. Rahman

Effect on Partial Pressure of Oxygen in Arterial Blood in Percutaneous Vertebroplasty

BACKGROUND AND PURPOSE: The purpose of this study is to estimate the change in partial pressure of oxygen (PaO_2) during percutaneous vertebroplasty and also to examine the factors related to the change in PaO_2 .

MATERIALS AND METHODS: We retrospectively reviewed preprocedural and postprocedural PaO_2 of 59 consecutive patients who underwent percutaneous vertebroplasty between November 2003 and April 2005 (11 men and 48 women; age range, 50–93; mean age, 75 years). Fifty-four patients were treated for osteoporosis-related fractures and 5 had malignant disease. Percutaneous vertebroplasty was performed in a conventional manner under local anesthetics and conscious sedation. Preprocedural and postprocedural blood drawing was performed 5 days to 30 minutes before percutaneous vertebroplasty and also at 30 minutes after the injection of bone cement. The difference between preprocedural and postprocedural data of PaO_2 was correlated with patients' age, number of treated vertebral bodies, presence of cement leakage, and presence of malignant neoplasm for each patient.

RESULTS: Mean pre- PaO_2 and post- PaO_2 were 80.9 ± 1.4 and 70.6 ± 1.3 mm Hg (mean \pm SE) respectively ($P = .0001$). Using analysis of variance, there was a significant difference according to the number of vertebral bodies. There was a positive trend of decrease in PaO_2 according to the number of vertebral bodies during percutaneous vertebroplasty. Using multiple linear regression and after adjusting by preprocedural PaO_2 and other variables, the number of vertebral bodies was still highly significant.

CONCLUSION: PaO_2 decreases during percutaneous vertebroplasty, and there is a correlation between the number of treated vertebral bodies and decrease in PaO_2 .

Cardiopulmonary disorder is one of the most serious complications during percutaneous vertebroplasty. Transient hypotension during percutaneous vertebroplasty has been reported.¹ Kaufmann et al² reported that oxygen saturation was significantly lower at 10 minutes after injection of polymethylmethacrylate (PMMA) than before injection, though the mean difference was negligible. The potential risk of cardiopulmonary changes during percutaneous vertebroplasty is of interest because percutaneous vertebroplasty is now widely implemented.

The purpose of this study was to estimate the change in partial pressure of oxygen (PaO_2) during percutaneous vertebroplasty and also to examine the factors related to the change in PaO_2 .

Materials and Methods

All procedures were performed according to institutional review board-approved guidelines. We extracted the relevant data from the medical records of 59 consecutive patients (11 men and 48 women) who underwent percutaneous vertebroplasty between November 2003 and April 2005. Patients' age range was 50–93 with mean age 75 years. The number of vertebral bodies treated was similar in terms of categories (1, $n = 17$; 2, $n = 19$; ≥ 3 , $n = 23$). The level of vertebral bodies was from T6 to L5. Fifty-four patients had compression fractures as a result of osteoporosis, and 5 patients had malignant neo-

plasm. Cement leakage was evaluated on a postprocedural multidetector CT and classified into cement leakage into adjacent disk and outside disk. Cement leakage into adjacent disk and outside disk was found in 33 of 59 and 16 of 59, respectively.

Percutaneous vertebroplasty procedure was performed in a conventional manner using a biplane angiography unit under local anesthesia and conscious sedation. The patient was placed in a prone position on an angiography table with sterile conditions. After a small skin incision was made, a disposable 11- or 13-gauge bone biopsy needle (Cook, Bloomington, Ind) was positioned with its tip near the center of the pedicle. Anteroposterior and lateral fluoroscopy was used to advance the needle through the pedicle into the vertebral body. PMMA was prepared by combining sterile barium and cranio-plastic cement (Codman Cranioplastic; Johnson & Johnson Medical, Berkshire, United Kingdom). Injection of PMMA was performed either manually or with an injection device.

PaO_2 was measured by a conventional blood gas analyzer (ABL700; Radiometer Medical, Copenhagen, Denmark). Arterial blood drawing was taken from the radial or femoral artery with the patient in a supine position. We measured preprocedural PaO_2 5 days to 30 minutes before percutaneous vertebroplasty and postprocedural PaO_2 30 minutes after percutaneous vertebroplasty.

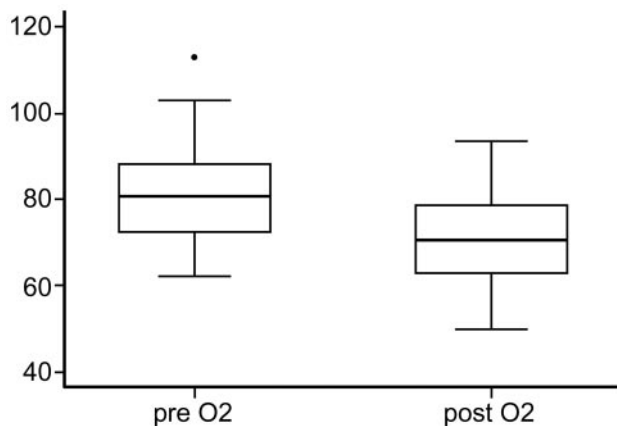
For statistical analysis, paired t test was used to examine the difference between preprocedural and postprocedural PaO_2 . Analysis of variance followed by t test was used to examine the difference in PaO_2 according to the number of treated vertebral bodies. Nonparametric trend test was used to estimate the trend of difference in PaO_2 depending on the number of treated vertebral bodies. Multiple linear regression technique was used to examine the correlation between the difference in PaO_2 and the following factors: patients' age, sex, number of treated vertebral bodies, presence of cement leakage, and presence of malignant diseases (adjusted by preprocedural PaO_2).

Received February 18, 2006; accepted after revision May 23.

From the Departments of Radiology (A.U., Y.N., M.M., N.K., Y.S.) and Clinical Practice Evaluation and Research (M.R.), St. Luke's International Hospital, Tokyo, Japan.

Paper previously presented at: Annual Meeting of the American Society of Neuroradiology; May 21–27, 2005; Toronto, Ontario, Canada.

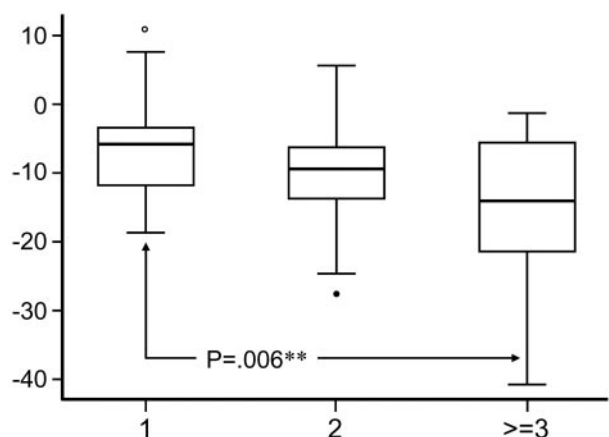
Address correspondence to Akihiro Uemura, MD, Department of Radiology, St. Luke's International Hospital, Akashi-cho 9-1, Chuo-ku, Tokyo, 104-8560 Japan; e-mail: akuemura@luke.or.jp



Mean: Pre PaO₂ 80.9 ± 1.4*mmHg → Post PaO₂ 70.6 ± 1.3*mmHg
 Difference: 10.27 (95% CI 7.81-12.72) [P=.0001]**

* standard error
 ** Paired t-test

Fig 1. The difference between preprocedural and postprocedural PaO₂.



*Non-parametric trend test
 **ANOVA followed by t-test

P=.018 with ANOVA
 P=.006 between 1 and ≥3
 P=.144 between 2 and ≥3
 P=.158 between 1 and 2
 P=.015 for test for trend*

Fig 2. Difference in PaO₂ before and after the procedure depending on the number of treated vertebral bodies.

Results

Mean (± SE) preprocedural and postprocedural PaO₂ values were 80.9 ± 1.4 and 70.6 ± 1.3 mm Hg, respectively. The difference between mean preprocedural and postprocedural PaO₂ was 10.3 mm Hg and was highly significant at $P < .0001$ levels (Fig 1). Difference in PaO₂ between preprocedure and postprocedure, depending on the number of treated vertebral bodies, is shown in Fig 2. Using analysis of variance, there was a significant difference according to the number of vertebral bodies. We found significant difference between the patients who had 1 and ≥3 vertebral bodies during percutaneous vertebroplasty ($P = .006$), though there was no significance between 1 and 2 ($P = .158$), or 2 and ≥3 ($P = .144$). Using a test for trend, there was a positive trend of decrease in PaO₂ according to the number of vertebral bodies during percutane-

Table 1: Results of multiple regression: model 1

	Coefficient	95% CI	P
Age	-0.36	-0.27-0.34	.816
Sex	-0.22	-0.27-3.42	.936
Number of vertebral bodies	3.41	0.81-6.00	.011
Cement leakage into adjacent disk	-0.86	-5.12-3.39	.685
Cement leakage except disk	1.52	-3.59-6.64	.553
Presence of malignancy	-3.91	-12.92-5.10	.388

Note:—CI indicates confidence interval. Dependent variables were difference between preprocedural and postprocedural PaO₂. Independent variables were age, sex, number of vertebral bodies, presence of cement leakage, and malignancy. Adjusted r^2 , 0.296.

Table 2: Results of multiple regression: model 2

	Coefficient	95% CI	P
Preprocedural PaO ₂	0.42	0.23-0.62	.000
Number of vertebral bodies	3.54	1.09-6.00	.005

Note:—CI indicates confidence interval. Independent variables were preprocedural PaO₂ and number of vertebral bodies. Adjusted r^2 , 0.336.

ous vertebroplasty ($P = .015$). We confirmed our finding of bivariate analysis by using multivariate technique (Table 1). We used multiple linear regression, and after adjusting by preprocedural PaO₂ and other variables, the number of vertebral bodies was still highly significant ($P = .011$) for the decrease in PaO₂. This was confirmed with a high level of confidence using the multiple regression model with independent variables: preprocedural PaO₂ and number of vertebral bodies (R^2 value 0.336 versus 0.296, $P = .005$) (Table 2).

Discussion

Percutaneous vertebroplasty was first described in France in 1987.³ The potential risk of cardiopulmonary changes during percutaneous vertebroplasty is of interest because percutaneous vertebroplasty is now widely used for the standard treatment of osteoporotic fractures and metastatic tumors of the vertebral bodies. We found a decrease in PaO₂ after percutaneous vertebroplasty, but the cause of the decrease remains unclear.

According to the US Food and Drug Administration (FDA) Center for Devices and Radiologic Health, through the on-line data base (<http://www.fda.gov/cdrh/maude.html>) for adverse event reporting, 19 complications associated with percutaneous vertebroplasty were reported, including 7 deaths and 4 cardiovascular events. Of the 7 patients who died, 4 underwent percutaneous vertebroplasty with lateral approach and 3 with transpedicular approach.⁴ Two had undergone multilevel vertebroplasty (8 in one case and 10 in the other) and experienced cardiovascular collapse, and 1 had a presumed anaphylactic reaction to bone cement, resulting in cardiac and/or respiratory arrest and death. In addition, of 4 patients who survived, 2 experienced diminished blood pressure and 2 had cardiac arrest. Pulmonary collapse during percutaneous vertebroplasty, including pulmonary embolism and acute respiratory distress syndrome, is a major concern, and symptomatic or asymptomatic pulmonary emboli associated with percutaneous vertebroplasty were reported.⁵⁻¹⁰ Although the overall number of such cases is small, the cardiopulmonary complications can be fatal.

There have been a few reports describing oxygen desaturation during conscious sedation.¹¹⁻¹³ Sedative drugs are known

to decrease respiratory function, and there is a report that myocardial ischemia occurred with the use of sedative drugs.¹⁴ In most cases of percutaneous vertebroplasty, sedative drugs are prescribed preoperatively and can affect oxygenation during percutaneous vertebroplasty. Furthermore, functional residual capacity may decrease during percutaneous vertebroplasty as a result of thoracic compression attributable to the prone position, which may be an important factor of deoxygenation. Patients who received supplemental oxygen during procedure were not included in this study. However, the use of supplemental oxygen during the procedure might avoid decrease in PaO₂.

Another cause of postprocedural decrease in PaO₂ may be pulmonary embolism. The source of emboli could be fragments of fatty bone marrow, which are created by increased intramedullary pressure during injection of PMMA or may be particles of PMMA themselves.⁵⁻⁷

Several reasons why the number of treated vertebral bodies affects postprocedural decrease in PaO₂ can be speculated upon. The reasons include increase in duration of percutaneous vertebroplasty procedure in prone position, increase in unpolymerized liquid monomer, cement volume, and possibly fragments of bone marrow. The consecutive augmentation of multilevel vertebral bodies with PMMA may induce a cumulative pulmonary embolism that deteriorates baseline PaO₂. Increase in number of needles, causing breath-holding due to procedural pain, could be another contributing factor. Another reason that multilevel vertebroplasty may correlate with decrease in PaO₂ is that perhaps more sedation was used. However, the pathophysiology for the PaO₂ decrease seems to be multifactorial.

The limitations of this study may be lack of sequential evaluation of PaO₂ after percutaneous vertebroplasty. Continuous intra-arterial blood gas monitoring during percutaneous vertebroplasty would be ideal. Although pulse oximetry is convenient to assess the oxygenation, blood gas analysis is more sensitive to oxygenation compared with pulse oximetry.

Our methodology has no power to suggest that PMMA injection has any effect on PaO₂ beyond the effects of prone positioning and moderate sedation, which plausibly may contribute to decreased PaO₂. Moreover, no data were collected to

show that the decrease in PaO₂ was sustained more than 30 minutes beyond the procedure.

Conclusion

PaO₂ decreases during percutaneous vertebroplasty, and there is a correlation between the number of treated vertebral bodies and a decrease in PaO₂. However, the pathophysiology of the decrease in PaO₂ is not clear and may be related to sedation, the patients' prone position, and/or pulmonary embolism. Physicians should be aware of the potential for a drop in PaO₂ with percutaneous vertebroplasty.

References

1. Vasconcelos C, Gailloud P, Martin JB, et al. **Transient arterial hypotension induced by polymethylmethacrylate injection during percutaneous vertebroplasty.** *J Vasc Interv Radiol* 2001;12:1001-02
2. Kaufmann TJ, Jensen ME, Ford G, et al. **Cardiovascular effects of polymethylmethacrylate use in percutaneous vertebroplasty.** *AJNR Am J Neuroradiol* 2002;23:601-04
3. Galibert P, Deramond H, Rosat P, et al. **Note preliminaire sur le traitement des angiomes vertebraux par vertebroplastie acrylique percutanee.** *Neurochirurgie* 1987;23:166-68
4. Nussbaum DA, Gailloud P, Murphy KA. **Review of complications associated with vertebroplasty and kyphoplasty as reported to the Food and Drug Administration medical device related web site.** *J Vasc Interv Radiol* 2004;15:1185-92
5. Aebli N, Krebs J, Davis G, et al. **Fat embolism and acute hypotension during vertebroplasty: an experimental study in sheep.** *Spine* 2002;27:460-66
6. Syed MI, Jan S, Patel NA, et al. **Fatal fat embolism after vertebroplasty: identification of the high-risk patient.** *AJNR Am J Neuroradiol* 2006;34:343-45
7. Padovani B, Kasriel O, Brunner P, et al. **Pulmonary embolism caused by acrylic cement: a rare complication of percutaneous vertebroplasty.** *AJNR Am J Neuroradiol* 1999;20:375-77
8. Stricker K, Orler R, Yen K, et al. **Severe hypercapnia due to pulmonary embolism of polymethylmethacrylate during vertebroplasty.** *Anesth Analg* 2004;98:1184-86
9. Jang JS, Lee SH, Jung SK. **Pulmonary embolism of polymethylmethacrylate after percutaneous vertebroplasty: a report of three cases.** *Spine* 2002;27:E416-18
10. Yoo KY, Jeong SW, Yoon W, et al. **Acute respiratory distress syndrome associated with pulmonary cement embolism following percutaneous vertebroplasty with polymethylmethacrylate.** *Spine* 2004;29:E294-97
11. Holm C, Christensen M, Schulze S, et al. **Effect of oxygen on tachycardia and arterial oxygen saturation during colonoscopy.** *Eur J Surg* 1999;165:755-58
12. Yano H, Iishi H, Tatsuta M, et al. **Oxygen desaturation during sedation for colonoscopy in elderly patients.** *Hepatogastroenterology* 1998;45:2138-41
13. O'Connor KW, Jones S. **Oxygen desaturation is common and clinically underappreciated during elective endoscopic procedures.** *Gastrointest Endosc* 1990;36:S2-S4
14. Holm C, Christensen M, Rasmussen V, et al. **Hypoxaemia and myocardial ischaemia during colonoscopy.** *Scand J Gastroenterol* 1998;33:769-72