

# Lower Cervical Nerve Root Block Using CT Fluoroscopy in Patients with Large Body Habitus: Another Benefit of the Swimmer's Position

## TECHNICAL NOTE

W.S. Bartynski  
D.S. Whitt  
M.A. Sheetz  
R.B. Jennings  
W.E. Rothfus

**SUMMARY:** We describe a method of performing lower cervical nerve root block (CNRB) with CT fluoroscopy in patients with large body habitus using the swimmer's position. This approach reduces image noise with acceptable visualization of vital structures and improved foraminal/root access. Anticipated use of the swimmer's position coupled with minimally modified radiation exposure parameters can limit radiation dose to operator/patient and reduce procedure time to match that of CNRB using CT fluoroscopy in typical patients.

Cervical nerve root block/steroid injection (CNRB) is commonly performed with CT or CT fluoroscopy (CTF).<sup>1-3</sup> This procedure can be challenging, in particular at lower cervical levels and in patients with a large body habitus (LBH) because of compromised image quality or limited trajectory options for foramen access because of the clavicle or shoulder. Poor visualization of critical structures, including the carotid artery, jugular vein, vertebral artery, and neural foramen, can occur.

The swimmer's position is traditionally used at the cervicothoracic junction in radiography/fluoroscopy and was recently advocated in the lower cervical spine for diagnostic CT.<sup>4</sup> We encountered several patients with LBH and lower cervical radiculopathy in which we modified our standard CNRB technique using a swimmer's position for improved visualization and access to the lower cervical foramina.

We describe our experience with this technique modification along with CT phantom assessment of operator/patient radiation exposure when performing CNRB with CT fluoroscopy, in particular at higher CTF dose levels.

### Technique

CNRB was requested in 9 patients (6 male, 3 female) with LBH and lower cervical radiculopathy (single root: 7; 2 roots: 2; C6: 5, C7: 5, C8: 1). Supine scout CT (120 kVp, 250 ± 50 mA, 20–25 cm FOV, 3-mm section thickness) was performed for level confirmation, foramen location, and trajectory determination, which demonstrated extensive beam-hardening artifacts obscuring the overlying vessels and target foramen. This suggested an unacceptable compromise in visualization by standard CTF, theoretically forcing higher exposure parameters.

As an alternative, patients were placed in the swimmer's position and scout CT was repeated. Critical blood vessels and the target foramen/root were more clearly identified and target access options improved (Fig 1). CNRB was performed in the swimmer's position using CTF and a 25-gauge spinal needle. Standard CTF spot images (range used in patients: 120–40 kVp, 50–100 mA, 20–25 cm FOV, 3-mm section thickness) were used to establish needle entry point and needle tip depth as it approached the target foramen/root. Vertebral tilt

induced by the swimmer's position resulted in foramen obliquity, but the needle could easily be followed as it entered the foramen and approached the root (Fig 1G, -H). Safe needle tip location was confirmed by local contrast accumulation adjacent to the nerve root (0.2–0.3 mL of iohexol, 180 mg of I/mm<sup>3</sup>; GE Medical Products, Milwaukee, Wis) by CTF. Methylprednisolone acetate 80 mg and bupivacaine 0.25% (2 mL for single root; 3 mL for double root, dose divided) were injected with intermittent CTF visualization of appropriate dilution of the test contrast pocket.

### Radiation Exposure with CTF

Theoretical operator/patient radiation exposure during CNRB by CTF was assessed using 2 cylindrical lucite CT phantoms (16 cm diameter [standard neck simulation], 32 cm diameter [swimmer's position simulation]). Deep patient exposure was evaluated in continuous mode with a phantom center location pencil CT ion chamber and electrometer (Radcal, Monrovia, Calif). Operator exposure was measured at 0.6 and 1.0 m in left/right lateral and center table positions during continuous mode using a micro-R ion chamber survey meter (Inovision, Cleveland, Ohio) and averaged using: 120/140 kVp and 50/100 mA with 20–25 cm FOV and 3-mm section thickness.

### Results

#### CNRB with Swimmer's Position

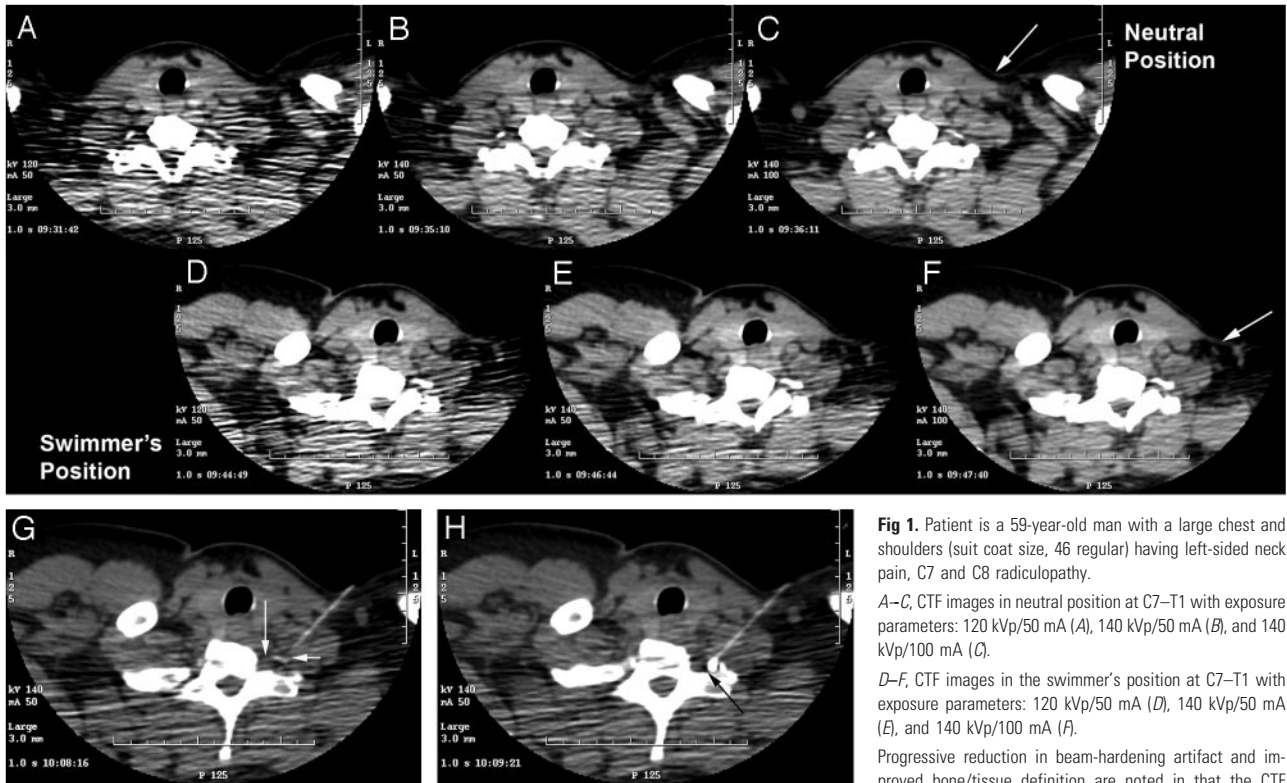
All CNRBs were successful and no complications were encountered. Adequate visualization of critical structures was obtained with CTF in the swimmer's position using only minor modification of standard milliamperage (mA) and kilovoltage (kVp) settings because of decreased tissue mass in the CT beam. Low shoulder position increased foraminal access options that avoided the carotid artery and jugular vein (Fig 1F). CTF allowed rapid access to the neural foramen even in those patients with LBH, resulting in short CNRB procedure time. Cumulative CTF time was approximately 15–20 seconds per treated level, and technical procedure time paralleled typical CNRBs performed in the standard neutral position.

Bone/tissue clarity increased with CTF exposure in both neutral and swimmer's position (Fig 1A–F). Visualization at 140 kVp/100 mA was superior (Fig 1F) but not considered routinely necessary to identify and avoid problem structures. Image quality appeared acceptable, and artifacts were equivalent between the neutral position 140-kVp/100-mA and the swimmer's position 140-kVp/50-mA exposures (Fig 1C, -E). Moderate artifacts were still present in the neutral position at 140 kVp/50 mA (Fig 1B).

Received June 2, 2006; accepted after revision October 17.

From the Department of Radiology (W.S.B., R.B.J., W.E.R.), Division of Neuroradiology, University of Pittsburgh, Presbyterian University Hospital, Pittsburgh, Pa; and Radiation Safety Office (D.S.W., M.A.S.), University of Pittsburgh, Pittsburgh, Pa.

Address correspondence to Walter S. Bartynski, M.D., Department of Radiology, Division of Neuroradiology, University of Pittsburgh, Presbyterian University Hospital, 200 Lothrop St, D132, Pittsburgh, PA 15213; e-mail: bartynskiws@upmc.edu.



**Fig 1.** Patient is a 59-year-old man with a large chest and shoulders (suit coat size, 46 regular) having left-sided neck pain, C7 and C8 radiculopathy.

A–C, CTF images in neutral position at C7–T1 with exposure parameters: 120 kVp/50 mA (A), 140 kVp/50 mA (B), and 140 kVp/100 mA (C).

D–F, CTF images in the swimmer's position at C7–T1 with exposure parameters: 120 kVp/50 mA (D), 140 kVp/50 mA (E), and 140 kVp/100 mA (F).

Progressive reduction in beam-hardening artifact and improved bone/tissue definition are noted in that the CTF

exposure parameters in both neutral position (A–C) and swimmer's position (D–F) are increased. Reduced beam-hardening artifact and improved bone/tissue definition are present in the swimmer's position (D–F) compared with the neutral position (A–C) at the same kilovolt-pascal/milliampere exposure settings. The swimmer's position offers a greater range of approach options to the left C7–T1 foramen (F, arrow) compared with limitations presented in the neutral position (C, arrow) because of the proximity of the clavicle, lateral chest wall, and shoulder.

G, swimmer's position induces vertebral body and foramen tilt, altering visible appearance of the needle approach. The needle is seen approaching the inferior margin of the C7 transverse process tubercle and roof of the C7–T1 foramen (short arrow). C8 nerve root is seen exiting medially and inferiorly to the foramen roof (long arrow).

H, Successful C8 CNRB performed at C7–T1 (arrow) with contrast seen adjacent to the C8 root. Patient's symptoms completely resolved with the C7 and C8 injections.

#### Radiation exposure

Phantom	kVp	mA	Center Dose (mRem/min)	Operator Dose (mRem/min)	
				0.6 m	1.0 m
16 cm	120	50	3620	2.8	1
	120	100	6950		2
	140	50	4370		1.5
32 cm	120	50	1070	3.2	1.4
	120	100	2120		2.5
	140	50	1610		2
	140	100	3290		3.8

#### Radiation Exposure at CTF

Patient/operator exposure (Table) increased linearly with increasing milliamperes. Operator exposure was significantly greater at close (0.6 m) compared with routine exposure distance (1.0 m). Operator/patient exposure with the 32 cm phantom at 1 m was lower with 140 kVp/50 mA than with 140 kVp/100 mA or 120 kVp/100 mA.

#### Discussion

Patients with large upper body habitus are challenging to image at the cervicothoracic junction. CNRB is difficult in this region because it is crucial to identify and avoid such vital structures as the carotid artery, jugular vein, and vertebral artery.

The swimmer's position, similar to the lateral decubitus position,<sup>5</sup> can be effectively used in performing CNRB in patients with LBH with adequate structure visualization and

standard root access and CTF times. Even with the swimmer's position, an increase in CTF dose is generally required for adequate structure visualization. Beam-hardening artifacts were severe in the neutral position and remained compromised in the swimmer's position at 120 kVp/50 mA (Fig 1A, -D). Surprisingly, image quality was similar between the 140 kVp/50 mA swimmer's position (Fig 1E) and 140 kVp/100 mA neutral position (Fig 1C) exposures, despite the lower dose at 140 kVp/50 mA. Visualization was markedly improved at 140 kVp/100 mA (Fig 1F) but not necessary to identify and avoid crucial structures. The operator can therefore assess/modify the available parameters, if necessary, and limit exposure. Radiation exposure studies have assessed CTF doses ranging from 10 to 100 mA at 120–140 kVp.<sup>6</sup> In our practice, 120 kVp and 40–60 mA is standard for most uncomplicated CNRB procedures.

CNRB can also be performed with traditional fluoroscopic

guidance.<sup>7-10</sup> Advocates prefer this technique because of the continuous visualization of the steroid/contrast mixture during injection for detection of intravascular migration.<sup>11-13</sup> With confirmation of needle tip position using anteroposterior, oblique, and lateral fluoroscopic images, a similar limitation can occur at the cervicothoracic junction in patients with LBH, particularly in the lateral and oblique positions.<sup>7-10</sup> In addition, the fluoroscopic approach does not allow direct visualization or avoidance of the carotid artery, jugular vein, or vertebral artery and may present alternative limitations and risks.

### Conclusion

CNRBs at low cervical levels can be successfully performed by CT fluoroscopy in patients with LBH using the swimmer's position to reduce scanned tissue mass and improve trajectory options. CTF parameters can be chosen to limit patient/operator exposure even in these challenging lower cervical locations.

### Acknowledgement

The authors would like to thank Eric Jablonowski for his assistance in image preparation.

### References

1. Kapoor V, Rothfus WE, Grahovac SZ, et al. **Refractory occipital neuralgia: preoperative assessment with CT-guided nerve block prior to dorsal cervical rhizotomy.** *AJNR Am J Neuroradiol* 2003;24:2105-10
2. Cyteval C, Thomas E, Decoux E, et al. **Cervical radiculopathy: open study on percutaneous periradicular foraminal steroid infiltration performed under CT control in 30 patients.** *AJNR Am J Neuroradiol* 2004;25:441-45
3. Wagner AL. **CT fluoroscopic-guided cervical nerve root blocks.** *AJNR Am J Neuroradiol* 2005;26:43-44
4. Kane AG, Reilly KC, Murphy TF. **Swimmer's CT: improved imaging of the lower neck and thoracic inlet.** *AJNR Am J Neuroradiol* 2004;25:859-62
5. Fenton DS, Czervionke LF. **Selective nerve root block.** In: Fenton DS, Czervionke LF, eds. *Image-Guided Spine Intervention*. Philadelphia: Saunders; 2003:73-98
6. Paulson EK, Sheafor DH, Enterline DS, et al. **CT fluoroscopy-guided interventional procedures: techniques and radiation dose to radiologists.** *Radiology* 2001;220:161-67
7. Morvan G, Monpoint D, Bard M, Levi-Valensin G. **Direct intra-foraminal injection of corticosteroids in the treatment of cervico-brachial pain.** In: Bard M, Laredo JD, eds. *Interventional Radiology in Bone and Joint*. New York: Springer-Verlag; 1988:253-57
8. Bush K, Hiller S. **Outcome of cervical radiculopathy treated with periradicular/epidural corticosteroid injections: a prospective study with independent clinical review.** *Eur Spine J* 1996;5:319-25
9. Slipman CW, Lipetz JS, Jackson HB, et al. **Therapeutic selective nerve root block in the nonsurgical treatment of atraumatic cervical spondylotic radicular pain: a retrospective analysis with independent clinical review.** *Arch Phys Med Rehabil* 2000;81:741-46
10. Vallee JN, Feydy A, Carlier RY, et al. **Chronic cervical radiculopathy: lateral approach periradicular corticosteroid injection.** *Radiology* 2001;218:886-92
11. Brouwers PJAM, Kottink EJBL, Simon MAM, et al. **A cervical anterior spinal artery syndrome after diagnostic blockade of the right C6-nerve root.** *Pain* 2001;91:397-99
12. Baker R, Dreyfuss P, Mercer S, et al. **Cervical transforaminal injection of corticosteroids into a radicular artery: a possible mechanism for spinal cord injury.** *Pain* 2003;103:211-15
13. Furman MB, Giovanniello MT, O'Brien EM. **Incidence of intravascular penetration in transforaminal cervical epidural steroid injections.** *Spine* 2003;28:21-25