AJNR

Whole-Body CT Trauma Imaging with Adapted and Optimized CT Angiography of the Craniocervical Vessels: Do We Need an Extra Screening Examination?

S. Langner, S. Fleck, M. Kirsch, M. Petrik and N. Hosten

AJNR Am J Neuroradiol 2008, 29 (10) 1902-1907
doi: https://doi.org/10.3174/ajnr.A1261
http://www.ajnr.org/content/29/10/1902

ORIGINAL RESEARCH

Whole-Body CT Trauma Imaging with Adapted and Optimized CT Angiography of the Craniocervical Vessels: Do We Need an Extra Screening Examination?

S. Langner
S. Fleck
M. Kirsch
M. Petrik
N. Hosten

BACKGROUND AND PURPOSE: Blunt carotid and vertebral artery injury (BCVI) is rare but potentially devastating. The objective of our study was to prospectively evaluate the usefulness of a dedicated and optimized CT angiography (CTA) protocol of the craniocervical vessels as part of a whole-body CT work-up of patients with multiple trauma in a population of patients with blunt trauma.

MATERIAL AND METHODS: From February 2006 to July 2007, a total of 368 consecutive patients with trauma were evaluated. All examinations were performed on a 16-row multisection CT (MSCT) scanner. CTA was performed from the level of the T2 vertebra to the roof of the lateral ventricles with 40 mL of iodinated contrast agent. Images were reconstructed with use of the angiography and bone window settings to evaluate vessels and bones.

RESULTS: Of all eligible patients imaged, 100 had injuries to the head and neck including 35 skull base fractures (9.5%), 24 maxillofacial (6.5%), and 11 cervical spine fractures (3%). CTA was diagnostic in all patients. BCVI was diagnosed in 6 cases (6 lesions of the internal carotid artery, 3 lesions of the vertebral artery); among them were 2 who did not meet the screening criteria. No patient with negative results on CTA subsequently had development of neurologic deficits suspicious for BCVI.

CONCLUSION: This study confirms that optimized craniocervical CTA can be easily integrated into a whole-body CT protocol for patients with multiple trauma. No additional screening technique is necessary to identify clinically relevant vascular injuries. Earlier recognition enables earlier treatment and may decrease mortality and morbidity rates of these rare but potentially devastating injuries.

Blunt carotid and vertebral artery injury (BCVI) is a rare event. The diagnosis is quite challenging because of the relatively low incidence of BCVI and delayed onset of clinical manifestations.[1,2] Although early series reported an incidence of carotid dissections of less than 0.1% of patients with blunt trauma,[3,4] recent studies have found BCVI in up to 1.6% of patients admitted for trauma.[5-8] In the light of the potential devastating consequences of BCVI, much effort has focused on improving detection and treatment during the past decade.[9,10] Initially, neurologic deficits were thought to be inevitable in these patients, but prompt systemic anticoagulation before the onset of stroke has significantly reduced ischemic neurologic events in such patients.[8,11] On the basis of these insights and increased awareness of BCVI, subsequent efforts have been directed toward the identification of injuries before the onset of stroke, resulting in screening protocols[7,12,13] according to mechanism of injury and specific injury patterns[9,10,14,15] (Table 1). Although screening criteria have been refined with time, there is still no generally accepted set of criteria used by all centers. Moreover, there is also no general consensus whether a liberalized screening protocol is justified[6,16] and of how to screen patients at risk.[1]

Noninvasive imaging techniques have markedly improved in recent years and now offer clear advantages over established diagnostic procedures (eg, intra-arterial conventional angiography). An initially silent condition such as BCVI should ideally be identified with a diagnostic test that is easy to perform, is readily available, and has a low complication rate. Intra-arterial digital subtraction angiography (IA-DSA) produces highly accurate images, but it is a time-consuming and expensive examination that requires highly trained and specialized personnel. It also comes with a small risk for severe complications such as catheter-associated cerebrovascular accidents or anaphylaxis from the contrast medium.[14] Therefore, the status of IA-DSA as the screening method of choice has been challenged in recent years.

CT angiography (CTA) has become an increasingly available tool in the emergency department. Early studies found CTA to be unreliable to detect BCVI because of low sensitivity.[5,10,14] However, with advanced CTA technology, there is increasing enthusiasm about CTA and its potential to become the main diagnostic technique to detect BCVI.[9,17-20] The advantage of CTA is that it can be easily integrated into existing protocols for CT work-up of patients with multiple trauma who already undergo CT for other reasons. However, in most studies, patients with trauma often undergo both body trauma imaging and CTA but as separate studies. This increases scan time and overall examination time, especially when the head and cervical spine have to be reviewed for risk factors. Nevertheless, the CT protocol for patients with multiple trauma is still subject to debate.

It is still unclear whether the absence of clinical predictors is helpful to exclude BCVI. The aim of our study was twofold. First, the benefit of a dedicated and optimized CTA protocol

Received May 8, 2008; accepted after revision June 26.

From the Institute for Diagnostic Radiology and Neuroradiology (S.L., M.K., M.P., N.H.) and Department of Neurosurgery (S.F.), Ernst-Moritz-Arndt-University Greifswald, Greifswald, Germany.

Please address correspondence to Soenke Langner, MD, Department of Radiology and Neuroradiology, Ernst-Moritz-Arndt-University Greifswald, Ferdinand-Sauerbruch-Str. 1, 17475 Greifswald, Germany; e-mail: langso@uni-greifswald.de

DOI 10.3174/ajnr.A1261

Table 1. Findings that are suspicious for BCVI and should trigger screening

Cervical spine fractures with C1-C3 vertebral fracture
Extension into transverse foramen or lateral elements of vertebra
Luxation/subluxation or distraction mechanism
Closed head injury with diffuse axonal injury
Neurologic examinations incongruent with brain imaging
Stroke or transient ischemic attack
Horner syndrome
Basilar skull fracture with involvement of carotid canal, foramen lacerum
Severe maxillofacial fracture
Carotid or vertebral artery perivascular hematoma
Neck soft tissue injury (eg, seatbelt injury or hanging)

Note:—BCVI indicates blunt carotid and vertebral artery injury.
From Utter et al[9], Cothren et al[10], Miller et al[14], and Sliker et al[15].

for head and neck vessels performed as part of whole-body CT work-up of patients with multiple trauma was prospectively evaluated in a population of patients with blunt trauma. In addition, the incidence of BCVI was determined in this population.

Materials and Methods

Our hospital fulfills level I accreditation criteria as required by the Trauma Committee of the American College of Surgeons. CT has become the main imaging technique in the management of patients with multiple trauma. The radiology department provides a 24-hour in-house service. The radiologist on call performs all imaging procedures in real time. Conflicting diagnoses by the radiologist and surgeon are resolved by consensus, taking into account both clinical symptoms and radiologic findings.

We obtained approval from our institutional review board before initiating the study.

From February 2006 to July 2007, we prospectively included 368 consecutive eligible patients who were admitted to our emergency department. These patients had sustained a high-velocity injury (eg, motor vehicle crash), a fall from a great height, or a trauma of unknown mechanism with clinical findings indicating relevant trauma (eg, pedestrian struck or skydiving accident). The diagnosis of multiple trauma was made in patients with an injury severity score of greater than 16 suspected by the emergency physician initially examining the patient in the trauma bay. This means that 1 or the combination of the suspected trauma sequelae was thought to be life threatening.[21] The indications for whole-body trauma CT were defined in advance by consensus between the department of radiology and the emergency department.

All examinations were performed on a 16-row multisection CT (MSCT) scanner (Somatom Sensation 16; Siemens Medical Systems, Erlangen, Germany). The patient was placed on the table with the arms under the back or on the abdomen if possible, otherwise aside. Initially, plain helical cranial CT was performed to exclude intracranial hemorrhage. Scanning parameters were 4.5-mm section thickness, 120 kV tube voltage, 360 mAs tube current, and a pitch of 1. Next, the CTA scan of the craniocervical vessels was acquired from the level of the T2 vertebra up to the roof of the lateral ventricles. Sections were reconstructed with a section thickness of 1 mm with use of an edge-enhancing bone algorithm for the spine and soft tissue algorithm for the vessels. The other scanning parameters were 100 kV tube voltage, 300 mAs tube current, collimation 16 × 0.75 mm, pitch 1.25, and a 25-cm FOV. We administered 40 mL of a nonionic iodine-containing contrast agent (Iodixanol, Visipaque; GE Healthcare Buchler, Braunschweig, Germany) using a power injector (MedRad Medical Systems, Volbach, Germany) at a flow rate of 4 mL/s followed by a saline flush of 40 mL at a flow rate of 4 mL/s after semiautomated bolus tracking in the common carotid artery at the level of the C6 vertebra with a threshold of 100 HU. The acquisition of the CTA dataset took 9.6 seconds. We created secondary multiplanar reconstructions (MPR) of the cervical spine in sagittal and curved coronal planes and of the skull base and midface in 2-mm axial sections and in sagittal and coronal planes using the images reconstructed with the bone algorithm. The axial source images of the craniocervical vessels were reformatted as 2-mm axial thin-section maximum intensity projections (MIP). Additional advanced postprocessing techniques (eg, thick slab MIP, curved MPR, and volume rendering technique) were used for clinical demonstration.

Finally, we scanned the trunk from the upper thoracic aperture to the femoral lesser trochanter after administering a second bolus of 60 mL of contrast medium, with a flow rate of 4 mL/s followed by a saline flush of 40 mL with the same flow. Scanning started with a 20-second delay to achieve good contrast in the aorta. Scanning was performed with a tube voltage of 140kV to compensate for additional attenuation, especially of the shoulders. Collimation was 16 × 1.5 mm, and sections were reconstructed with 2-mm and 5-mm thickness. The protocol used CARE dose 4D automatic exposure control (Siemens Medical Systems) to optimize the tube current relative to body attenuation. We obtained MPR images of the thoracic and lumbar spine and the pelvis in the sagittal and coronal planes with a section thickness of 2 mm. The chest and abdomen were reconstructed in the coronal planes with a section thickness of 3 mm. In children, we used an adapted scanning and contrast medium protocol.

The images of the craniocervical vessels were reviewed by 2 experienced board-certified radiologists, of whom 1 was a board-certified neuroradiologist. Both readers had at least 7 years of experience in interpreting CT angiography and emergency department imaging. For image analysis, they used either the CT workstation (syngoCT 2007/s; Siemens Medical Systems) or a PACS workstation (Impax DS 3000; AGFA Healthcare, Mechelen, Belgium). Pathologic patterns suggesting BCVI were irregular vessel walls, tapering stenosis, occlusions, and dissected arterial walls or bulges of the vessel wall indicating pseudoaneurysm. Patients in whom CTA detected BCVI received heparin or warfarin for anticoagulation at the discretion of the emergency team and in accordance with the overall treatment regimen.

The length of the hospital stay until discharge was registered for all patients. At the end of the study, all examinations were reviewed again for missed cervical spine or maxillofacial fractures.

We performed all statistical analyses using Version 14 of the Statistical Package for the Social Sciences (SPSS, Chicago, Ill). Sensitivity and specificity for the CTA as well as positive and negative predictive values were calculated.

Results

From February 2006 to July 2007, we prospectively included 368 consecutive patients. There were 251 male patients and 117 female patients. Mean age was 40.78 years. Mechanisms of injury included motor vehicle (n = 174 [47.28%]) or motorcycle crash (n = 34 [9.24%]), bicycle accident (n = 21 [5.71%]), fall from great height (n = 84 [22.83%]), and pedestrian struck (n = 6 [1.63%]). In 14 (3.8%) cases, the trauma mechanism was unknown. The remaining patients (n = 35 [9.51%]) had a combination of less common mechanisms (eg, skydiving accident, assault, struck by cow). There

Table 2. Summary of mechanisms of injury, trauma sequelae, and associated vascular lesions in the 6 patients with BCVI

Mechanism	Injury	Vascular Lesion	Neurologic Symptoms
Fall from ladder	Fracture of articular process of C6	Dissection of vertebral artery	+
Bicycle vs truck	Basilar skull fracture	Carotid cavernosus fistula, dissection of contralateral ICA	+
Motor vehicle crash	Luxation fracture of C4	Dissection of vertebral artery	+
Bicycle accident	Skull fracture, fracture of C4-C6	Dissection of both vertebral arteries	+
Motor vehicle crash	No fracture on CT	Unilateral ICA dissection	−
Motor vehicle crash	Concussion; no fracture	Bilateral ICA dissections	−

Note:—BCVI indicates blunt carotid and vertebral artery injury; ICA, internal carotid artery.

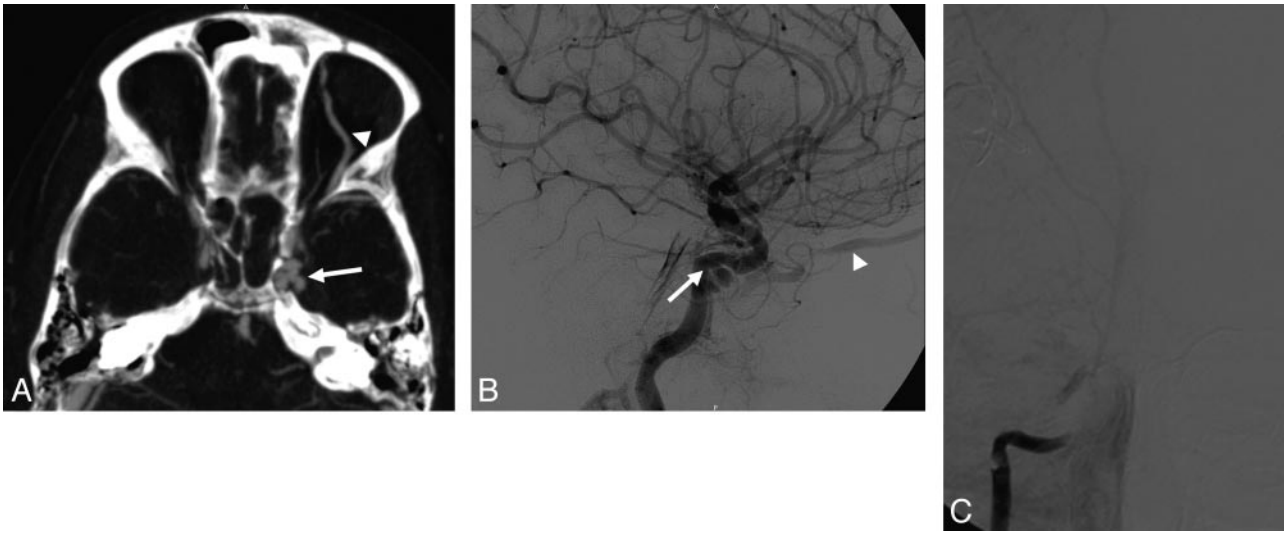

Fig 1. Findings in a young male patient with severe head injury and basilar skull fracture in a bicycle accident. The patient died of extensive cerebral infarction 2 days after the accident. *A,* direct carotid cavernosus fistula (*arrow*) of the left internal carotid artery with dilated superior ophthalmic vein (*arrowhead*). *B,* corresponding lateral angiogram; carotid cavernosus fistula (*closed arrow*) with dilated superior ophthalmic vein (*arrowhead*). *C,* angiogram of the right internal carotid artery, which is occluded by dissection.

were 100 (27.17%) patients who had head and neck injuries. Fractures of the cervical spine were present in 11 patients (3% of all admissions), fractures of the skull in 35 (9.51%) cases, and facial fractures in 24 (6.52%) cases. There were 8 (2.17%) patients who had a combined injury of the head and neck, and in 22 cases there was no bone damage despite intracranial trauma sequelae. Two patients were without evidence of significant head, facial, or neck trauma. Injuries of the trunk, extremities, or thoracic and lumbar spine were not monitored. No missed cervical spine fracture or maxillofacial fracture was identified clinically or on follow-up imaging. This was confirmed by the retrospective analysis of all examinations at the end of the trial.

In most of the patients, it was possible to place the arms under the back or on the abdomen during CT scanning. Therefore, despite a marginal deterioration in image quality, artifacts from the arms were not a diagnostic problem for the evaluation of the chest and upper abdomen. CTA was performed in all patients, and the craniocervical vessels were evaluable in all cases. The diagnosis of BCVI was made by CTA in 6 cases (1.63% of all admissions, 6% of patients with injury to head and neck). CTA revealed no equivocal findings. The diagnosis was confirmed in 2 cases by angiography and in 4 cases by duplex sonography. Three patients had injuries to more than 1 artery, with a total number of affected vessels of 9. Arterial dissection accounted for 8 (89%) of the injuries. Vascular injury led to stenosis or occlusion of the affected vessel in 5 (55.56%) instances, whereas no hemodynamic relevance of the injury was identified at the time of admission in 4 (44.44%) vessels. The internal carotid artery and the vertebral artery were equally affected in 3 cases, whereas there was bilateral involvement of the internal carotid artery in 2 patients and of the vertebral artery in 1 case (Table 2). There was a direct carotid cavernous fistula (Fig 1) in 1 case. Of the 2 patients without evidence of severe head and neck injury, the first had dissection of 1 internal carotid artery and the other had bilateral internal carotid dissection (Fig 2). In comparison with the clinical risk factors for BCVI,[9,10,14,15] sensitivity and specificity for CTA were 100% with a positive predictive value (PPV) of 1 and a negative predictive value (NPV) of 0.

All patients were managed nonoperatively with anticoagulation. Two patients died (0.54% of all admissions, 2% of BCVI), both from to massive cerebral infarction secondary to BCVI. No patients with negative results on CTA subsequently had development of signs or symptoms of BCVI during their hospital stay. The mean number of days in the hospital was 18.17 ± 5.71 days (range, 3–29 days).

Discussion

BCVI is an underdiagnosed injury in patients with multiple trauma. Often, BCVI goes unrecognized on admission because neurologic symptoms often occur late, with symptoms developing in most patients within 10 to 72 hours after the trauma.[7,10] It is frequently associated with other severe multiple organ injuries and is often not suspected after minor head and neck trauma.[18] Therefore, the diagnosis is often delayed until a severe neurologic deficit develops.[18] Recent studies suggest that BCVI is much more common than once be-

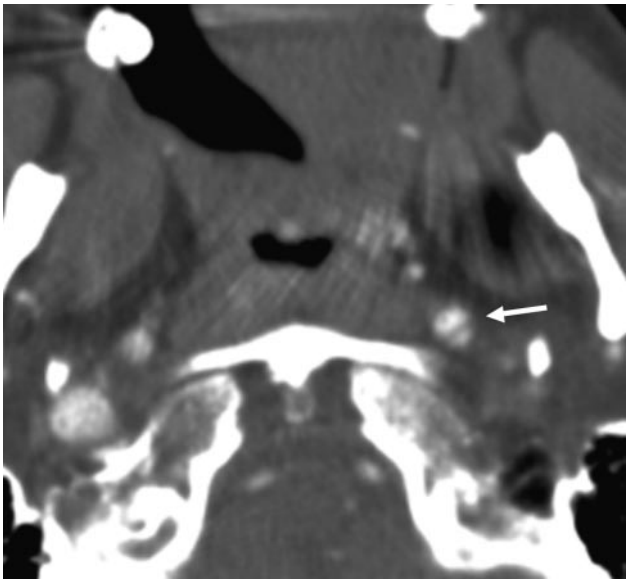

Fig 2. Axial source image of the CTA of a patient without clinical signs or symptoms of severe head or neck injury. Dissection of the left internal carotid artery (*intima flap indicated by white arrow*) with patency of both lumens.

lieved.[5-8,14] BCVI is associated with high mortality and morbidity rates, in part attributable to the severity of concomitant injuries. Nevertheless, BCVI-specific mortality by itself is also high. There is a reported stroke rate of up to 60% for BCVI.[22] Several investigators[23] believe that stroke from BCVI can be prevented by anticoagulation or surgery or endovascular intervention[5,6,14,24] if the vascular injury is detected early. Because of the devastating potential of BCVI, screening programs have been proposed for patients at risk.[6,8,14] These programs are based on the identification of particular patterns of injuries that are associated with BCVI.[6,14,25] Current algorithms include patients with specific symptoms or signs (Table 1) as well as those considered at high risk.[7,12] Although there is no consensus about the benefit of liberalized screening protocols,[6,16] it has been shown that the likelihood of vessel injury increases with the number of risk factors present.[26]

Noninvasive methods to diagnose BCVI have evolved during the last years.[9,10] Angiography is the generally accepted criterion standard for evaluation of the head and neck vessels when vascular injuries are suspected.[1] However, IA-DSA is resource intensive, not necessarily completely sensitive, and carries a small yet significant risk for neurologic morbidity. More recently, various improved noninvasive imaging techniques such as MR angiography,[27] duplex sonography (DUS), and CTA[28] have been studied for their potential role in the diagnosis of BCVI. MR imaging is at a disadvantage because of its limited availability in the acute trauma setting. There is also incompatibility with various medical devices and the need for MR-compatible monitoring equipment and ventilators. Other factors include the risks associated with scanning patients with certain indwelling devices or foreign bodies. Flow effects, artifacts, and limited spatial resolution compared with CTA may limit the sensitivity of MR angiography to detect clinically significant injuries. Therefore, its diagnostic accuracy has been debated, especially when time-of-flight techniques are used.[14,16] On the other hand, intramural hematoma can be clearly depicted by MR imaging, but because of the relatively long imaging times, it is very sensitive to the patient's motion. Only a few studies have discussed the sensitivity of DUS to detect BCVI and have shown disappointing results.[15] In a more recent study by Mutze et al,[21] DUS was found to have a sensitivity of only 38.5% for the detection of BCVI. DUS is highly operator dependent and has limited accuracy for lesions of the intracranial vessels and near the skull base, where injuries frequently occur.[1,26] Also, evaluation of the vertebral arteries within the cervical canal is limited by osseous structures.

Miller et al[14] conducted a prospective comparative study of screening modalities for BCVI. They found that CTA was unreliable to detect BCVI, with sensitivities between 50% and 68%. Biffl and coworkers[29] reported that CTA may miss discrete luminal irregularities of less than 25% of the vessel diameter, which they could only diagnose by conventional angiography.[29] These lesions are mostly injuries found by aggressive screening.[16,29] According to Biffl et al[29], these injuries carry a significant risk for stroke, and Cothren[10] considered the risk for angiography to be less than the risk for stroke from these lesions. However, it has also been shown that these vessel irregularities may not be injuries after all but related to the angiographic procedure and vasospasm, or they may heal spontaneously within 10 days regardless of treatment.[5] Therefore, many may find the potential complications of angiography unacceptable given the relatively low incidence of BCVI in the screening situation.

There are earlier studies in which single-detector helical CT was found to have high sensitivity and specificity to detect injuries to the major vessels of the head and neck in the setting of BCVI.[18] Advanced CT technology and developments in image reconstruction offer improved spatial resolution and faster scanning times. Unlike angiography, CTA can be performed within minutes of a patient's arrival. CTA requires the patient to remain motionless for 2 to 3 minutes only, which is much shorter than the long period required for angiography. In our study protocol, the scan time for CT angiography was 9.6 seconds. Furthermore, 3D volume rendering techniques can be used to generate images that are similar to conventional angiography and help in presenting the findings to the referring physician.[1] Therefore, some centers have adopted CTA as the initial test, followed by IA-DSA in patients with abnormal or equivocal CT findings.[1] Recent studies[9,17-20] underline the role of CTA as the main diagnostic technique for BCVI. CTA is superior to DUS in that it is operator independent, depicts vessels in the skull base and the intracranial vessels,[16] and allows evaluation of patients with difficult anatomy or neck hematomas that are not amenable to DUS.[28]

A dedicated CT protocol must represent the best compromise between examination speed, radiation dose and image quality. In all studies published so far,[9,17-21] CTA was performed as a second diagnostic test or as an additional examination in patients who underwent CT scanning for cranial or cervical trauma and met the screening criteria or were considered at high risk for BCVI. This increases both scan time and overall examination time, especially when the head and neck have to be reviewed for risk factors. It also increases patient exposure to radiation. In this study, we report our experience with the use of an optimized and dedicated CTA protocol for the vessels of the head and neck in the setting of whole-body

CT trauma work-up. CTA was performed in all patients, and the CTA data were reconstructed with use of a soft kernel to evaluate the vessels and a "bone" kernel to evaluate the cervical spine. That the use of CTA involves administration of a contrast medium and may be associated with adverse effects can be justified in this population because patients with multiple trauma undergo contrast-enhanced CT of the chest and abdomen as part of standard management. In contrast to the other studies, our patients were not exposed to additional radiation because CT of the midface, skull base, and cervical spine is part of our whole-body trauma protocol. In our study population, 4 patients (66% of all BCVI) met the screening criteria for BCVI; 3 of them had injuries to the vertebral arteries. One patient with a complex fracture of the skull base had a direct carotid cavernosus fistula on 1 side and dissection of the petrous segment of the internal carotid artery on the other side. It is worth noting that 2 patients with BCVI (33% of all BCVI) did not meet the screening criteria and had no physical signs or symptoms of trauma to the head and neck or symptoms of BCVI before CTA. One of these patients had bilateral dissection of the internal carotid artery and the other unilateral dissection. A similar observation was made in a recent study by Stein et al,[30] who found no major craniofacial or cervical spine injury in 27% of patients diagnosed with BCVI. Biffl[29] and coworkers reported approximately 20% of patients with BCVI with no recognized risk factors and initially occult injuries. These findings highlight the fact that even if a liberalized screening protocol on the basis of risk factors were instituted, delayed BCVI-related stroke could still occur because the published risk factors are not all-inclusive. The risk of overlooking BCVI is especially high in patients with trauma who are primarily ventilated with an unknown mechanism of injury and unknown neurologic status.

Blunt vertebral artery injury typically occurs in the V3 segment should craniocervical junction distraction or dislocation occur and less commonly in the foraminal segments (eg, V2). In this segment, the vertebral arteries are relatively protected in the transverse foramina but, on the other hand, they are susceptible to injuries induced by displaced bone fragments or stretching related to rotation or subluxation.[16] Blunt carotid injury typically affects the vessel just below the skull base. It is noteworthy that we found multiarterial injury in 66% of all cases. In the literature, more than 1 injured vessel in various combinations is reported for 18% to 38% of BCVI cases.[6,13,15]

In our study, no patients with a negative result on CTA developed evidence of BCVI during their hospital stay (mean, 18.17 $\pm$ 5.71 days). These data are supported by the work of Biffl et al[17] and Berne and coworkers.[31] Neither group reported delayed neurologic complications of BCVI in patients with normal results on CTA. The incidence of BCVI in our study is at the upper end of the range published in the literature.[5-8] This underlines the need for an optimized CTA protocol for the craniocervical vessels as part of the primary CT work-up of patients with multiple trauma. What remains open is whether patients with an early diagnosis of BCVI would have progressed to cerebral ischemia with or without therapy. Retrospective analysis after the end of the study revealed no missed nonvascular trauma findings such as fractures of the cervical spine or maxillofacial fractures.

Various attempts have been made to optimize parenchymal opacification.[32] It has been shown that injection protocols with more than 1 injection phase are superior to protocols with a single injection phase. In our experience, the early injection phase for the craniocervical vessels also contributes to the opacification of the visceral organs. The second phase allows simultaneous detection of vascular damage and visceral organ injury. This protocol reduces the incidence of equivocal findings from arm-related artifacts because hematomas within organs appear with a lower attenuation compared with the artifacts. This might be especially beneficial in patients with multiple trauma with circulatory instability in whom a single-phase injection protocol results in suboptimal opacification of the vessels and visceral organs.

There were a few limitations to this study that deserve mention. First, we did not conduct long-term follow-up of patients in whom BCVI-related symptoms did not develop during their hospital stay. Second, the patients who had a negative result on CTA were not subjected to DUS or a conventional angiogram on a regular basis. However, the aim of this study was not to calculate sensitivity and accuracy of CTA. It has been shown by Mutze et al[21] that a negative result on high-quality CTA of the craniocervical vessels is highly predictive of a benign clinical course. Third, the BCVI cohort consists of only 6 patients, which is a small number, but then the entity under investigation is uncommon; this limitation is also shared by other studies.[17,19,33] In comparison with the clinical risk factors, which were used by other authors[9,10,14,15] to identify patients who should undergo screening examinations, sensitivity and specificity for CTA were 100% with a PPV of 1 and a NPV of 0. Because the incidence of BCVI and of patients with multiple injured vessels is in the range reported by other authors, we believe that our data may reflect the true accuracy of 16-row MSCT angiography in screening a general blunt trauma population for BCVI. Sensitivity and specificity might be biased by the low incidence of BCVI, but comparable results have been reported by Miller and coworkers.[14] Therefore, we believe that an optimized and dedicated CTA of the craniocervical vessels integrated into a whole-body CT protocol for patients with trauma can be considered diagnostically equivalent to conventional angiography. The role of 64-row or greater MSCT for the detection of BCVI has to be evaluated, preferably in a prospective multicenter trial.

Conclusion

This study confirms that optimized craniocervical CTA can be easily integrated into a whole-body CT protocol for patients with multiple trauma. The incidence of BCVI with use of this protocol is at the upper end of the range published in the literature. No additional screening technique is necessary to identify clinically relevant vascular injuries. Earlier recognition enables earlier treatment and may decrease mortality and morbidity rates of these rare but potentially devastating injuries.

References

1. Nunez DB Jr, Berkmen T. **Imaging of blunt cerebrovascular injuries.** *Eur J Radiol* 2006;59:317–26
2. Rubio PA, Reul GJ Jr, Beall AC Jr, et al. **Acute carotid artery injury: 25 years' experience.** *J Trauma* 1974;14:967–73
3. Cogbill TH, Moore EE, Meissner M, et al. **The spectrum of blunt injury to the carotid artery: a multicenter perspective.** *J Trauma* 1994;37:473–79

4. Davis JW, Holbrook TL, Hoyt DB, et al. **Blunt carotid artery dissection: incidence, associated injuries, screening, and treatment.** *J Trauma* 1990;30:1514–17
5. Biffl WL, Ray CE Jr, Moore EE, et al. **Treatment-related outcomes from blunt cerebrovascular injuries: importance of routine follow-up arteriography.** *Ann Surg* 2002;235:699–706; discussion 706–07
6. Kerwin AJ, Bynoe RP, Murray J, et al. **Liberalized screening for blunt carotid and vertebral artery injuries is justified.** *J Trauma* 2001;51:308–14
7. Miller PR, Fabian TC, Bee TK, et al. **Blunt cerebrovascular injuries: diagnosis and treatment.** *J Trauma* 2001;51:279–85; discussion 285–86
8. Biffl WL, Moore EE, Ryu RK, et al. **The unrecognized epidemic of blunt carotid arterial injuries: early diagnosis improves neurologic outcome.** *Ann Surg* 1998;228:462–70
9. Utter GH, Hollingworth W, Hallam DK, et al. **Sixteen-slice CT angiography in patients with suspected blunt carotid and vertebral artery injuries.** *J Am Coll Surg* 2006;203:838–48
10. Cothren CC, Moore EE, Ray CE Jr, et al. **Screening for blunt cerebrovascular injuries is cost-effective.** *Am J Surg* 2005;190:845–49
11. Fabian TC, Patton JH Jr, Croce MA, et al. **Blunt carotid injury. Importance of early diagnosis and anticoagulant therapy.** *Ann Surg* 1996;223:513–22; discussion 522–25
12. Biffl WL, Moore EE, Offner PJ, et al. **Blunt carotid arterial injuries: implications of a new grading scale.** *J Trauma* 1999;47:845–53
13. Cothren CC, Moore EE, Biffl WL, et al. **Anticoagulation is the gold standard therapy for blunt carotid injuries to reduce stroke rate.** *Arch Surg* 2004;139:540–45; discussion 545–46
14. Miller PR, Fabian TC, Croce MA, et al. **Prospective screening for blunt cerebrovascular injuries: analysis of diagnostic modalities and outcomes.** *Ann Surg* 2002;236:386–93; discussion 393–95
15. Sliker CW, Mirvis SE. **Imaging of blunt cerebrovascular injuries.** *Eur J Radiol* 2007;64:3–14
16. Mayberry JC, Brown CV, Mullins RJ, et al. **Blunt carotid artery injury: the futility of aggressive screening and diagnosis.** *Arch Surg* 2004;139:609–12; discussion 612–13
17. Biffl WL, Egglin T, Benedetto B, et al. **Sixteen-slice computed tomographic angiography is a reliable noninvasive screening test for clinically significant blunt cerebrovascular injuries.** *J Trauma* 2006;60:745–51; discussion 751–52
18. Rogers FB, Baker EF, Osler TM, et al. **Computed tomographic angiography as a screening modality for blunt cervical arterial injuries: preliminary results.** *J Trauma* 1999;46:380–85
19. Eastman AL, Chason DP, Perez CL, et al. **Computed tomographic angiography for the diagnosis of blunt cervical vascular injury: is it ready for primetime?** *J Trauma* 2006;60:925–29; discussion 929
20. Schneidereit NP, Simons R, Nicolaou S, et al. **Utility of screening for blunt vascular neck injuries with computed tomographic angiography.** *J Trauma* 2006;60:209–15; discussion 215–16
21. Mutze S, Rademacher G, Matthes G, et al. **Blunt cerebrovascular injury in patients with blunt multiple trauma: diagnostic accuracy of duplex Doppler US and early CT angiography.** *Radiology* 2005;237:884–92
22. McKevitt EC, Kirkpatrick AW, Vertesi L, et al. **Blunt vascular neck injuries: diagnosis and outcomes of extracranial vessel injury.** *J Trauma* 2002;53:472–76
23. Pittock SJ, Moroney JT, Alexander M, et al. **Traumatic bilateral carotid dissection with concomitant cerebral infarction.** *J Emerg Med* 2001;20:33–38
24. Berne JD, Norwood SH, McAuley CE, et al. **The high morbidity of blunt cerebrovascular injury in an unscreened population: more evidence of the need for mandatory screening protocols.** *J Am Coll Surg* 2001;192:314–21
25. Carrillo EH, Osborne DL, Spain DA, et al. **Blunt carotid artery injuries: difficulties with the diagnosis prior to neurologic event.** *J Trauma* 1999;46:1120–25
26. Biffl WL, Moore EE, Offner PJ, et al. **Blunt carotid and vertebral arterial injuries.** *World J Surg* 2001;25:1036–43
27. Bok AP, Peter JC. **Carotid and vertebral artery occlusion after blunt cervical injury: the role of MR angiography in early diagnosis.** *J Trauma* 1996;40:968–72
28. Stuhlfaut JW, Barest G, Sakai O, et al. **Impact of MDCT angiography on the use of catheter angiography for the assessment of cervical arterial injury after blunt or penetrating trauma.** *AJR Am J Roentgenol* 2005;185:1063–68
29. Biffl WL, Ray CE Jr, Moore EE, et al. **Noninvasive diagnosis of blunt cerebrovascular injuries: a preliminary report.** *J Trauma* 2002;53:850–56
30. Stein DM, Boswell S, Sliker CW, et al. **Blunt cerebrovascular injuries: does treatment really matter?** Eastern Association for the Surgery of Trauma 2007; 20th Annual Scientific Assembly, Fort Myers, FL, January 8, 2007
31. Berne JD, Norwood SH, McAuley CE, et al. **Helical computed tomographic angiography: an excellent screening test for blunt cerebrovascular injury.** *J Trauma* 2004;57:11–17; discussion 17–19
32. Loupatatzis C, Schindera S, Gralla J, et al. **Whole-body computed tomography for multiple traumas using a triphasic injection protocol.** *Eur Radiol* 2008;18:1206–14
33. Berne JD, Reuland KS, Villarreal DH, et al. **Sixteen-slice multi-detector computed tomographic angiography improves the accuracy of screening for blunt cerebrovascular injury.** *J Trauma* 2006;60:1204–09; discussion 1209–10