

The **next generation** GBCA  
from Guerbet is here

Explore new possibilities >

Guerbet | 

© Guerbet 2024 GUOB220151-A

# AJNR

## **Diffuse Lipogranulomatosis Involving Soft Tissues of the Head and Neck due to Multiple Self-Injections of Mineral Oil**

S. Kathuria and P.-L. Westesson

*AJNR Am J Neuroradiol* 2008, 29 (10) 1908-1909

doi: <https://doi.org/10.3174/ajnr.A1192>

<http://www.ajnr.org/content/29/10/1908>

This information is current as  
of July 16, 2024.

# Diffuse Lipogranulomatosis Involving Soft Tissues of the Head and Neck due to Multiple Self-Injections of Mineral Oil

## CASE REPORT

S. Kathuria  
P.-L. Westesson

**SUMMARY:** We describe imaging findings of a 45-year-old man with a 6-month history of gradually increasing diffuse swelling of the neck. CT showed diffuse thickening and infiltration of the superficial and deep soft tissues bilaterally. On further investigation of his history, the patient stated that he had injected mineral oil into his neck to clean out his body from drugs. Biopsy results showed multinucleated giant cells and inflammatory infiltrates confirming the diagnosis of lipogranulomatosis.

We report the characteristic imaging appearance of lipogranulomatosis predominantly involving the head and neck region following self-injection of mineral oil in the neck. To our knowledge, the predominant involvement of the head and neck region has not been previously reported in the radiology literature.

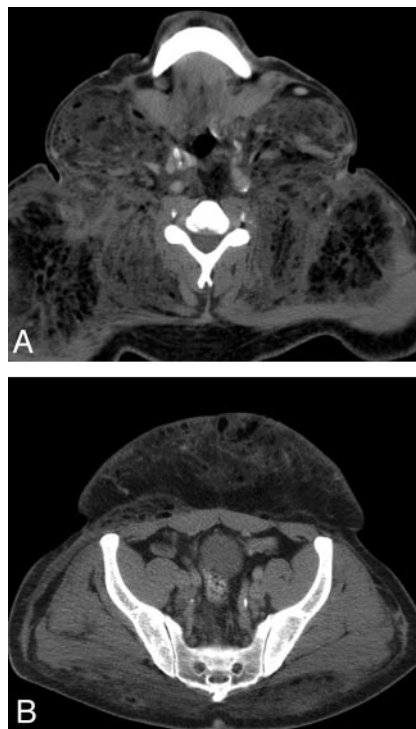
### Case Report

A 45-year-old African American man with a 16-year history of human immunodeficiency virus (HIV), diabetes, and schizophrenia presented with gradually increasing diffuse swelling in the neck for 6 months. He had not seen any physician in the last 6 years and had not been taking any medication during this period. One month previously, he was seen in an emergency department at an outside facility for scrotal swelling and was advised to follow up at the HIV clinic at our hospital. He had been on medication for schizophrenia for a brief period many years before. He had a history of smoking and cocaine abuse but denied any such use for the last 4 years.

On clinical examination, large swellings were noticed in the bilateral supraclavicular and submandibular regions. There was no tenderness or any evidence of cellulitis. Also noticed was induration of the lower portion of the anterior abdominal wall skin extending into the pubic area and scrotum with a peau d'orange appearance. The primary consideration was matted lymphadenopathy, likely secondary to tuberculosis or *Mycobacterium avium intracellulare*. He was then referred for CT scanning of the neck and abdomen.

CT images through the neck showed diffuse thickening of the superficial and deep soft tissue bilaterally with a characteristic infiltrative process and multiple locules of macroscopic fat deposits. The bilateral sternocleidomastoid muscles were especially diffusely prominent with similar infiltration (Fig 1A). Similar but less extensive changes were also seen in chest wall, anterior abdominal wall, scrotum, and gluteal muscles (Fig 1B). On the basis of the characteristic imaging findings, the diagnosis of lipogranulomatosis was suggested.

On further questioning, the patient revealed that he believed his HIV disease was most likely obtained from intravenous drug abuse. He then started injecting mineral oil into his neck and abdomen to clean out his body from drugs. It was only after these injections that he noticed the gradually progressive swelling, especially in the neck and scrotum.



**Fig 1.** A, Axial CT image shows diffuse thickening and infiltration of deep soft tissues with multiple locules of fat. There is involvement of the bilateral sternocleidomastoid muscles. B, Axial CT image shows similar but less extensive involvement of the anterior abdominal wall and gluteal muscles.

Subsequent skin biopsy showed multinucleated giant cells and inflammatory infiltrates of histiocytes and lymphocytes that have a particular tropism for connective and adipose tissue, confirming the diagnosis of lipogranulomatosis due to mineral oil injection.

### Discussion

The first reported subcutaneous injection of exogenous lipids goes back to 1899, when Robert Gersuny from Vienna injected mineral oil to correct the absence of a testicle in a patient who was castrated for tuberculous epididymitis.<sup>1</sup> "Sclerosing lipogranuloma" is a term applied to a complication of this practice in which injected oil elicits a marked granulomatous reaction with prominent fibrosis. Similarly, paraffin-induced sclerosing lipogranuloma is a well-known complication after intradermal injection of paraffin in dermatology and cosmetic and endonasal surgery.<sup>2</sup> Although this complication has been described as a localized process occurring mainly in the scrotal area and regional lymph nodes, few studies have documented systemic manifestations.<sup>3</sup>

Received April 23, 2008; accepted May 1.

From Department of Imaging Sciences, the Division of Diagnostic and Interventional Neuroradiology, University of Rochester Medical Center, Rochester, NY.

Please address correspondence to Sudhir Kathuria, MD, Johns Hopkins University, Radiology B-100, 600 N Wolfe St, Baltimore, MD 21230; e-mail: skathur2@jhmi.edu

DOI 10.3174/ajnr.A1192

Diffuse lipogranulomatosis with similar radiologic and pathologic features can also be seen as extraskkeletal manifestations of Erdheim-Chester disease and Farber disease. However, these diseases predominantly involve the skeletal system.<sup>4</sup>

Although physicians have stopped the practice of oil-injection therapy, some laypersons continue to subject themselves to the risk of the disfiguring complication of lipogranulomatosis. There have been many reports of such complications involving the genital area, with a few involving the abdominal wall and breast.<sup>5,6</sup> In the present case, there was predominant involvement of the neck due to self-injection of mineral oil in that area. Recognition of the characteristic imaging appearance can help physicians reach the correct diagnosis and appropriate management. This case also illustrates the tendency of patients to conceal the history of self-

injection of foreign bodies and associated psychological problems.

## References

1. Glicenstein J. **The first “fillers,” Vaseline and paraffin: from miracle to disaster.** *Ann Chir Plast Esthet* 2007;52:157–61
2. Witschel H, Geiger K. **Paraffin induced sclerosing lipogranuloma of eyelids and anterior orbit following endonasal sinus surgery.** *Br J Ophthalmol* 1994;78:61–65
3. Rollins CE, Reiber G, Guinee DG Jr. **Disseminated lipogranulomatosis and sudden death from self-administered mineral oil injection.** *Am J Forensic Med Pathol* 1997;18:100–03
4. Tan APA, Tan LKA, Choo IH. **Erdheim-Chester disease involving breast and muscle: imaging findings.** *AJR Am J Roentgenol* 1995;164:1115–17
5. Motoori K, Takano H, Ueda T, et al. **Sclerosing lipogranuloma of male genitalia: CT and MR images.** *J Comput Assist Tomogr* 2002;26:138–40
6. Rosen T, Chen M. **Factitious disease of the breast of a male due to injection of liquid plastic.** *Int J Dermatol* 2001;40:743–46