

The **next generation** GBCA
from Guerbet is here

Explore new possibilities >

Guerbet | 

© Guerbet 2024 GUOB220151-A

AJNR

Carotid Disease: The Role of Imaging in Diagnosis and Management

AJNR Am J Neuroradiol 2008, 29 (6) e48-e49
doi: <https://doi.org/10.3174/ajnr.A0979>
<http://www.ajnr.org/content/29/6/e48>

This information is current as
of February 22, 2024.

Carotid Disease: The Role of Imaging in Diagnosis and Management

J. Gillard, M. Graves, T. Hatsukami, and C. Yuan, eds. Cambridge, United Kingdom: Cambridge University Press; 2006, 532 pages, 92 illustrations, \$210.00.

Since the publication of the North American Symptomatic Carotid Endarterectomy Trial nearly 2 decades ago, significant advances in the field of carotid imaging have dramatically expanded the radiologist's armamentarium for diagnosing and characterizing carotid disease. As the landscape of carotid imaging continues to rapidly evolve, the need for an easily accessible, up-to-date, and comprehensive source for information on the topic becomes increasingly evident. Surprisingly, however, there has been a relative paucity of books written on the subject of carotid imaging in recent years, which makes the arrival of the new text, *Carotid Disease: The Role of Imaging in Diagnosis and Management*, a very welcome sight.

This multiauthored book is composed of 8 sections and 35 chapters covering a wide array of topics on the basic science, treatment, and imaging of carotid atherosclerotic disease. Section 1 includes a number of background chapters, which lay the framework for the remainder of the book. Included in this section are chapters on the pathology, epidemiology, and treatment of carotid atherosclerotic disease. The chapters on treatment cover medical management, surgical management for both symptomatic and asymptomatic carotid stenosis, and endovascular techniques. A significant amount of text in these latter chapters is devoted to reviewing and comparing existing data on the indications and relative efficacy of various treatment options. Also included in these chapters are fairly detailed descriptions of surgical and endovascular treatment techniques, which are quite enlightening for those of us who do not perform them.

The next 3 sections cover specific imaging techniques used in evaluating carotid atherosclerotic disease, which the editors divide into "luminal imaging techniques," "morphologic plaque imaging," and "functional plaque imaging." Luminal techniques refer to those used primarily for quantifying the degree of vessel stenosis and include conventional Doppler sonography (US), digital subtraction angiography, CT angiography, and MR angiography, which collectively make up the bulk of carotid imaging techniques used in common practice today. Included in the discussion of luminal techniques is a practical and informative chapter reviewing cost-effectiveness analyses on carotid luminal imaging techniques.

The section on morphologic plaque imaging reviews techniques for noninvasive characterization of plaque composition, including MR, CT, conventional US, and intravascular sonography (IVUS). A brief chapter on image postprocessing concludes the section and focuses primarily on the computer-aided system for cardiovascular disease evaluation developed by researchers at the University of Washington.

"Functional plaque imaging" delves into a number of primarily investigational carotid imaging techniques targeted toward

plaque inflammation. Included in the discussion are nuclear imaging techniques, such as [¹⁸F]fluorodeoxyglucose positron-emission tomography and technetium Tc99m-labeled annexin-A5 single-photon emission CT (SPECT); ultrasmall paramagnetic iron oxide-enhanced MR imaging; and gadolinium-enhanced MR plaque imaging.

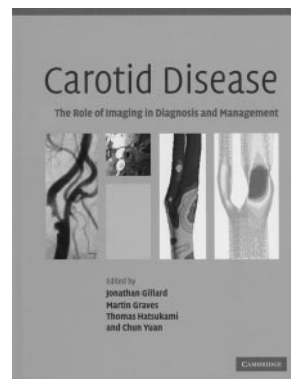
Section 5 focuses on the use of computational modeling to describe the interactions between carotid flow dynamics, shear stress, and plaque composition. Casual readers may find this section a bit too esoteric and technical for their tastes. Nonetheless, the 2 chapters included in this section are quite informative and provide a possible glimpse into the future of carotid MR imaging.

Sections 6 and 7 review techniques used in monitoring the effects of surgical, endovascular, and medical therapies for carotid disease. Topics covered include transcranial Doppler US, MR and CT perfusion imaging of the brain, brain oxygenation measurement with near infrared spectroscopy, brain SPECT imaging, xenon CT imaging, IVUS, and US measurement intima-media thickness. The concluding section speculates on the future directions of carotid plaque imaging, with an emphasis on molecular imaging and evolving MR technology.

A large number of color and black and white figures supplement the text, including a fair number of images correlating imaging with gross and microscopic pathology specimens. With few exceptions, the figures are of very good quality and well annotated. The figure legends are clear and sufficiently descriptive but not overly so. A comprehensive subject index is included, and one nice added touch is a table of abbreviations at the front of the book that defines each of the abbreviations and acronyms used within the text.

Although many of the modalities presented in the book, such as MR angiography and CT angiography, have developed into robust and widely used diagnostic tools for carotid imaging, several of the techniques described in the book, though certainly promising, remain unproven. With regard to these techniques, it remains to be seen whether experimental promise will translate into future clinical practice. In fact, it is probable that some of the modalities contained in the book will never gain widespread acceptance and will ultimately become little more than footnotes in the history of medicine. Nevertheless, the authors of the book have done an outstanding job of presenting the current state of carotid imaging and the outlook for future developments in the field.

As neuroradiologists, we rarely, if ever, pass a workday without encountering some sequela of carotid disease at our view boxes. In all too many cases, by the time a patient presents to the emergency department with an acute stroke, the damage has already been done, and we are little more than after-the-fact observers. However, with the advances being made in the field of carotid imaging, it is becoming increasingly evident that the role of neuroradiologists is shifting, albeit gradually, away from one of stroke diagnosis



toward one of stroke prevention. Although I doubt that we shall ever be able to eliminate stroke entirely during my lifetime, I would not be surprised to see the incidence of stroke decline significantly over the next 50 years, and radiology will play a significant role at the forefront of this movement. For this reason, the relevance of this book can-

not be overstated. *Carotid Disease: The Role of Imaging in Diagnosis and Management* is thoughtful, up to date, comprehensive, and well written and should be on required reading lists for neuroradiologists and, indeed, all physicians involved in the management of carotid disease.

DOI 10.3174/ajnr.A0979