

# Maneuver to Aid Diagnosis of Orbital Varix by Computed Tomography

James Winter,<sup>1</sup> Ricardo S. Centeno, and John R. Bentson

The congenital orbital varix is a form of venous malformation of the orbit resulting in intermittent proptosis in a child, adolescent, or young adult [1, 2]. Vision is seldom affected, although attempts at surgical removal may alter vision [3]. Skull films may demonstrate orbital enlargement or phleboliths within the orbit [4]. Orbital venography and carotid angiography have previously proved useful in the study of vascular abnormalities of the orbit [5–8]. More recently, computed tomography (CT) has been used to further differentiate vascular lesions [9, 10]. We describe a simple CT technique to help demonstrate that an orbital mass is a varix.

## Case Report

A 17-year-old Mexican/American boy had bulging of the right eye for 3 years. The proptosis was increased by straining, leaning forward, or performing a Valsalva maneuver, and it was accompanied by some dizziness and orbital pain.

CT of the brain and orbits in the supine position showed a mass along the medial wall of the right orbit and remodeling of the medial wall (fig. 1A). When the patient assumed the prone position and performed a Valsalva maneuver, the mass enlarged markedly (fig. 1B). Intravenous injection of contrast medium produced significant enhancement of the entire mass. A right internal carotid arteriogram showed enlargement of the ophthalmic artery and many of its

branches. A venous angioma was incidentally noted in the right basal ganglia. Surgery was not recommended.

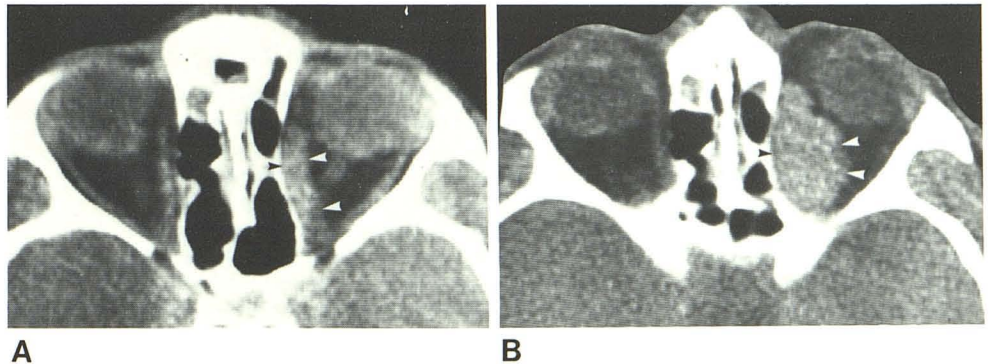
## Discussion

The absence of valves within the venous system extending from the jugular veins intracranially facilitates pooling of blood in enlarged vessels such as orbital varices. This is accentuated by simple maneuvers such as forced expiration, coughing, straining, leaning forward, and manual compression of the jugular veins [1–3]. Similarly, changing the position of the patient so that the orbits are more dependent and adding a Valsalva maneuver may result in a marked change in size of an orbital mass, indicating that, in all probability, the mass is a varix. Orbital venography, the classic radiographic method of confirming the presence of orbital varices, was not considered to be necessary in this case in light of these scan findings. Cerebral angiography was performed instead, demonstrating that the etiology of the varix was an orbital arteriovenous malformation.

## REFERENCES

1. Lloyd GA, Wright JE, Morgan G. Venous malformations in the orbit. *Br J Ophthalmol* 1971;55:505–516

Fig. 1.—Orbital varix enlarging with prone position and Valsalva maneuver. **A**, Supine. Contrast-enhanced mass of medial right orbit (arrowheads). Bowing of medial orbital wall. **B**, Prone. Valsalva maneuver resulted in marked enlargement of medial orbital mass, confirming diagnosis of orbital varix.



Received January 20, 1981; accepted after revision August 7, 1981.

<sup>1</sup> All authors: Department of Radiological Sciences, Neuroradiology Section, UCLA School of Medicine, Los Angeles, CA 90024. Address reprint requests to J. R. Bentson.

2. Jakobiec FA, Jones IS. Vascular tumors, malformations, and degenerations. In: Jones IS, Jakobiec FA, eds. *Diseases of the orbit*. New York: Harper & Row, **1979**:269-308
3. Wright JE. Orbital vascular anomalies. *Trans Am Acad Ophthalmol Otolaryngol* **1974**;78:606-616
4. Lloyd G. Phleboliths in the orbit. *Clin Radiol* **1965**;16:339-346
5. Vignaud J, Clay C, Bilaniak LT. Venography of the orbit: an analytical report of 413 cases. *Radiology* **1974**;110:373-382
6. Russell DB, Miller JDR. Orbital venography. *Radiology* **1974**;103:267-273
7. Dilenge D. Arteriography in angiomas of the orbit. *Radiology* **1974**;113:355-361
8. Hasso AN, Hanafee WN, Vignaud J, Bentson JR, Clay C. Phlebographic appearance and pathogenesis of venous malformations in the orbit. *Acta Radiol [Suppl]* (Stockh) **1975**;347:99-107
9. Moseley IF, Bull JW. Computerized axial tomography, carotid angiography, and orbital phlebography in the diagnosis of space-occupying lesions of the orbit. In: Salamon G, ed. *Advances in cerebral angiography*. New York: Springer, **1975**: 361-369
10. Davis KR, Hesselink JR, Dallow RL, Grove AS. CT and ultrasound in the diagnosis of cavernous hemangioma and lymphangioma of the orbit. *Comput Tomogr* **1980**;4:98-104