

Are your **MRI contrast agents** cost-effective?

Learn more about generic **Gadolinium-Based Contrast Agents**.



FRESENIUS  
KABI

caring for life

**AJNR**

**Spinal subarachnoid hematoma.**

D Frager, R D Zimmerman, H S Wisoff and N E Leeds

*AJNR Am J Neuroradiol* 1982, 3 (1) 77-79

<http://www.ajnr.org/content/3/1/77.citation>

This information is current as  
of May 15, 2024.

# Spinal Subarachnoid Hematoma

David Frager,<sup>1</sup> Robert D. Zimmerman,<sup>1</sup>  
Hugh S. Wisoff,<sup>2</sup> and Norman E. Leeds<sup>1</sup>

A subarachnoid hematoma is the rarest type of clot to form within the spinal canal [1]. Most "so-called" spontaneous cases are related to underlying spinal cord pathology or bleeding diathesis [2]. Another smaller but significant group of patients develop hematomas after lumbar puncture, once again, often with concurrent clotting abnormalities [1]. Our report discusses the myelographic features of a large spinal subarachnoid hematoma that developed after lumbar puncture.

## Case Report

A 39-year-old alcoholic man was admitted to another hospital for evaluation of a grand mal seizure after minor head trauma. Cranial computed tomography (CT) was normal. Lumbar puncture the next day was bloody, and, despite several attempts, yielded only clotting fluid. This was considered to be posttraumatic. Severe low back pain over the ensuing 14 hr was associated with flaccid paraparesis, areflexia, an L3 sensory level with sacral sparing and urinary retention. No thrombocytopenia or other clotting abnormality was identified.

The patient was transferred to Montefiore Hospital and Medical Center 24 hr after the onset of symptoms. Emergency myelography was performed via C1-2 puncture after a dry lumbar tap. From T8 extending inferiorly to the site of a complete block at L2-3 (figs. 1C and 1D), the spinal cord and cauda equina appeared widened in the frontal and lateral projections. At the superior margin of this lesion, a capping defect was noted on all views (figs. 1A and 1B).

Immediately after myelography, a laminectomy from T12 to L3 revealed a large fresh totally subarachnoid clot which was evacuated. The hematoma was confined to the anterior aspect of the canal, displacing the spinal cord and cauda equina posteriorly. No tumor or vascular malformation was identified and the spinal cord was not enlarged. Myelography 2 weeks later (fig. 2) demonstrated disappearance of both the capping defect and apparent cord widening. Arachnoiditis was noted below L2.

## Discussion

Spinal subarachnoid hematoma is rare because dilution of the blood by cerebrospinal fluid and defibrination by the normal pulsation of the brain and spinal cord presumably

prevent thrombus formation. When bleeding is massive and rapid or normal dilution is mechanically impeded, a frank hematoma may form [3]. This unusual event may be precipitated by many causes, which include angioma, aneurysm, periarteritis, systemic lupus erythematosus, blood dyscrasia, neoplasm, coarctation of the aorta, hypertension, endometriosis, and trauma [2, 4, 5]. The lumbar puncture needle may rarely lacerate radicular vessels, and as such cause hemorrhage with consequent hematoma formation, as demonstrated by Masdeu et al. [6] in their postmortem study. In a few cases, no cause is apparent [7].

The acute onset of severe low back pain, rapidly progressive paraparesis, a sensory level, meningismus, and a dry lumbar puncture characterize the clinical picture of subarachnoid hematoma [1]. At surgery or autopsy, the clot may be anywhere in the subarachnoid space, most often in the thoracolumbar region, and it is often adherent to the roots of the cauda equina, which may be compressed or displaced [3]. Following lumbar puncture, the hematoma may not be solely subarachnoid, but may extend via the needle rent into the subdural space [1, 6].

The myelographic features of spinal subarachnoid hematoma are such that a small clot would appear as a nonspecific intradural extramedullary lesion [8-10]. With increasing size, however, the clot begins to envelop or displace the cord (fig. 1). This encasement will result in apparent widening of the cord shadow (figs. 1A and 1C) and, thus, mimic an intramedullary process. Eventually a complete block will be produced. Capping of the contrast column when identified on frontal and lateral views as in our case (figs. 1A and 1B) is the key radiographic feature that ascertains the subarachnoid location and superior extent of the clot.

The differential diagnosis in this case includes carcinomatous meningitis, which may envelop the cord [11] but should not produce capping. On the other hand, an intramedullary tumor with exophytic extension or hemorrhage may produce similar findings. Differentiation of the subarachnoid hematoma from the more common subdural and epidural hematomas is possible because the latter produce

Received February 27, 1981; accepted May 7, 1981.

<sup>1</sup>Department of Radiology, Montefiore Hospital and Medical Center, 111 E. 210th St., Bronx, NY 10467. Address reprint requests to D. Frager.

<sup>2</sup>Department of Neurosurgery, Montefiore Hospital and Medical Center, Bronx, NY 10467.

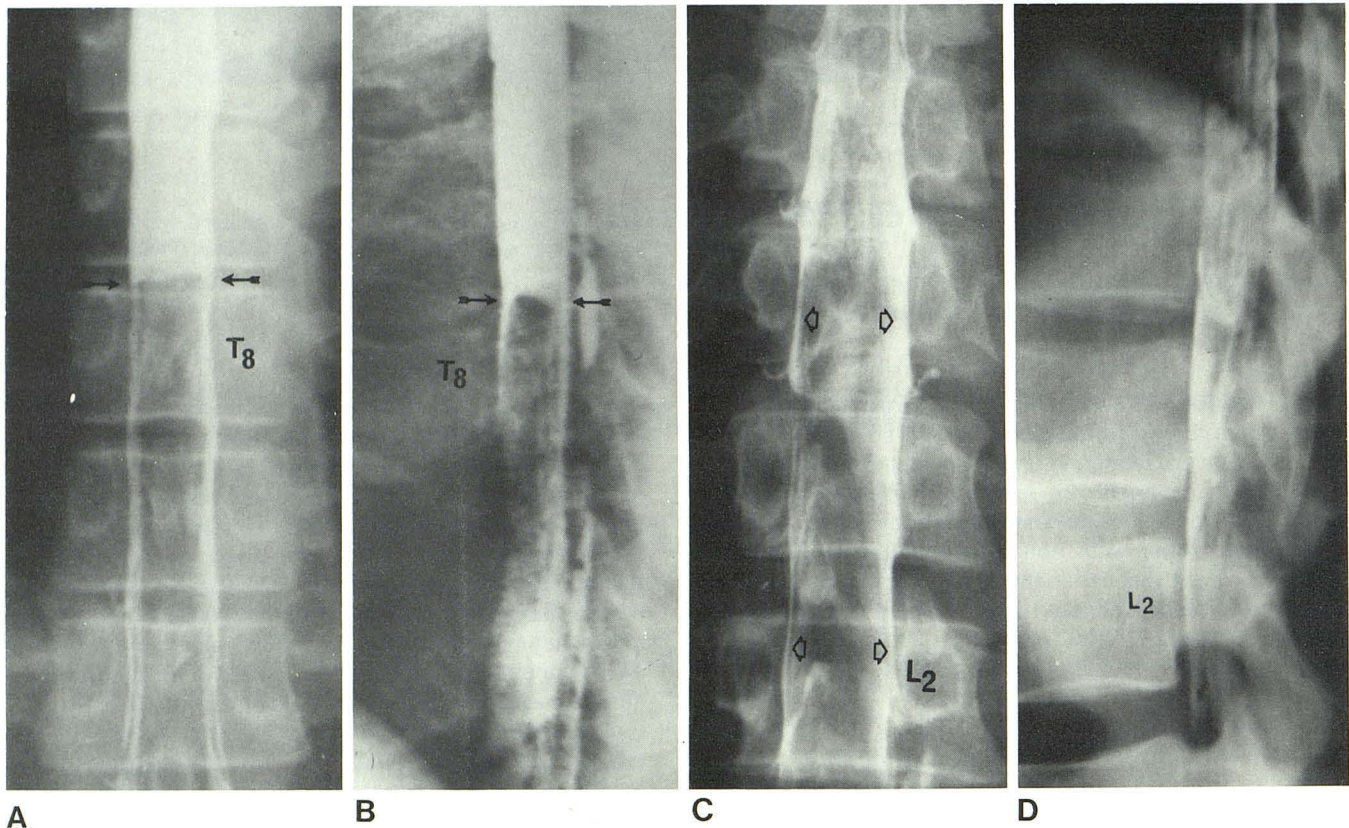


Fig. 1.—Preoperative myelogram via C1–C2 puncture. Frontal (A) and lateral (B) views. Capping defect (arrows) at superior margin of hematoma at T8. Apparent cord widening below defect due to clot surrounding cord. C, Frontal view. Inferiorly, apparent cord expansion mimics intramedullary pro-

cess (arrows). Dilated vascular channels on surface of cord (T9–T12), but no vascular malformation was identified at surgery. D, Lateral view. Complete block at L2–3 and no contrast dorsally below T12 due to posterior displacement of cord by hematoma.

extraarachnoidal myelographic defects. Epidural hematomas tend to displace the axillary pouches, while subdural hematomas may not [12].

Preoperative evaluation of subarachnoid hematoma requires myelography for definitive localization. An adequate amount of contrast material and maintenance of the patient in the erect position will best outline the full extent of the lesion because of the constricted subarachnoid space. C1–C2 puncture will usually be required since the lumbar tap is often dry. While Pantopaque was used in our case, metrizamide is the contrast agent of choice since it should allow for excellent depiction of the lesion without the problem of residual contrast in the subarachnoid space. If surgery fails to reveal an underlying cause for the hemorrhage, myelography should be repeated. Finally, spinal CT, especially with recently developed high resolution techniques, may prove to be the ideal diagnostic procedure in evaluation of these cases. A hyperdense envelope of subarachnoid blood surrounding or displacing the spinal cord should be diagnostic.

#### REFERENCES

1. Kirkpatrick D, Goodman ST. Combined subarachnoid and subdural spinal hematoma following spinal puncture. *Surg Neurol* 1975;3:109–111
2. Henson RA, Croft PB. Spontaneous spinal subarachnoid hemorrhage. *Q J Med* 1956;25:53–66
3. Rengachary SS, Murphy D. Subarachnoid hematoma following lumbar puncture causing compression of the cauda equina. *J Neurosurg* 1974;41:252–254
4. Epstein B. *The spine*. Philadelphia: Lea & Feiberger 1976: 763–774
5. Fody EP, Netsky MG, Mrak RE. Subarachnoid spinal hemorrhage in a case of systemic lupus erythematosus. *Arch Neurol* 1980;37:173–174
6. Masdeu JC, Breuer AC, Schoene WC. Spinal subarachnoid hematomas: clue to a source of bleeding in traumatic lumbar puncture. *Neurology (NY)* 1979;29:872–876
7. Plotkin R, Ronthal M, Froman C. Spontaneous spinal subarachnoid hemorrhage. Report of 3 cases. *J Neurosurg* 1966;25: 443–446
8. Lombardi G, Passerini A. *Spinal cord diseases: a radiologic and myelographic analysis*. Baltimore: Williams & Wilkins, 1964:160
9. King OJ, Glas WW. Spinal subarachnoid hemorrhage following lumbar puncture. *Arch Surg* 1960;80:574–577
10. Rice JF, Shields CB, Morris CF, Neely BD. Spinal subarachnoid hemorrhage during myelography. *J Neurosurg* 1978;48:645–648
11. Taveras JM, Wood EH. *Diagnostic neuroradiology*. Baltimore: Williams & Wilkins, 1976:1199
12. Guthikonda M, Schmidek IT, Wallman L, Snyder T. Spinal subdural hematoma: case report and review of the literature. *J Neurosurg* 1979;5:614–616

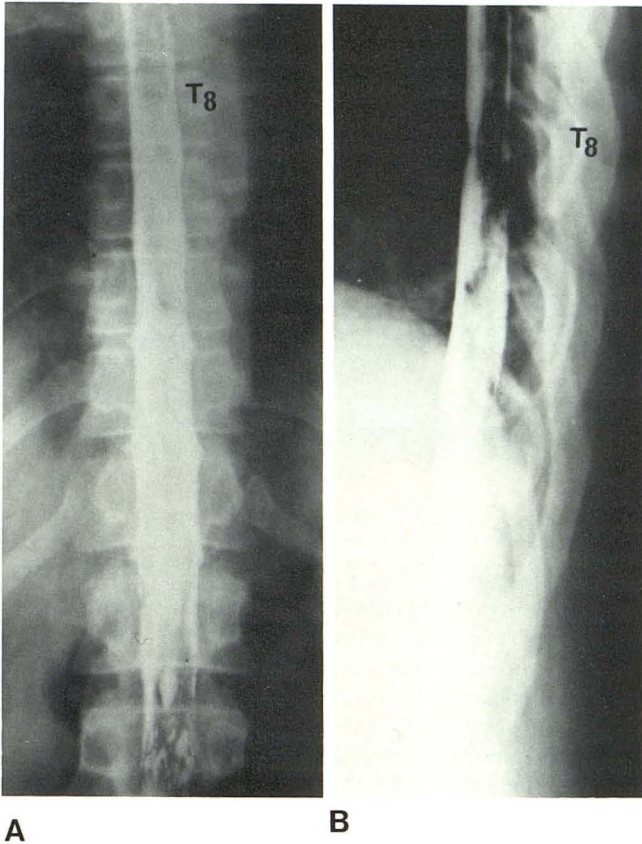


Fig. 2.—Postoperative myelogram via C1–C2 puncture. Frontal (A) and lateral (B) views after evacuation of clot. Disappearance of both capping defect and apparent cord widening. Arachnoiditis below L2.