

Are your **MRI contrast agents** cost-effective?

Learn more about generic **Gadolinium-Based Contrast Agents**.



FRESENIUS
KABI

caring for life

AJNR

Another Look at Blow-Out Fractures of the Orbit

Steven B. Hammerschlag, Susan Hughes, Gerald V. O'Reilly and
Alfred L. Weber

AJNR Am J Neuroradiol 1982, 3 (3) 331-335
<http://www.ajnr.org/content/3/3/331>

This information is current as
of May 17, 2024.

Another Look at Blow-Out Fractures of the Orbit

Steven B. Hammerschlag¹
 Susan Hughes²
 Gerald V. O'Reilly¹
 Alfred L. Weber³

Thirty cases of orbital floor blow-out fractures proven by tomography were retrospectively reviewed to determine the accuracy of the plain films. Using the maximum diameter from the tomograms, the area and volume of the fractures were calculated and correlated with the presence of diplopia and enophthalmos at the time of presentation and at subsequent follow-up. Nine of the 30 cases underwent surgical repair. Orbital floor fractures were recognized in 29 of 30 cases using only the 28° Caldwell and Waters views. Routine tomography is unnecessary and should be reserved as a preoperative evaluation in patients with enophthalmos to establish the presence of a significant associated medial wall prolapse.

In 1889, Lang [1] described a case of traumatic enophthalmos and suggested that this was due to a depressed internal orbital wall fracture. In 1943, Pfeiffer [2] reported 24 cases of internal orbital fractures with development of enophthalmos. He postulated the mechanism of injury as a blow transmitted through the eyeball to the orbital walls with fracture, the orbital rim remaining intact. In 1957, Smith et al. [3, 4] confirmed this mechanism with a cadaver experiment and these fractures were subsequently termed as "blow-out" fractures.

The management of blow-out fractures is controversial. Historically, the accepted treatment was early repair of the defect to prevent persistent diplopia and enophthalmos [5]. This approach presumes these complications occur frequently in untreated fractures. Other authors state that in most cases the diplopia resolves with time and advocate surgery only for patients with cosmetically significant enophthalmos [6, 7]. Most surgeons now agree that a blow-out fracture is not a surgical emergency [8] and delay the decision to operate for 10–14 days, after which repair is performed selectively on the basis of persistent diplopia or enophthalmos [9]. The presence of a fracture in itself does not necessitate surgical intervention.

For a long time, radiology has played an important part in diagnosis. Pfeiffer [2] showed the usefulness of the Caldwell and Waters views. Other authors have indicated the advantages of modified plain film views and tomography [10–13]. We undertook a study to correlate the clinical and radiographic changes in blow-out fractures and to assess the part radiography plays in light of the current more conservative approach to management. The question of whether radiography should be considered an urgent requirement is reexamined.

Materials and Methods

We analyzed retrospectively 30 cases of blow-out fractures of the orbital floor proven by hypocycloidal tomography. The age range of the patients was 13–50 years (average, 25 years). There were 28 males and two females. All patients underwent plain film radiography, which included a 28° Caldwell (projecting the petrous ridge just below the inferior orbital rim) (fig. 1A) and a Waters view. Similar plain film views in 30 cases of patients with

This article appears in the May/June 1982 issue of *AJNR* and the July 1982 issue of *AJR*.

Received September 15, 1981; accepted after revision February 2, 1982.

Presented at the annual meeting of the American Society of Head and Neck Radiology, Los Angeles, May 1981.

¹Department of Radiology, Harvard Medical School, Brigham and Women's and Beth Israel Hospitals, Boston, MA 02115. Address reprint requests to S. B. Hammerschlag, Brigham and Women's Hospital, 75 Francis St., Boston, MA 02115.

²Department of Ophthalmology, Massachusetts Eye and Ear Infirmary, Boston, MA 02114.

³Department of Radiology, Massachusetts Eye and Ear Infirmary, Boston, MA 02114.

AJNR 3:331–335, May/June 1982
 0195–6108/82/0303–0331 \$00.00
 © American Roentgen Ray Society

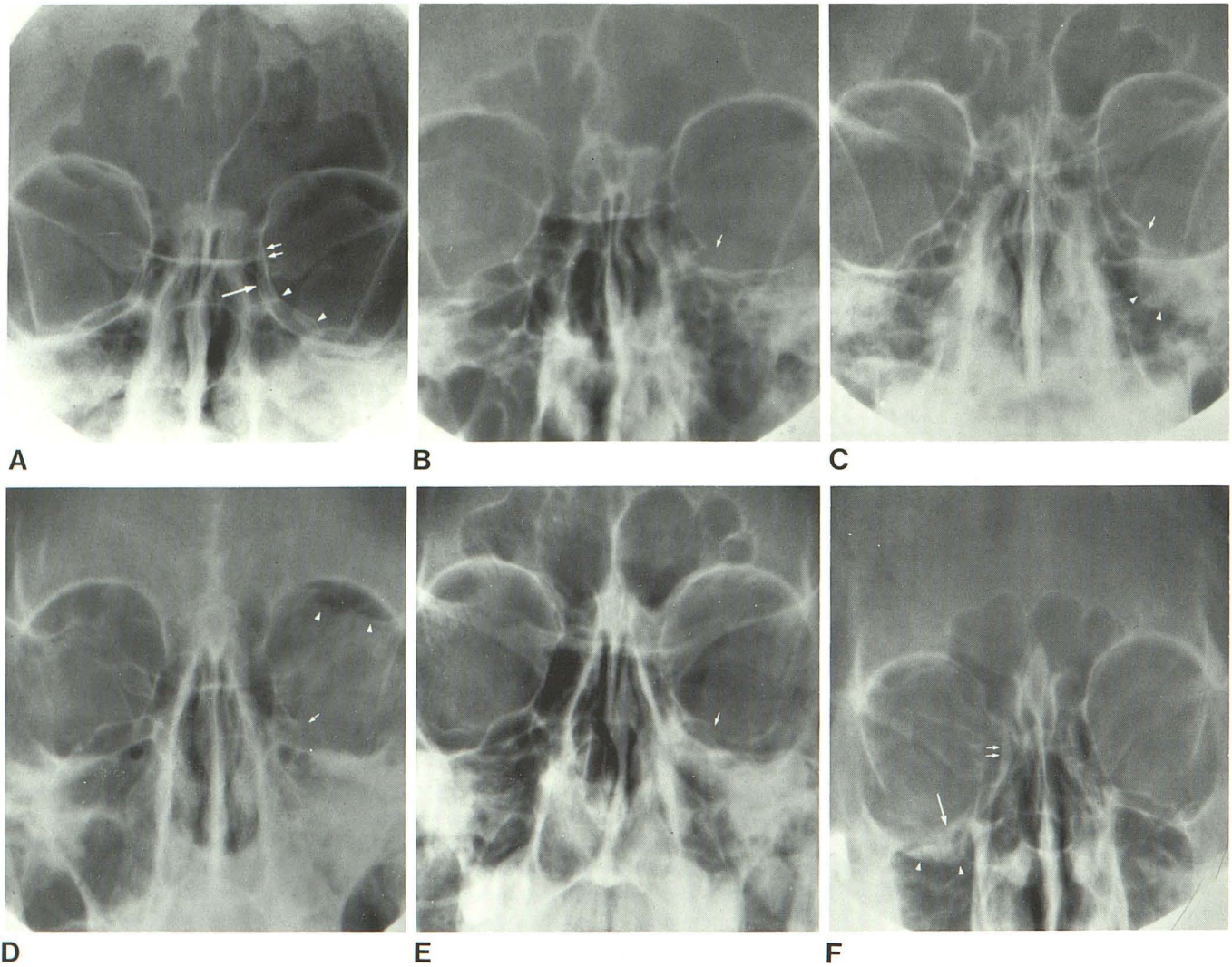


Fig. 1.—28° Caldwell views projecting petrous ridge just below inferior orbital margin. **A**, Normal orbits. Lamina papyracea of ethmoid bone forming medial orbital wall (*short arrows*) is more lateral than medial orbital rim (*long arrow*). Orbital floor formed by orbital plate of maxilla (*arrowheads*) extends from ethmoidomaxillary plate (*upper arrowhead*) to inferior orbital groove (*lower arrowhead*). **B**, Orbital floor blow-out fracture. Orbital plate of maxilla is absent (*arrow*). **C**, Orbital floor blow-out fracture. Lateral aspect of orbital plate of maxilla absent (*arrow*). Soft-tissue density projects into maxillary

antrum (*arrowheads*). **D**, Orbital floor blow-out fracture with absent orbital plate of maxilla (*arrow*). In addition, orbital emphysema (*arrowheads*) and opacification of antrum. No medial wall fracture (confirmed by anteroposterior tomography). **E**, Step-off of orbital plate of maxilla indicates floor fracture (*arrow*). Ipsilateral ethmoid clouding suggests medial wall fracture (presumptive finding). **F**, Depressed orbital plate of maxilla (*long arrow*) and density projecting into antrum (*arrowheads*) indicates floor fracture. Definite evidence of medial wall fracture manifested by bony displacement (*short arrows*).

inflammatory sinus disease were reviewed as controls.

We established positive criteria for plain film diagnosis of blow-out fractures. For fracture of the orbital floor, the positive signs were bone discontinuity or bone displacement on either the Caldwell (figs. 1B–1F) or Waters view or both. Although presumptive signs (antral roof density, antral air-fluid level, or orbital emphysema) were present in many of the cases, they were not used, as they alone did not demonstrate definite evidence of bone disruption (e.g., an isolated soft-tissue density in the antral roof without definite evidence of fracture would be regarded as negative for fracture). However, invariably, an antral roof density was accompanied by evidence of bone disruption.

Similarly, positive diagnosis of a medial wall fracture on plain films required visualization of actual bone displacement, which had to be confirmed on anteroposterior tomograms. Again, the presumptive criteria (unilateral ethmoid clouding and orbital emphysema) alone were not used.

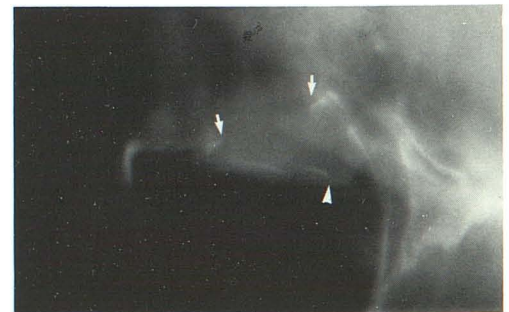

Fig. 2.—Lateral tomogram. Example of measurements. Distance from arrow to arrow constitutes maximum sagittal diameter of floor fracture. Maximum floor depression measured from posterior arrow to arrowhead. All measurements are corrected for magnification.

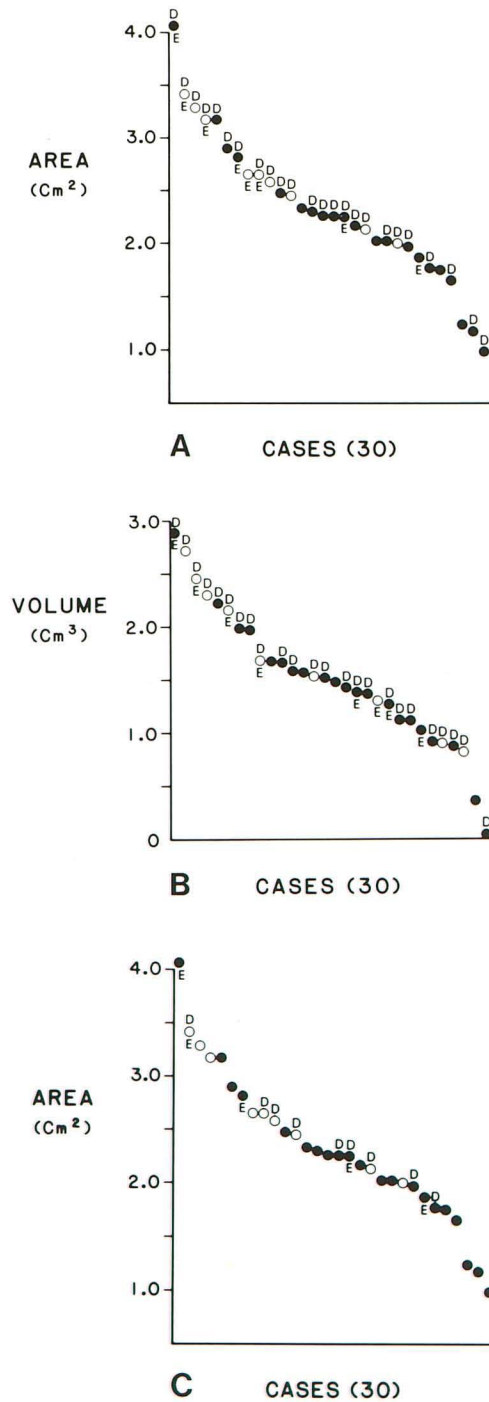


Fig. 3.—30 cases of orbital floor blow-out fractures in sequential order of size. A, Fracture area (maximum transverse × maximum sagittal diameter). B, Fracture volume (area × maximum floor depression). Each dot represents one case; white dots are patients who went to surgery; black dots are patients treated conservatively. D above dot indicates diplopia; E indicates enophthalmos at initial examination. It is apparent that diplopia occurred with all sizes of fracture, enophthalmos with larger fractures, and larger fractures were selected for surgery. C, Follow-up examination (postoperative for white dots). Eight of nine cases with residual diplopia correspond to fracture sizes of 1.75–2.75 cm².

The maximum dimensions of the orbital floor fractures were measured from the tomograms in the transverse and sagittal diameter as well as the maximum floor depression (fig. 2). After magnification correction, the fractures were tabulated in sequential order

TABLE 1: Clinical Evaluation of Orbital Floor Blow-out Fractures

Clinical Findings	Surgical Cases (n = 9)	Nonsurgical Cases (n = 21)
Initial examination:		
Extreme gaze diplopia	2	6
Functional diplopia	6	10
Enophthalmos	4	4
Follow-up examination:		
Extreme gaze diplopia	3	4
Functional diplopia	2	0
Enophthalmos	1	4

of size (calculated for both area and displacement volume) (fig. 3). Review of the patients charts revealed that nine underwent surgical repair of the floor defect and 21 were managed conservatively. The presence of diplopia and enophthalmos at the initial examination and subsequent follow-up (ranging from 1 week to 20 months) was recorded (table 1). These symptoms and signs at the time of presentation and at follow-up were correlated with the fracture sizes (fig. 3).

Results

The controls demonstrated excellent symmetry between the orbital plates of the maxillae on either side (fig. 1A), with an occasional mild asymmetry at the lateral aspect of the plate as it descends into the infraorbital groove.

In the 30 cases of orbital floor blow-out fractures, the 28° Caldwell view was positive in 26 (87%) and the Waters view positive in 25 (83%), giving a combined positive of 29 (97%) cases. Although the presumptive criteria were not used to identify fracture, their presence alerts the viewer to search for the bone discontinuity. Of the 30 cases, 10 had antral air-fluid levels, seven had orbital emphysema, and five had both. All cases that demonstrated these presumptive signs also had definite signs of a fracture. The one case that had no definite evidence of a fracture on either the Caldwell or Waters view had ipsilateral ethmoid clouding, but no other presumptive signs. The fracture measured 1.17 cm² and is recorded as the second smallest fracture in figure 3A.

Medial wall fractures were definitely diagnosed on the 28° Caldwell view in two (6%) cases (fig. 1F). The tomograms definitely diagnosed eight (26%) medial wall fractures. Unilateral ethmoid clouding, however, a presumptive sign, was present in 16 (53%) cases (fig. 1E).

Of the 30 patients, 24 had diplopia on initial examination. These cases are distributed uniformly throughout the range of fracture sizes (figs. 3A and 3B). At follow-up examinations (postoperative for the surgicals), nine cases had residual diplopia. These were mostly medium-sized (fig. 3C). Eight of the nine cases with residual diplopia had fracture sizes of 1.75–2.75 cm².

For the eight patients with enophthalmos at the time of presentation (fig. 3A), there was a definite correlation with the area of fracture. Six of these occurred in the upper third of the spectrum with a fracture area of 2.5 cm² or greater. Only one case of enophthalmos was present below an area of 2 cm². There was no correlation between the presence of enophthalmos and the fracture volume at follow-up.

Discussion

By obtaining correct plain film views and applying definite criteria, the accuracy of recognizing clinically significant orbital floor fractures is excellent [14]. There should be no false-positives. An unknown number of small fractures, less than 1 cm in diameter, may be missed, even with tomography, especially comminuted fractures with no bone displacement [15]. These fractures are, however, of little clinical consequence. The notion that small fractures tend to be associated with muscle entrapment [16] did not hold up in our study.

Diplopia at the time of presentation in a blow-out fracture is a common symptom. It was apparent in 24 of our 30 cases. Diplopia usually results from restricted contraction of the inferior rectus, inferior oblique or medial rectus muscles caused by edema, hemorrhage, or damage to the nerve supplying the muscles. Fixation of the muscles by the bony defect—a true muscle incarceration—is rare [17]. In most patients treated conservatively, the diplopia resolves in time. In our series, there was no correlation between diplopia and fracture size, and the size of the defect had no bearing on persistence of this symptom.

Enophthalmos in the acute phase can only result from prolapse of orbital contents into adjacent sinuses. In our series, enophthalmos correlated well with the area of the fracture, being more common with larger defects. It did not appear to correlate as well with volume of the fracture, which suggests that the point of maximum floor displacement is an inaccurate parameter for estimating overall floor depression (figs. 3A and 3B). Cosmetically significant enophthalmos is a firm indication for surgery. Ideally, this should be performed early as delayed repair is more difficult [8]. Historically, tomography has been used in suspected blow-out fractures to detect large defects and, thus, predict which patients are likely to develop enophthalmos. In our series, there were no cases of late onset of enophthalmos. However, delayed enophthalmos is well documented [16] and may result from a gradual prolapse of orbital contents through a bony defect. It may also be due to scarring and retraction of orbital contents without prolapse. In any event, it is not a frequent occurrence. Enophthalmos usually manifests early, either immediately after trauma, or within 2 weeks after the swelling has subsided. Therefore, patients can be selected for surgery on the basis of clinical enophthalmos, and not necessarily on the basis of a large fracture as seen on tomography. The application of routine tomography in all suspected blow-out fractures seems unnecessary in view of the limited yield in predicting late onset enophthalmos.

Medial wall blow-out fractures have been noted to occur in a high percentage of orbital floor fractures produced experimentally in cadaver studies [15, 18]. Although plain films and tomography only occasionally demonstrate clear evidence of ethmoid fractures with definite bone displacement, the true incidence is probably in excess of 50%, as was suggested in our study by ethmoid clouding. Most of these fractures are small and have little clinical significance because entrapment of the medial rectus muscle is infre-

quent [19–21]. However, large defects may have important sequelae as orbital contents prolapse into the ethmoid labyrinth. Of the five patients with residual enophthalmos at follow-up, three had cosmetically significant enophthalmos. In each of these, there was a large medial defect with prolapse. This suggests that a medial wall defect may be a contributing factor in the development of enophthalmos. Therefore, any patient with enophthalmos should undergo anteroposterior tomography to assess the medial orbital wall, with appropriate surgical repair of a significant medial defect, if present. Postoperative residual enophthalmos after repair of a floor fracture, as was noted in one patient, may well be the result of an unrecognized medial wall prolapse.

To summarize, plain films (28° Caldwell and Waters views) can positively diagnose a very high percentage of orbital floor blow-out fractures. Small fractures of less than 1 cm diameter may be missed but they have little clinical significance. Routine tomography in all suspected cases of blow-out fractures is not necessary. It should be reserved for patients with enophthalmos where it is important to establish the presence of an additional medial wall defect with prolapse of orbital contents into the ethmoid labyrinth. Whereas there is no correlation between fracture size and diplopia, enophthalmos is usually present with fractures over 2.5 cm² in area.

REFERENCES

- Lang W. Injuries and disease of the orbit. *Trans Ophthalmol Soc UK* 1889;9:41–45
- Pfeiffer R. Traumatic enophthalmos. *Arch Ophthalmol* 1943;30:718–726
- Smith B, Regan WF. Blow-out fracture of the orbit. Mechanism and correction of internal orbital fracture. *Am J Ophthalmol* 1957;44:733–739
- Converse JM, Smith B. Enophthalmos and diplopia in fractures of the orbital floor. *Br J Plast Surg* 1957;9:265–274
- Converse JM, Smith B. Orbital blow-out fractures: a ten-year survey. *Plast Reconstr Surg* 1967;39:20–36
- Putterman AM, Stevens T, Urist MJ. Nonsurgical management of blow-out fractures of the orbital floor. *Am J Ophthalmol* 1974;77:232–239
- Putterman AM. Late management of blow-out fractures of the orbital floor. *Ophthalmology (Rochester)* 1977;83:650–662
- Converse JM, Smith B. On the treatment of blow-out fractures of the orbit. *Plast Reconstr Surg* 1978;62:100–104
- Crikelair GF, Rein JM, Potter GD, Cosman B. A critical look at the "blow-out" fracture. *Plast Reconstr Surg* 1972;49:374–379
- Culler AM. Fractures of the orbit: the demonstration of the orbit by planography (bony section radiography). *Trans Am Ophthalmol Soc* 1940;38:348–369
- Lewin JR, Rhodes DH, Ravsek EJ. Roentgenologic manifestations of fracture of the orbital floor (blow-out fracture). *AJR* 1960;83:628–632
- Zizmor J, Smith B, Fasano C, Converse JM. Roentgen diagnosis of blow-out fractures of the orbit. *AJR* 1962;87:1009–1018
- Dodick JM, Berret A, Galin MA. Hypocycloidal tomography and orbital blow-out fracture. *Am J Ophthalmol* 1969;68:483–486

14. Zizmor J, Lombardi G. *Atlas of orbital radiography*. Birmingham, AL: Aesculapius, **1973**:24
15. Hammerschlag SB, Hughes S, O'Reilly GV, Naheedy MH, Rumbaugh CL. Blow-out fractures of the orbit: a comparison of computed tomography and conventional radiography with pathologic correlation. *Radiology* (In press)
16. Smith B, Petrelli R. Fractures of the orbit: blow-out and naso-orbital fractures. In: Freeman HM, ed. *Ocular trauma*. New York: Appleton-Century-Crofts, 1979:117-123
17. Helveston EM. The relationship of extraocular muscle problems to orbital floor fractures: early and late management. *Ophthalmology* (Rochester) **1977**;83:660-662
18. Pearl RM, Vistnes LM. Orbital blow-out fractures: an approach to management. *Ann Plast Surg* **1978**;1:267-270
19. Rumelt MB, Ernest JT. Isolated blow-out fracture of the medial orbital wall with medial rectus muscle entrapment. *Am J Ophthalmol* **1972**;73:451-453
20. Thering HR, Bogart JN. Blow-out fracture of the medial orbital wall with entrapment of the medial rectus muscle. *Plast Reconstr Surg* **1979**;63:848-852
21. Edwards WC, Ridley RW. Blow-out fracture of the medial orbital wall. *Am J Ophthalmol* **1968**;65:248-249