

Are your **MRI contrast agents** cost-effective?

Learn more about generic **Gadolinium-Based Contrast Agents**.



FRESENIUS
KABI

caring for life

AJNR

Brain parenchyma penetration by intrathecal ionic and nonionic contrast media.

M R Sage, J Wilcox, C A Evill and G T Bennes

AJNR Am J Neuroradiol 1982, 3 (5) 481-483

<http://www.ajnr.org/content/3/5/481>

This information is current as
of April 18, 2024.

Brain Parenchyma Penetration by Intrathecal Ionic and Nonionic Contrast Media

Michael R. Sage¹
 John Wilcox
 Charles A. Evill
 Geoffrey T. Benness

Metrizamide, a nonionic water-soluble contrast medium, has been shown to penetrate normal brain when injected intrathecally. Recently it was suggested that the complications following intrathecal metrizamide are directly related to the cerebral concentration reached. Metrizamide, both in experimental animals and clinically, is regarded as less neurotoxic than equivalent iodine concentrations of ionic contrast media. In this study the degree and depth of brain penetration of intrathecal metrizamide and methylglucamine iohalamate (Conray 280), using a similar iodine concentration (280 mg I/ml), was compared at 1 hr in adult greyhound dogs. The depth of penetration and concentration reached in the cortical gray matter was determined by coronal computed tomographic scanning of the brain after removal. No significant difference was found between the two contrast media, suggesting that the rate of diffusion across the cerebrospinal fluid-brain interface is similar and that the difference in neurotoxicity is not explained by a reduced concentration of contrast medium in the case of nonionic metrizamide, when compared with ionic methylglucamine iohalamate. Using Evans blue as a qualitative marker, no evidence of gross blood-brain disruption was demonstrated in the area of maximum penetration with either contrast medium.

Compared with the more hypertonic ionic contrast media, the nonionic contrast medium metrizamide has been shown experimentally to be less toxic, particularly to the nervous system, and it is now used widely for myelography and ventriculography [1]. Its lack of neurotoxicity compared with ionic water-soluble contrast media has been well documented both in experimental animals [2, 3] and by clinical trials [1, 4, 5]. However, it is not completely biologically inert, and a relatively high incidence of postmyelographic headache and other symptoms remain a problem [6, 7].

Penetration of metrizamide into the brain parenchyma has been demonstrated after its introduction into the subarachnoid space [8, 9]. While a physiologic barrier between the blood and brain parenchyma has been well documented [10], there is an apparent lack of a diffusion barrier between the cerebrospinal fluid (CSF) and the extracellular fluid of the brain parenchyma [10-12], allowing penetration of contrast media after intrathecal injection [8, 9, 11]. This penetration may be relevant in explaining the incidence of adverse effects encountered with intrathecal water-soluble contrast media [13]. To determine whether the degree of brain penetration is a factor in the different toxicity between ionic and nonionic media, using a canine model, the degree of brain penetration of metrizamide and methylglucamine iohalamate after intrathecal injection was compared, and the gross effect of the penetration on the blood-brain barrier (BBB) was documented.

Materials and Methods

Adult greyhound dogs of either gender, weighing 20-32 kg, were anesthetized with intravenous pentobarbital (Pentothal), 25 mg/kg, and after intubation, anesthesia was maintained using 1% halothane in a 1:1 mixture of nitrous oxide

Received November 9, 1981; accepted after revision March 19, 1982.

¹All authors: Department of Radiology, Flinders Medical Centre, Bedford Park, South Australia. Address reprint requests to M. R. Sage.

AJNR 3:481-483, September/October 1982
 0195-6108/82/0305-0481 \$00.00
 © American Roentgen Ray Society

and oxygen. Respiration was controlled at 8 breaths/min with an Oxford ventilator.

With the dog in a prone position with the neck flexed, cisternal puncture was performed using a 22 gauge needle, and 6 ml of test solution was injected into subarachnoid space slowly over 2 min. Radiography was performed to determine successful intrathecal injection, and, if a clean puncture was not obtained, the study was abandoned. Four studies with each of the two test solutions were performed, namely metrizamide at a concentration of 280 mg l/ml and methylglucamine iohalamate (Conray 280, 280 mg l/ml).

After intrathecal injection of the contrast media, the dog was placed in a head-down position for 2 min, during which time the head was rolled gently from side to side; after this, the dog was returned to a prone position with the neck remaining slightly flexed. Evans blue is an established visual marker of BBB disruption [10] and 3 ml/kg of Evans blue solution (2% in 0.9% saline, membrane filtered) was administered intravenously 3 min after the intrathecal injections.

The animals were killed by an intravenous injection of 10–15 ml of saturated potassium chloride solution 60 min after the end of the intrathecal injection. Within 15 min, the brain was removed and the surface rinsed with an isotonic solution (Hartmann solution, Travenol Labs, Sydney, Australia) to remove overlying CSF and contrast media. The brain was then suspended in Hartmann's solution in a sealed, cylindrical, perspex container and positioned in the computed tomographic (CT) scanner (EMI model 5005). After phantom studies to ensure the accuracy of attenuation values, coronal scans were obtained at 1 cm intervals, using 13 mm collimation (fig. 1). After obtaining CT scans, the brain was sectioned in the coronal plane and qualitative assessment of the presence of any Evans blue staining was performed by two independent observers.

The coronal CT sections were assessed for evidence of brain penetration by the contrast media. Since subsequent results indicated that consistent and maximum penetration was demonstrated in the anterior and mid temporal region bilaterally, quantitative measurements were made in these regions by calculating the mean EMI number in a 100 pixel region of interest in the middle of the gray matter in both temporal lobes (fig. 1).

Five control studies without an intrathecal injection were performed to determine the maximum attenuation value of the normal canine brain. The gray matter was never greater than 24 EMI units. With this information, blind subjective assessment of the depth of penetration of contrast medium into both temporal lobes was assessed at two adjacent levels in the eight studies. The window width of the diagnostic display console was placed on "measure" setting and the level set at 25 EMI units. The depth of attenuation values above that of normal gray matter could then be measured directly at right angles to the brain surface in the same region of the temporal lobe for each study (fig. 1). This allowed a blind subjective assessment of brain penetration.

Results

CT attenuation values were compared for methylglucamine iohalamate and metrizamide. The mean EMI number

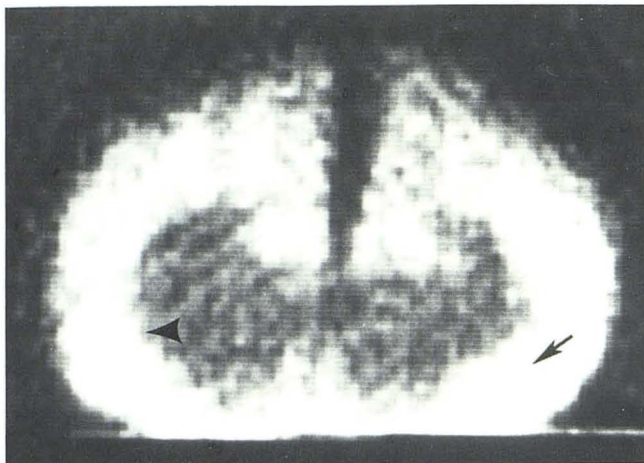


Fig. 1.—Coronal CT scan of canine brain after intrathecal metrizamide (280 mg l/ml) has been contact with cortical surface for 60 min. Hyperdense gray matter is due to contrast penetration through CSF–brain interface. Region of interest sites for concentration assessment (arrow) and level of depth of penetration measurement (arrowhead).

for a 100 pixel region of interest for each series of experiments was 37.0 ± 9.1 for methylglucamine iohalamate and 39.2 ± 10.8 for metrizamide. Analysis using *t* test showed no significant difference between the concentration of iodine obtained by either contrast medium within the brain parenchyma ($p < 0.1$).

The depth of penetration into the brain parenchyma was similar after 1 hr. For methylglucamine iohalamate, it was 13.7 ± 1.6 mm; for metrizamide, it was 13.4 ± 0.9 mm ($p < 0.01$). There was no evidence of Evans blue staining of the parenchyma in the temporal region of either hemisphere in any of the studies, despite the obvious presence of contrast media in these areas, as indicated by iodine concentration demonstrated by CT.

Discussion

Our study confirmed the findings of others [8, 9, 12] that there is free passage of both ionic and nonionic water-soluble contrast media across the CSF–brain interface. Unlike the BBB between cerebral capillaries and the brain parenchyma, no obvious barrier exists at the pial surfaces to the passage of small water-soluble molecules [10, 12, 14, 15], and evidence suggests that they enter the brain parenchyma by simple diffusion into the extracellular space [11]. A similar concentration of iodine, as measured by CT, was obtained with both methylglucamine iohalamate (ionic) and metrizamide (nonionic). CT measurements have been shown to be a valid method of quantitative comparison of contrast media density [16]. The rate of complications after intrathecal metrizamide has been shown to be directly related to the cerebral concentration reached by the contrast medium [13]. Using contrast media of similar iodine concentrations, our study has shown that the iodine concentration reached by both ionic and nonionic contrast media within the cortical gray matter is similar. This indicates that the increased toxicity of ionic contrast media is not related

simply to the iodine concentration reached within the brain parenchyma but to other factors.

The depth of penetration after 1 hr, as measured in the temporal region, was similar for both methylglucamine iohalamate and metrizamide, indicating a similar rate of diffusion across the CSF-brain interface into the extracellular brain tissue. This would indicate that the ionic state does not determine such penetration across the CSF-brain interface, and the reduced toxicity of metrizamide is therefore not related to a reduction in the depth of brain penetration when compared with ionic contrast media.

Although in vivo cerebral penetration in man following metrizamide myelography has been reported [8, 13], in our studies, as with other animal studies [8, 9], there is the possibility that the brain penetration by the contrast medium could be at least partly a postmortem phenomenon during the time required to remove the brain. In the future, in vivo studies would be more appropriate to exclude this possibility.

Although recognized as perhaps a crude marker of BBB integrity, no obvious Evans blue staining of the brain was demonstrated in the areas of maximum contrast concentration with either methylglucamine iohalamate or metrizamide. This would suggest that the presence of a significant concentration of either ionic or nonionic contrast media within the extracellular fluid does not have a gross effect on the integrity of the BBB. The brain distribution of metrizamide after subarachnoid injection has been shown to be primarily extracellular [9]. Other lipid-insoluble metabolically inert molecules (e.g., inulin, horseradish peroxidase) after subarachnoid injection are also distributed in the extracellular fluid and for practical purposes do not cross the BBB [10]. Although such molecules may pass through the astrocytic end feet surrounding the capillary endothelium, they are prevented from entering the lumen of the capillaries by the tight junctions between cells [17]. This is likely to hold for water-soluble contrast media as long as the integrity of the BBB is maintained.

Certain metabolically active molecules such as cycloserine and 2-deoxyglucose are distributed intra- as well as extracellularly [12, 13] after subarachnoid injection. Although the brain distribution of subarachnoid metrizamide is predominantly extracellular [11], deoxyglucose is part of the metrizamide molecule [13]. Therefore, it has been suggested that metrizamide may compete with glucose for

ultimate penetration into the intracellular space [13]. This warrants further consideration.

REFERENCES

1. Sackett JF, Strother CM. *New techniques in myelography*. Hagerstown, MD: Harper & Row, 1979
2. Gonsette RE. Biologic tolerance of the central nervous system to metrizamide. *Acta Radiol [Suppl]* (Stockh) 1973;335:25-44
3. Houghton VM, Ho K, Larson SJ, Unger GF, Correa-Paz F. Comparison of arachnoiditis produced by meglumine iocarmate and metrizamide myelography in an animal model. *AJR* 1978;131:129-132
4. Grainger RG. Technique of lumbar myelography with metrizamide. *Acta Radiol [Suppl]* (Stockh) 1977;355:31-37
5. Conqvist S, Brismar J. Cervical myelography with metrizamide. *Acta Radiol [Suppl]* (Stockh) 1977;355:110-120
6. Sage MR, Benness GT, Perrett LV, Mansfield J. Lumbar myelography today. *Med J Aust* 1981;1:175-176
7. Schmidt RC. Mental disorders after myelography with metrizamide and other water-soluble contrast media. *Neuroradiology* 1980;19:153-157
8. Drayer BP, Rosenbaum AE. Metrizamide brain penetrance. *Acta Radiol [Suppl]* (Stockh) 1977;355:280-293
9. Golman K. Distribution and retention of ¹²⁵I labelled metrizamide after intravenous and sub occipital injection in rabbit, rat and cat. *Acta Radiol [Suppl]* (Stockh) 1973;335:300-311
10. Bradbury MWB. *The concept of a blood-brain barrier*. Chichester NY: Wiley, 1979
11. Winkler SS, Sackett JF. Explanation of metrizamide brain penetrance: a review. *J Comput Assist Tomogr* 1980;4:191-193
12. Oldendorf WH, Davson H. Brain extracellular space and the sink action of the cerebrospinal fluid. *Arch Neurol* 1967;17:196-205
13. Caille JM, Guibert-Trainer F, Howa JM, Billerey J, Calabet A, Piton J. Cerebral penetration following metrizamide myelography. *J Neuroradiol* 1980;7:3-12
14. Dunker RO, Harris AB, Jenkins DP. Kinematics of horseradish peroxidase migration through cerebral cortex. *Brain Res* 1976;118:199-217
15. Cserr HF. Relationship between cerebrospinal fluid and interstitial fluid of brain. *Fed Proc* 1974;33:2075-2078
16. Wilson BC, Evill CA. Correlation of computed tomography and nephrography in quantitative comparison of urographic contrast agents. *Radiology* 1981;140:127-134
17. Bradbury MWB. Why a blood-brain barrier? *Trends Neurosci* 1979;2:36-38