

## ASNR Career Center

The Go-To Job Site for Neuroradiology Employers and Job Seekers  
*Start here: [careers.asnr.org](http://careers.asnr.org)*

# AJNR

## Duvernoy's Atlas of the Human Brain Stem and Cerebellum

*AJNR Am J Neuroradiol* 2009, 30 (5) e75

doi: <https://doi.org/10.3174/ajnr.A1550>

<http://www.ajnr.org/content/30/5/e75>

This information is current as  
of December 9, 2023.

## BOOK REVIEW

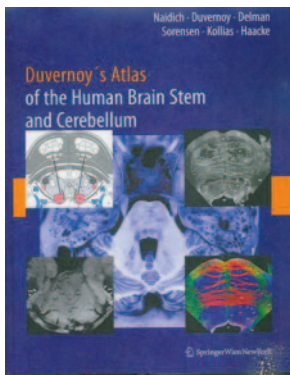
# Duvernoy's Atlas of the Human Brain Stem and Cerebellum

T.P. Naidich, H.M. Duvernoy, B.N. Delman, et al, eds. Springer; 2009, 876 pages, 1000 illustrations, \$439.00.

In a truly remarkable anatomic and MR imaging atlas of the human brain stem and cerebellum, Drs. Thomas Naidich, Henri Duvernoy, Bradley Delman, Gregory Sorensen, Spyros Kollias, and Mark Haacke as editors teamed up with 21 authors to give the neuroscience community a publication that will shortly become a standard in the field of neuroanatomy. The meticulous detail of the ex vivo specimens takes the reader far beyond any previously published work on the MR imaging anatomy of the brain stem, cerebellum, and upper cervical spinal cord. One must see the text firsthand to appreciate the beauty of the specimens and the wealth of knowledge contained in the exact labeling of this complex anatomy. This review attempts to convey to the potential buyer what to expect.

First, understand that we would not carry this text from office to reading station to home. Weighing in at 11 pounds, this 876-page book has used what, to my eye, is the finest paper stock imaginable. The reproductions showing even the smallest of structures are unbelievably crisp; obviously great pains were taken to optimally display the images. The resultant images on a 9.4T system are rightly entitled *MR microscopy*.

After a brief introduction and 2 pages explaining the imaging and staining methods used, the sections that follow in order are surface anatomy of the brain stem, cerebellum, and fourth ventricle; internal architecture of the brain stem; diagrams and descriptions of the brain stem function; structure and function of the cerebellum; structure of the mesencephalic-diencephalic junction; vascularization of the cerebellum and brain stem (diagrams and images); intrinsic vascular territories of the brain stem (here with clinical 1.5T images of infarcts and corresponding diagrams); gray matter nuclei and white matter tracts of the brain stem in formalin fixed



brains (9.4T); cranial nerves (both intra-axial and within the basal cisterns); structural MR imaging (showing neuromelanin, subspecialty-weighted imaging, and diffusion tensor imaging both at 3T in vivo and at 9.4T, formalin fixed); and cross anatomy of the brain stem and cerebellum at 3T in the 3 primary orthogonal planes with use of T1, T2, and constructive interference in steady state imaging.

Many MR imaging atlases are on the market; however, none even come remotely close to showing the detailed structural anatomy available in this publication. Although one could suggest that the detail is too extensive and minute to be of great value to the clinical neuroradiologist, that viewpoint would be shortsighted. As the field moves toward higher and higher field strengths, we undoubtedly will begin to increasingly appreciate the delicate anatomy of the brain stem and cerebellum. Also, an additional observation is that, simply from an intellectual standpoint, anyone who has spent his or her professional life as a neuroradiologist should rejoice in viewing this book and marveling at what can be seen on MR imaging. This book should have wide appeal to everyone in the neurosciences (researchers, neuroanatomists, and clinicians alike). In fact, first-year medical students, who often wonder why they are taught apparently arcane features of the brain stem and the cerebellum, can now have in front of them an atlas that shows that, during their lifetime of practicing medicine, these structures will be visualized in their patients.

I found it simply enjoyable to thumb through the many pages and review the precise and clearly labeled structures, but would I be able to see these finer details tomorrow when I am reviewing cases on a 1.5T or 3T system? The answer is yes for some of them (along with a greater appreciation of their functional connections), but even for those structures that are not discernible, I can now picture where they are and consider what I will be able to see in 10 years. Our field can only hope that Dr. Naidich and his colleagues press forward and extend their exquisite anatomic depictions to the basal ganglia and cerebrum.

I encourage the readers of my review to make it a special point to inspect this book at the next national meeting (American Society of Neuroradiology, Radiological Society of North America, American Association of Neurological Surgeons, American Academy of Neurology), where Springer has its volumes on display. Despite its hefty price tag and hefty weight, I am certain that this book will be selected as a primary reference for any neuroradiology, neurosurgical, or neurology library. It is a classic.

DOI 10.3174/ajnr.A1550