

Extension of “Roller Coaster Dissection” after Tissue Plasminogen Activator

A 40-year-old woman developed a right supraorbital headache after a series of roller coaster rides in a theme park. The headache fluctuated in intensity and was relieved with over-the-counter analgesics. One week later, she developed a sudden-onset left hemiparesis. She was taken to a local hospital, where a head CT finding was normal.

CT angiography findings were consistent with right internal carotid artery (ICA) dissection, with subtle intraluminal irregularity (arrow) suggesting thrombus at the bifurcation of the common carotid artery (Fig 1A, -C). Intravenous tissue plasminogen activator (tPA) was administered 2.5 hours after symptom onset. She was then transferred to our hospital. Diffusion-weighted MR imaging, performed 6 hours after symptom onset, showed acute infarctions in the right hemisphere (Fig 1E). The next day, repeat CT angiography showed extension of the ICA dissection into the common and external carotid arteries, with fresh intraluminal thrombus (arrow, Fig 1B) (Fig 1D). The patient remained stable with no new neurologic deficits. She was administered heparin and then warfarin anticoagulation and was discharged to a rehabilitation hospital after 1 week.

In light of the extension of arterial dissection after tPA administration, a repeat CT/CT angiography was performed 2 weeks after admission. There was no change in the right ICA dissection and no pseudoaneurysm formation, and the infarct had evolved without postischemic hemorrhage. The neurologic deficits improved during the next 5 months of follow-up.

The supraorbital location and nature of our patient’s headache is typical for ICA dissection.¹ The temporal relationship of the headache and subsequent dissection-related stroke to the roller coaster rides sug-

gests a causal link. Roller coaster rides have been associated with carotid and vertebral artery dissections,^{2,3} which are believed to be related to excessive G forces and forceful neck movements during rides. Our patient received intravenous tPA, which is advocated even in the setting of cerebral artery dissection based on anecdotal experience and retrospective analysis.

Georgiadis et al⁴ reported a series of 33 patients who had received intravenous tPA for acute stroke due to spontaneous ICA dissection. None of their patients had new or worsened neurologic deficits, subarachnoid hemorrhage, or pseudoaneurysm. In our patient, serial neurologic examinations showed gradual improvement in function, and brain imaging studies showed evolution of the infarct without postischemic hemorrhage. However, dissection extension in this patient may have occurred as a result of tPA use. It may be prudent to assess extension of dissection and pseudoaneurysm formation in patients with cerebral artery dissection treated with tPA.

References

1. Fisher CM. The headache and pain of spontaneous carotid dissection. *Headache* 1982;22:60–65
2. Biousse V, Chabriat H, Amarenco P, et al. Roller-coaster-induced vertebral artery dissection. *Lancet* 1995;346:767
3. Blacker DJ, Wijndicks EF. A ripping roller coaster ride. *Neurology* 2003;61:1255
4. Georgiadis D, Lanczik O, Schwab S, et al. IV thrombolysis in patients with acute stroke due to spontaneous carotid dissection. *Neurology* 2005;64:1612–14

S.I. Sheikh

A.B. Singhal

Department of Neurology
Massachusetts General Hospital
Boston, Massachusetts

DOI 10.3174/ajnr.A1895

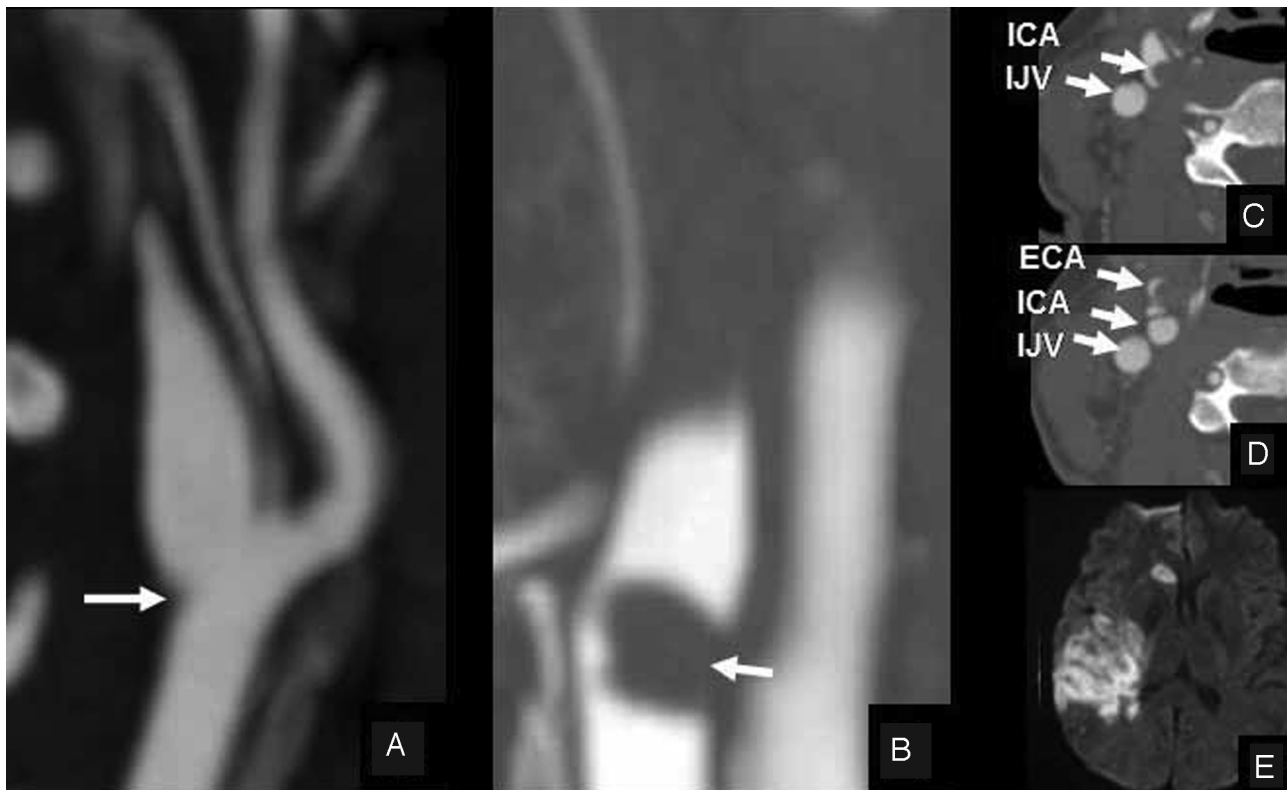


Fig 1. A, Admission CT angiogram shows a flame-shaped tapering occlusion of the right internal carotid artery (ICA), consistent with arterial dissection, with subtle intraluminal irregularity (arrow) suggesting thrombus at the bifurcation of the common carotid artery (CCA). C, Axial image shows the typical crescent sign of arterial dissection at the origin of the ICA and a normal internal jugular vein (IJV). B and D, Follow-up CT angiograms 1 day after intravenous tissue plasminogen activator administration show extension of the dissection into the external carotid artery (ECA) and the CCA and additional intraluminal thrombus in the CCA (arrow, B). E, Diffusion-weighted brain MR imaging shows acute infarcts in the territory of the right internal carotid artery.