



## ASNR Career Center

The Go-To Job Site for Neuroradiology Employers and Job Seekers

Start here: [careers.asnr.org](http://careers.asnr.org)

# AJNR

### **Proton MR Spectroscopy of Progressive Multifocal Leukoencephalopathy–Immune Reconstitution Inflammatory Syndrome**

V. Cuvinciuc, G. Martin-Blondel, B. Marchou and F. Bonneville

This information is current as of December 8, 2023.

*AJNR Am J Neuroradiol* 2010, 31 (8) E69-E70

doi: <https://doi.org/10.3174/ajnr.A2160>

<http://www.ajnr.org/content/31/8/E69>

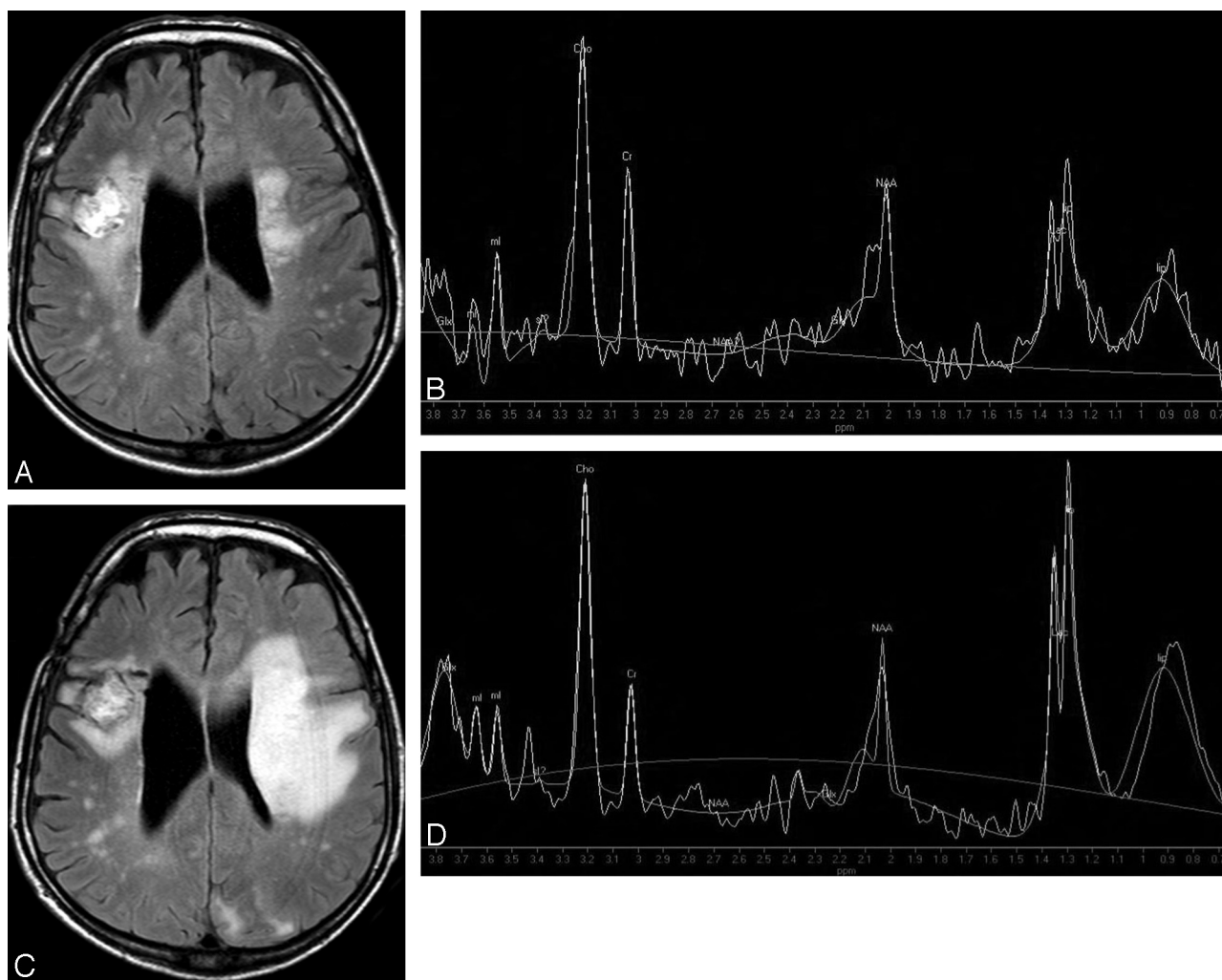
## Proton MR Spectroscopy of Progressive Multifocal Leukoencephalopathy—Immune Reconstitution Inflammatory Syndrome

We read with great interest the article by Bag et al<sup>1</sup> entitled “JC Virus Infection of the Brain.” In this work, the authors dedicated a significant section to the inflammatory forms of progressive multifocal leukoencephalopathy (PML), referred to as PML-immune reconstitution inflammatory syndrome (IRIS). The authors underlined how this diagnosis may be challenging because there is no available biomarker of PML-IRIS and also because the suggestive MR imaging findings of PML-IRIS, namely the onset of contrast enhancement and/or mass effect of white matter T2 hyperintensities, are inconsistently present.<sup>1,2</sup> Thus, proton MR (<sup>1</sup>H-MR) spectroscopy, a technique that studies the metabolism of the brain and lesions in vivo, could be of interest in demonstrating specific modifications in cases of PML-IRIS. However, as Bag et al<sup>1</sup> noticed, while <sup>1</sup>H-MR spectroscopy has already been reported in PML, the literature lacks spectroscopic descriptions of PML-IRIS. Herein, we wanted to briefly report our experience with serial <sup>1</sup>H-MR spectroscopy in a patient with PML-IRIS.

A 48-year-old man was admitted with a right frontal cerebral tox-

oplasmic abscess revealing human immunodeficiency virus-1 (HIV-1) infection. After the abscess was evacuated emergently, MR imaging was performed and showed confluent T2 hyperintensity in the left corona radiata, with no gadolinium uptake, compatible with PML (Fig 1A). Short TE <sup>1</sup>H-MR spectroscopy of the left corona radiata lesion showed a mild elevation of choline (Cho), a diminution of *N*-acetylaspartate (NAA), the presence of lactate (Lac)/lipids at 1.3 ppm, and the presence of myo-inositol (mIns) (Fig 1B). Combined antiretroviral treatment was started. Two months later, the patient developed subacute right hemiplegia, while the HIV load had decreased by >2 log<sub>10</sub> copies/mL. MR imaging showed a marked increase of the left white matter T2 hyperintensity, with mass effect (Fig 1C) and contrast enhancement. Subsequent short and long TE proton spectra showed an additional increase of Cho and Lac/lipid peaks (Fig 1D), compared with the spectrum of PML acquired before combined antiretroviral treatment initiation and immune restoration. Stereotactic brain biopsy further confirmed PML-IRIS.

In conclusion and responding to Bag et al,<sup>1</sup> we report a case of paradoxical PML-IRIS with serial MR spectroscopy features consistent with an increased inflammatory response. While the elevation of the mIns/creatine ratio has been shown to be associated with better sur-



**Fig 1.** A, Fluid-attenuated inversion recovery (FLAIR) axial image shows high signal intensity in the left corona radiata, compatible with PML. Note the right frontal postsurgical appearance after evacuation of a cerebral abscess. B, Short TE spectroscopy shows increased Cho, free lipids (and/or Lac), and diminished NAA. C, After 2 months of treatment, with adapted biologic response but paradoxical clinical worsening, axial FLAIR image reveals an enlargement of the left T2 hyperintensity with obvious mass effect on the ipsilateral ventricle. D, Short TE spectroscopy shows further increase in Cho, Lac, and free lipid peaks (long TE not shown). Glx indicates glutamine/glutamate; lip, lipid; ml, myo-inositol.

vival rates in patients with PML,<sup>3</sup> we propose that serial spectroscopy could be a diagnostic marker of PML-IRIS, deserving further study.

## References

1. Bag AK, Cure JK, Chapman PR, et al. **JC virus infection of the brain.** *AJNR Am J Neuroradiol* 2010 Mar 18. [Epub ahead of print]
2. Tan K, Roda R, Ostrow L, et al. **PML-IRIS in patients with HIV infection: clinical manifestations and treatment with steroids.** *Neurology* 2009;72:1458–64
3. Katz-Brull R, Lenkinski RE, Du Pasquier RA, et al. **Elevation of myoinositol is associated with disease containment in progressive multifocal leukoencephalopathy.** *Neurology* 2004;63:897–900

V. Cuvinciu  
Neuroradiology Department  
University Hospital  
Toulouse, France  
and  
Neuroradiology Department  
University Hospital  
Grenoble, France

DOI 10.3174/ajnr.A2160

G. Martin-Blondel  
*Infectious and Tropical Diseases Department*  
University Hospital  
Toulouse, France  
and  
INSERM U563  
Toulouse, France  
B. Marchou  
*Infectious and Tropical Diseases Department*  
University Hospital  
Toulouse, France  
F. Bonneville  
*Neuroradiology Department*  
University Hospital  
Toulouse, France