This information is current as of October 12, 2024.

Transient Focal Neurologic Symptoms Correspond to Regional Cerebral Hypoperfusion by MRI: A Stroke Mimic in Children

L.L. Lehman, A.R. Danehy, C.C. Trenor III, C.F. Calahan, M.E. Bernson-Leung, R.L. Robertson and M.J. Rivkin

AJNR Am J Neuroradiol 2017, 38 (11) 2199-2202
doi: https://doi.org/10.3174/ajnr.A5296
http://www.ajnr.org/content/38/11/2199

Transient Focal Neurologic Symptoms Correspond to Regional Cerebral Hypoperfusion by MRI: A Stroke Mimic in Children

L.L. Lehman, A.R. Danehy, C.C. Trenor III, C.F. Calahan, M.E. Bernson-Leung, R.L. Robertson, and M.J. Rivkin

ABSTRACT

SUMMARY: Children who present with acute transient focal neurologic symptoms raise concern for stroke or transient ischemic attack. We present a series of 16 children who presented with transient focal neurologic symptoms that raised concern for acute stroke but who had no evidence of infarction and had unilateral, potentially reversible imaging features on vascular and perfusion-sensitive brain MR imaging. Patients were examined with routine brain MR imaging, MRA, perfusion-sensitive sequences, and DWI. Fourteen (88%) children had lateralized MRA evidence of arterial tree pruning without occlusion, all had negative DWI findings, and all showed evidence of hemispheric hypoperfusion by susceptibility-weighted imaging or arterial spin-labeling perfusion imaging at presentation. These findings normalized following resolution of symptoms in all children who had follow-up imaging (6/16, 38%). The use of MR imaging with perfusion-sensitive sequences, DWI, and MRA can help to rapidly distinguish children with conditions mimicking stroke from those with acute stroke.

Children who present with sudden onset of focal neurologic symptoms raise concern for acute stroke and transient ischemic attack. Yet certain conditions, such as complex migraine, postictal hemiparesis, or conversion disorder, can imitate acute stroke and are considered "stroke mimics." Patients with stroke mimics present with an acute onset of focal neurologic symptoms but, on further evaluation, do not have an infarction or hemorrhage. Rapid differentiation of a stroke mimic from a cerebrovascular emergency constitutes a critically important diagnostic step before the initiation of time-dependent treatment such as thrombolysis or thrombectomy. Neuroimaging and MR imaging, in particular, provide essential information in the diagnosis of stroke.[1-3] Diffusion imaging documents irreversible tissue infarction.[1] Arterial spin-labeling and susceptibility-weighted imaging provide information on regional differences in brain perfusion, which can include the core infarct but also encompass tissue beyond it that is hypoperfused but not yet irreversibly infarcted.[2,4] MRA, which is based on flow-related enhancement, is used for documentation of vascular attenuation or obstruction consistent with both a patient's clinical symptoms and core infarct location.[3]

We report a case series of 16 children with transient neurologic symptoms who had unilateral cerebral hypoperfusion and lateralized vascular pruning without associated diffusion abnormalities by MR imaging. The resolution of neurologic symptoms without stroke-specific intervention and the normalization of the initial MR imaging features in patients with follow-up imaging confirm this clinicoradiologic entity as a stroke mimic. Recognition of these imaging patterns may help distinguish true stroke requiring urgent intervention from a stroke mimic condition in children presenting acutely with focal neurologic symptoms.[5]

CASE SERIES

Cases were collected retrospectively as part of a larger, institutional review board–approved review of children with transient neurologic symptoms presenting to a free-standing children's hospital. A total of 16 children met both the clinical criteria of transient focal neurologic symptoms and the imaging criteria of focal hypoperfusion and/or focal vascular pruning. We collected clinical information on each of the children, including symptoms at presentation, time from presentation to imaging, headache at presentation, and history of migraines. All clinical information was reviewed by a pediatric neurologist.

Clinical Features

Our cohort of 16 children included 6 females (38%). The children ranged from 2 to 16 years of age. Among the 16 children, 13 (81%) had headache at presentation. Only 6 (38%) had a previous diagnosis of migraine (Table 1). Most patients (94%) did not meet the International Classification of Headache Disorders criteria for

Received January 30, 2017; accepted after revision May 9.

From the Stroke and Cerebrovascular Center (L.L.L., A.R.D., C.C.T., C.F.C., M.E.B.-L., M.J.R.), Departments of Neurology (L.L.L., C.F.C, M.E.B.-L., M.J.R.), Psychiatry (M.J.R), Radiology (A.R.D., R.L.R., M.J.R.), and Division of Hematology/Oncology (C.C.T.), Boston Children's Hospital, Harvard Medical School, Boston, Massachusetts.

R.L. Robertson and M.J. Rivkin are co-senior authors.

Please address correspondence to Richard Robertson, MD, Boston Children's Hospital, 300 Longwood Ave, Main 2, Boston, MA 02115; e-mail: richard.robertson@childerns.harvard.edu

http://dx.doi.org/10.3174/ajnr.A5296

Table 1: Clinical details of the presentation of the children

Patient No.	Age (yr)	Sex	Headache	History of Migraine Headache	Time from Presentation to Imaging	Clinical Symptoms
1	15	Female	Yes	Yes	4.5 hr	Right face and arm weakness, hypoesthesia, hemianopia, aphasia
2	13	Male	Yes	No	5.5 hr	Left face and hand paresthesia
3	16	Female	Yes	No	6.75 hr	Left hand and foot paresthesia and weakness
4	14	Male	Yes	Yes	4.5 hr	Aphasia, right hemianopia
5	2	Male	No	No	<12 hr	Right hemiparesis and hemianopia
6	12	Female	Yes	Yes	6 hr	Aphasia
7	13	Male	Yes	No	4.25 hr	Aphasia and right face and arm weakness
8	8	Male	Yes	No	11 hr	Aphasia, bilateral blurry vision, left hand paresthesia
9	10	Male	Yes	No	6 hr	Right hand paresthesia, confusion
10	11	Female	No	Yes	<1 hr	Right hand paresthesia
11	5	Male	No	No	4 hr	Right hemiparesis, dysarthria, and confusion
12	13	Female	Yes	No	7.5 hr	Left hand weakness and paresthesia, aphasia
13	8	Male	Yes	Yes	16.25 hr	Left facial weakness, hemiparesis
14	15	Male	Yes	Yes	10.5 hr	Aphasia
15	10	Male	Yes	No	8.5 hr	Aphasia and blurry vision
16	4	Female	Yes	No	<16 hr	Left facial weakness, dysarthria

hemiplegic migraine.[6] All patients had complete resolution or marked improvement in symptoms by 24 hours after symptom onset. Only 6 (38%) had recurrence of transient neurologic symptoms since the initial presentation; none had stroke at the time of presentation or at follow-up. We had a median follow-up of 0.7 years with a range of 1 day to 3.4 years.

Imaging Approach and Features

MR imaging was performed at a median of 6.4 hours, with all patients imaged within 16.5 hours of presentation. All examinations were performed on a 3T Magnetom Skyra or Trio imaging system (Siemens, Erlangen, Germany) with a 32- or 64-channel head coil. All patients were examined with the standard institutional brain imaging sequences, including the following: sagittal T1 MPRAGE (TR = 1520–2530 ms, TE = 1.63–3.39 ms, section thickness = 0.90–1 mm, echo-train length = 1, matrix = 220–256/220–256, one or 4 excitations); axial fast spin-echo T2 (TR = 4400–14,143 ms, TE = 89–100 ms, section thickness = 2.5 mm, echo-train length = 13–19, matrix = 269–359/512, two-to-three excitations); axial T2 FLAIR (TR = 6800–9000 ms, TE = 135–137 ms, section thickness = 4 mm, echo-train length = 13–16, matrix = 250–320/320, one-to-two excitations); diffusion tensor imaging with 30 or 35 directions, b=1000 s/mm^2 (TR = 5300–13,800 ms, TE = 88–92 ms, section thickness = 2–4 mm, echo-train length = 1,48, or 51, matrix = 128/128, one excitation); and 3D time-of-flight angiography (TR = 21–22 ms, TE = 3.43–3.88 ms, section thickness = 0.60–0.80 mm, echo-train length = 1, matrix = 230–344/384–512, one excitation). Perfusion-sensitive sequences, including perfusion-weighted pulsed arterial spin-labeling (n = 11 patients: TR = 2500–5000 ms, TE = 11–35 ms, section thickness = 3–5 mm, echo-train length = 1–51, matrix = 64–96/64–84, one-to-sixty excitations, TI = 700 ms); velocity-selective arterial spin-labeling (n = 2 patients: TR = 3000 ms, TE = 13 ms, section thickness = 5 mm, matrix = 64/64, one excitation, TI_1 = 700 ms, $TI_{1,stop}$ = 1400 ms, and TI_2 = 2000 ms [to the center section]); and axial susceptibility-weighted imaging (n = 16 patients: TR = 28 ms, TE = 20 ms, section thickness = 1.25 mm, echo-train length = 1, matrix = 184–336/256–384, one excitation) were also performed.

Images were independently reviewed by 2 pediatric neuroradiologists. The final interpretation was reached by consensus in cases of disagreement between the reviewers. Each MR imaging examination was evaluated for the following imaging abnormalities: linear sulcal signal abnormality on FLAIR imaging, subcortical hypointensity on T2-weighted imaging, localized brain parenchymal signal or diffusion abnormalities, gyral swelling, venous prominence on susceptibility-weighted imaging, perfusion abnormality on arterial spin-labeling, abnormal leptomeningeal and parenchymal enhancement following the administration of intravenous contrast, and evidence of increased/decreased flow-related enhancement or vessel stenosis on 3D TOF MR angiography. Imaging abnormalities were further characterized according to vascular distribution for MRA and lobes of the brain involved in SWI and arterial spin-labeling.

DWI revealed no areas of decreased diffusivity in any patient. None had evidence of gyral swelling. Linear sulcal signal abnormality in the hemodynamically affected region was seen on FLAIR imaging in 2 patients (2/16, 13%). One patient had subcortical hypointensity on T2-weighted imaging (1/16, 6%). All 16 patients had unilateral increased prominence of the cortical or medullary veins in ≥1 cerebral lobe on SWI, suggesting elevated venous deoxyhemoglobin, indicative of hypoperfusion. Of the 11 patients evaluated with arterial spin-labeling, decreased perfusion to ≥1 lobe of the brain was evident in all. Diminished flow-related enhancement due to decreased hemispheric flow in at least 1 branch vessel of the circle of Willis was evident in 14 patients (14/16, 88%). Multivessel unilateral vascular pruning was present in 9 patients. None of the patients demonstrated hemodynamic change in the posterior fossa structures. Arterial beading on MRA was not demonstrated in any patient. Intravenous contrast was administered in 3 patients (3/16, 19%) with increased leptomeningeal prominence seen in the regions corresponding to those with arterial spin-labeling, SWI, and MRA changes in all 3. No parenchymal enhancement was observed in any of the 3 patients administered contrast. The Figure represents an example of the imaging findings observed in our cohort. Follow-up imaging was performed in 6 patients (6/16, 38%). Resolution of MR imaging changes, including normalization of arterial spin-labeling, SWI, and MRA findings, was observed in all 6 patients who had follow-up imaging (Table 2).

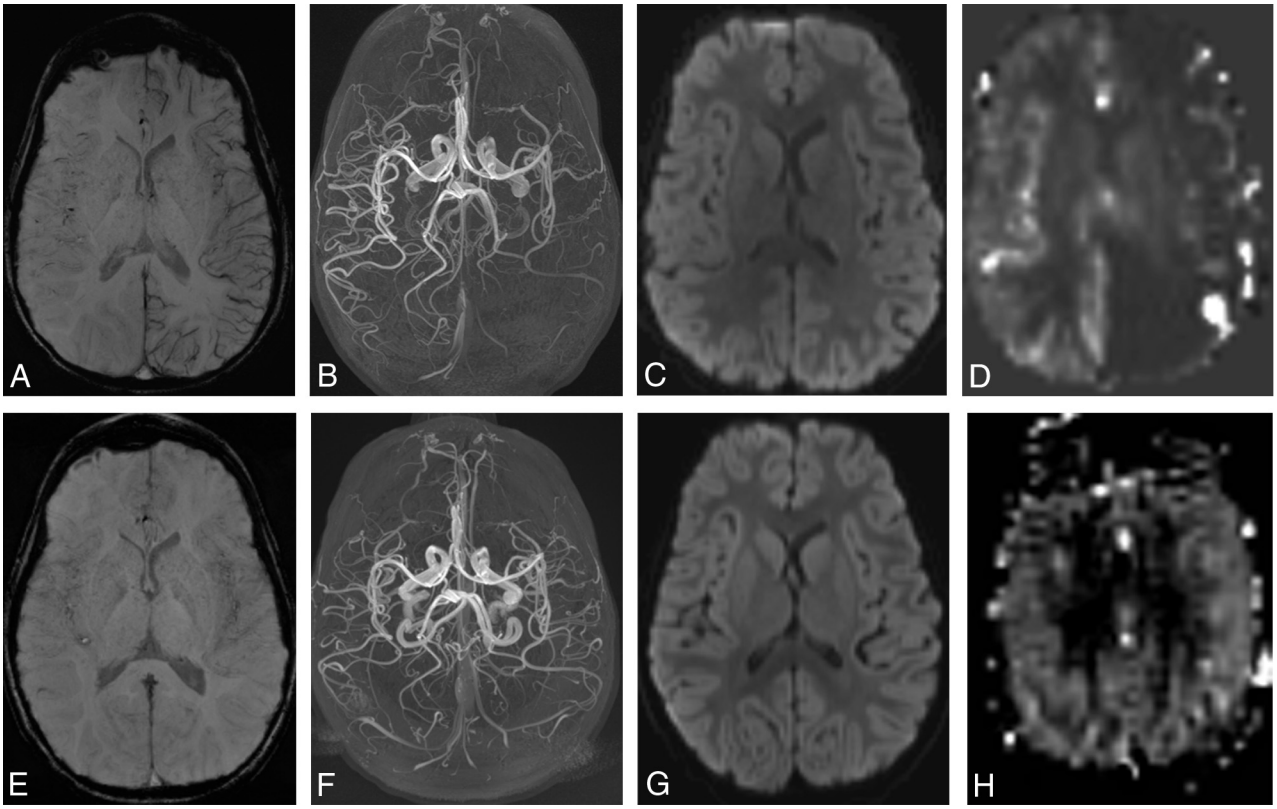

FIGURE. A 5-year-old boy presenting with right-sided weakness. Symptoms were improving at the time of the initial MR imaging performed 3 hours after presentation (*A–D*). *A*, Susceptibility-weighted imaging shows increased prominence of the cortical veins throughout the left cerebral hemisphere, indicating increased deoxyhemoglobin on the left. *B*, Collapsed maximum intensity projection from time-of-flight MR angiography shows reduced flow-related enhancement in the left anterior, middle, and posterior cerebral arteries. *C*, The average trace of the diffusion tensor image shows no abnormality of diffusion. *D*, Pulsed arterial spin-labeled perfusion-weighted imaging relative CBF map shows a marked decrease in perfusion throughout the left cerebral hemisphere. Follow-up imaging at 4 days after presentation (*E–H*). *E*, SWI shows resolution of venous asymmetry. *F*, MRA shows normal flow-related enhancement in the left anterior, middle, and posterior cerebral arteries. *G*, Findings of the average trace image continue to be negative. *H*, Pulsed arterial spin-labeling relative CBF map shows resolution of perfusion asymmetry.

Table 2: Radiology findings of children with ASL and SWI reported in lobes and MRA in vessels involved

Patient No.	Side	pASL (Decrease)	vASL (Decrease)	SWI (Increase)	MRA (Decrease)	Resolution
1	Left	P/T/O	ND	F/P/T/O	MCA/PCA	ND
2	Left	P/T	ND	P/T	MCA	Yes
3	Right	P	ND	P	MCA	ND
4	Left	P/T/O	ND	P/T/O	None	Yes
5	Left	F/P/T/O	ND	F/P/T/O	ACA/MCA/PCA	Yes
6	Left	F/P/T/O	Left F/P/O/T	F/P/T/O	ACA/MCA/PCA	ND
7	Left	F/T	ND	F/T	MCA	ND
8	Left	P/T	ND	P/T	None	ND
9	Left	F/P/T/O	ND	F/P/T/O	ACA/MCA	ND
10	Left	ND	ND	P/T/O	MCA/PCA	ND
11	Left	F/P/T/O	ND	F/P/T/O	ACA/MCA/PCA	Yes
12	Right	F/P/T/O	ND	F/P/T/O	ACA/MCA/PCA	Yes
13	Right	ND	Right P/O/T	P/T/O	MCA/PCA	Yes
14	Left	ND	ND	F/P/T/O	MCA/PCA	ND
15	Left	ND	ND	F/P	MCA	ND
16	Left	ND	ND	P/T/O	MCA	ND

Note:—pASL indicates pseudocontinuous arterial spin-labeling; vASL, velocity-selective arterial spin-labeling; ND, study not done; F, frontal; P, parietal; T, temporal; O, occipital; ACA, anterior cerebral artery; PCA, posterior cerebral artery.

DISCUSSION

We describe a cohort of children with a specific radiologic presentation that included negative diffusion-weighted imaging findings, evidence of lobar or hemispheric hypoperfusion by susceptibility-weighted imaging, and/or arterial spin-labeled perfusion imaging associated with transient focal neurologic symptoms. MRA evidence of arterial pruning without occlusion was usually present. In all children who had repeat imaging, the vascular and perfusion findings had normalized and there was no evidence of infarction. Most children had headache at presentation, and only

one-third had recurrence of symptoms. Most interesting, only 1 of the children met the International Classification of Headache Disorders criteria for hemiplegic migraine.[5,6]

The literature describing the neuroimaging findings in children with transient focal neurologic symptoms is limited. Imaging findings of focal hypoperfusion and vascular pruning have been reported previously in pediatric and adult patients with hemiplegic migraine (genetically proved or clinically diagnosed) in case reports and small case series.[7-9] Perfusion findings have been reported and are temporally variable in children with acute onset of migraine with an aura. In a case-control study, 10 patients with migraine with an aura were acutely imaged with arterial spin-labeled perfusion imaging and found to have a change in perfusion compared with controls. The children had decreased perfusion if scanned <14 hours from the onset of symptoms, while evidence of increased perfusion was found if imaging was performed at >17 hours from symptom onset.[10] In addition, Safier et al[11] reported a series of 8 children with hemiplegic migraine who demonstrated vascular narrowing by MRA. However, in their case series, only the middle cerebral artery was examined.[11] The study by Safier et al did not report on the other branch vessels of the circle of Willis. Consequently, it is not certain whether the vascular changes occurred in only the middle cerebral artery in their patients or if other vessels were similarly affected but not evaluated as part of the study. In our patient cohort, several branch vessels were usually affected.

Children who present with the acute onset of focal neurologic symptoms raise concern for stroke. Rapid neuroimaging of these children is extremely important, given the availability of treatment with thrombolysis or endovascular thrombectomy for acute stroke. DWI permits differentiation of a stroke from a stroke mimic.[5] While negative DWI excludes an infarction requiring acute stroke therapy, the addition of perfusion-sensitive imaging in patients with diffusion-negative transient neurologic deficits can provide additional information regarding the etiology of the neurologic symptoms. Our findings indicate that a subset of children with symptoms mimicking acute stroke lack the anatomic or diagnostic diffusion-related changes of infarction but exhibit perfusion and flow-related vascular changes indicating reduced regional perfusion as a cause of symptoms. All children in our cohort with anatomic- and DWI-negative but perfusion-positive imaging findings demonstrated decreased rather than increased regional perfusion. The decreased perfusion findings in these children help to differentiate symptoms due to an ischemic cause from other conditions that may mimic stroke, such as a postictal state that typically shows increased regional blood flow.[12-14]

We recognize limitations in our study. Our series is retrospective in nature and small in number. Furthermore, only a portion of the children we report had repeat imaging following resolution of symptoms. Finally, we have only limited outcome information.

CONCLUSIONS

The use of combined MR imaging to include perfusion-sensitive, diffusion-weighted, and angiographic imaging can help to rapidly distinguish children who present with stroke mimics whose symptoms are likely to be transient and who do not require stroke treatment from those with an acute stroke. In our series, the imaging findings of unilateral, often multilobar, hypoperfusion and arterial vascular pruning without evidence of diffusion restriction in a child presenting with focal neurologic symptoms reflect a benign stroke mimic and confirm a vasoconstrictive basis for the patient's symptoms. Our observations support the routine use of perfusion-sensitive sequences as part of the neuroimaging evaluation of any child presenting with stroke or strokelike symptoms.

Disclosures: Richard L. Robertson—*UNRELATED*: *Other*: GE Healthcare*. *Money paid to the institution.

REFERENCES

1. Schellinger PD, Bryan RN, Caplan LR, et al; Therapeutics and Technology Assessment Subcommittee of the American Academy of Neurology. **Evidence-based guideline: the role of diffusion and perfusion MRI for the diagnosis of acute ischemic stroke—report of the Therapeutics and Technology Assessment Subcommittee of the American Academy of Neurology.** *Neurology* 2010;75:177–85 CrossRef Medline
2. Haacke EM, Mittal S, Wu Z, et al. **Susceptibility-weighted imaging: technical aspects and clinical applications, part 1.** *AJNR Am J Neuroradiol* 2009;30:19–30 Medline
3. Wintermark M, Sanelli PC, Albers GW, et al; American Society of Neuroradiology, American College of Radiology, Society of Neuro-Interventional Surgery. **Imaging recommendations for acute stroke and transient ischemic attack patients: a joint statement by the American Society of Neuroradiology, the American College of Radiology and the Society of NeuroInterventional Surgery.** *J Am Coll Radiol* 2013;10:828–32 CrossRef Medline
4. Zaharchuk G, Olivot JM, Fischbein NJ, et al. **Arterial spin labeling imaging findings in transient ischemic attack patients: comparison with diffusion- and bolus perfusion-weighted imaging.** *Cerebrovasc Dis* 2012;34:221–28 CrossRef Medline
5. Rivkin MJ, deVeber G, Ichord RN, et al. **Thrombolysis in pediatric stroke study.** *Stroke* 2015;46:880–85 CrossRef Medline
6. Headache Classification Committee of the International Headache Society (IHS). **The International Classification of Headache Disorders, 3rd edition (beta version).** *Cephalalgia* 2013;33:629–808 CrossRef Medline
7. Bosemani T, Burton VJ, Felling RJ, et al. **Pediatric hemiplegic migraine: role of multiple MRI techniques in evaluation of reversible hypoperfusion.** *Cephalalgia* 2014;34:311–15 CrossRef Medline
8. Kim S, Kang M, Choi S. **A case report of sporadic hemiplegic migraine associated cerebral hypoperfusion: comparison of arterial spin labeling and dynamic susceptibility contrast perfusion MR imaging.** *Eur J Pediatr* 2016;175:295–98 CrossRef Medline
9. Fedak EM, Zumberge NA, Heyer GL. **The diagnostic role for susceptibility-weighted MRI during sporadic hemiplegic migraine.** *Cephalalgia* 2013;33:1258–63 CrossRef Medline
10. Boulouis G, Shotar E, Dangouloff-Ros V, et al. **Magnetic resonance imaging arterial-spin-labelling perfusion alterations in childhood migraine with atypical aura: a case-control study.** *Dev Med Child Neurol* 2016;58:965–69 CrossRef Medline
11. Safier R, Cleves-Bayon C, Vaisleib I, et al. **Magnetic resonance angiography evidence of vasospasm in children with suspected acute hemiplegic migraine.** *J Child Neurol* 2014;29:789–92 CrossRef Medline
12. Kim BS, Lee ST, Yun TJ, et al. **Capability of arterial spin labeling MR imaging in localizing seizure focus in clinical seizure activity.** *Eur J Radiol* 2016;85:1295–303 CrossRef Medline
13. Matsuura K, Maeda M, Okamoto K, et al. **Usefulness of arterial spin-labeling images in periictal state diagnosis of epilepsy.** *J Neurol Sci* 2015;359:424–29 CrossRef Medline
14. Verma RK, Abela E, Schindler K, et al. **Focal and generalized patterns of cerebral cortical veins due to non-convulsive status epilepticus or prolonged seizure episode after convulsive status epilepticus: A MRI study using susceptibility-weighted imaging.** *PLoS One* 2016; 11:e0160495 CrossRef Medline