

Are your **MRI contrast agents** cost-effective?

Learn more about generic **Gadolinium-Based Contrast Agents**.



FRESENIUS
KABI

caring for life

AJNR

Clinical application of digital tomosynthesis: a preliminary report.

K R Maravilla, R C Murry, M Deck and S Horner

AJNR Am J Neuroradiol 1983, 4 (3) 277-280

<http://www.ajnr.org/content/4/3/277>

This information is current as
of April 19, 2024.

Clinical Application of Digital Tomosynthesis: A Preliminary Report

Kenneth R. Maravilla,¹ Robert C. Murry, Michael Deck, and Sherye Horner

Digital tomosynthesis represents a new technique for digital manipulation of data acquired during a single tomographic sweep. With the aid of a computer, data can be processed to yield images in any parallel plane of the body. This technique allows rapid tomographic studies requiring a much lower radiation dose to the patient. Dynamic studies such as angiotomography are feasible, and application to digital subtraction intravenous angiography is also possible with this technique. Early experience with clinical application in patient studies is presented.

In 1971 Miller et al. [1] described a method for producing an infinite number of tomograms from a finite set of radiographic images. Subsequently, Baily et al. [2-4] adapted these principles to an electronic display system using a fluoroscope and an electronic storage tube for synthesis and display of images in different planes. At the University of Texas Health Science Center in Dallas we have assembled a digital image processing system which is capable of synthesizing tomograms of any desired plane within an object from raw data acquired during a single tomographic sweep. We call this technique digital tomosynthesis (DTS).

In other reports [5-7] we have described the details of our system, and we have evaluated the feasibility of this technique with various phantom studies. The potential for clinical application of DTS has also been determined from animal studies. In our early studies the quality of the computer-synthesized tomographic image was shown to be comparable to the actual, nonsynthesized tomographic image, and was more than sufficient to yield diagnostic quality information. Since those initial studies we have modified our system and refined our computer programs to allow DTS studies to be performed on patients in our clinical x-ray department. This report presents our early experience with clinical studies using the DTS technique.

Materials and Methods

The system used in our x-ray department consists of a standard x-ray apparatus that can perform conventional linear tomography and has an integrated image intensifier and television system. Real-time (30 frames/sec) video images from the fluoroscopic television system are acquired during a tomographic sweep, and these images are stored on an analog video disk recorder. The stored images are later recalled for postprocessing using a digitizer and a computer to reconstruct tomographic pictures for any desired cut plane within

the body. The tomosynthesis algorithms used for image generation are currently implemented using an LSI-11 computer system in conjunction with a high-speed arithmetic processor. Reconstruction times range from about 10-30 sec depending on the image parameters chosen. The resulting reconstructed image is stored in a digital video memory with a 512×512 matrix and is displayed on a television monitor. Capabilities for window and level manipulations of the displayed image and for programs that allow for subtraction of the image are an integral part of our system. A more complete description of the principles of operation and the system architecture is described elsewhere [7].

Representative Case Reports

Case 1

A 54-year-old woman was admitted to the emergency room with neck pain following an automobile accident. Plain films revealed considerable degenerative change throughout the cervical spine. Although no fracture was seen, a 2 mm subluxation was present at the C3-C4 level. Flexion and extension views of the cervical spine were done using the DTS technique. In the flexion view (figs. 1A and 1B) the actual tomographic plane (or zero (0) plane) was centered at the midline and defined the 2 mm subluxation at the bodies of C3-C4. Synthesis of a tomographic plane 1.5 cm to the left of the midline clearly defined the articular facets, and a large degenerative spur on the posterior aspect of the superior articular facet of C4 was noted. In the extension position (figs. 1C and 1D) the midline plane is now best defined on the DTS image reconstructed 8 mm to the right of the 0 plane. This shows persistence of the 2 mm subluxation. The DTS image 8 mm to the left of 0 again shows the degenerative spur formation, which prevents complete reduction of the facets at C3-C4 with the patient's spine in extension. Polytomograms were obtained and confirmed the findings described on the tomosynthesized images.

Comment: Flexion and extension views of patients with suspected spine abnormalities are often obtained using either plain film technique or a single midline tomogram. The DTS technique in this case not only provided the information usually obtained with conventional flexion-extension views, but also provided additional information through retrospective reconstruction of a tomographic plane at the level of the articular facets. This established the diagnosis of a nonreducible subluxation and enabled us to determine the reason for this fixed defect—namely, the degenerative spurring of the facet joints. This case illustrates another advantage of DTS in that, in the

¹All authors: Department of Radiology, University of Texas Health Science Center at Dallas, 5323 Harry Hines Blvd., Dallas, TX 75235. Address reprint requests to K. R. Maravilla.

extension view, the attempted midline tomogram was not obtained at the proper level but rather was inadvertently sectioned off to the left side. Nevertheless, the true midline of the spine was readily obtained by tomosynthesis of an image 8 mm to the right of 0 plane.

Case 2

A 41-year-old woman was admitted to the hospital after an acute subarachnoid hemorrhage. Computed tomography (CT) showed subarachnoid blood in the left side of the suprasellar cistern and the left sylvian fissure. A cerebral arteriogram revealed an aneurysm

arising near the bifurcation of the left internal carotid artery. A lateral angiogram using DTS technique (fig. 2) was obtained after injection into the left common carotid artery. This showed the aneurysm to arise from the left internal carotid artery at the origin of the posterior communicating artery. A plane 3 cm to the left defined a small, localized area of spasm in a branch of the middle cerebral artery that was not detected on the conventional arteriographic study due to overlap of vessels. At surgery the location of the aneurysm at the posterior communicating artery was confirmed and the neck was clipped without difficulty.

Comment: DTS images in different sagittal planes of the head clearly show different parts of the intracranial vasculature. This

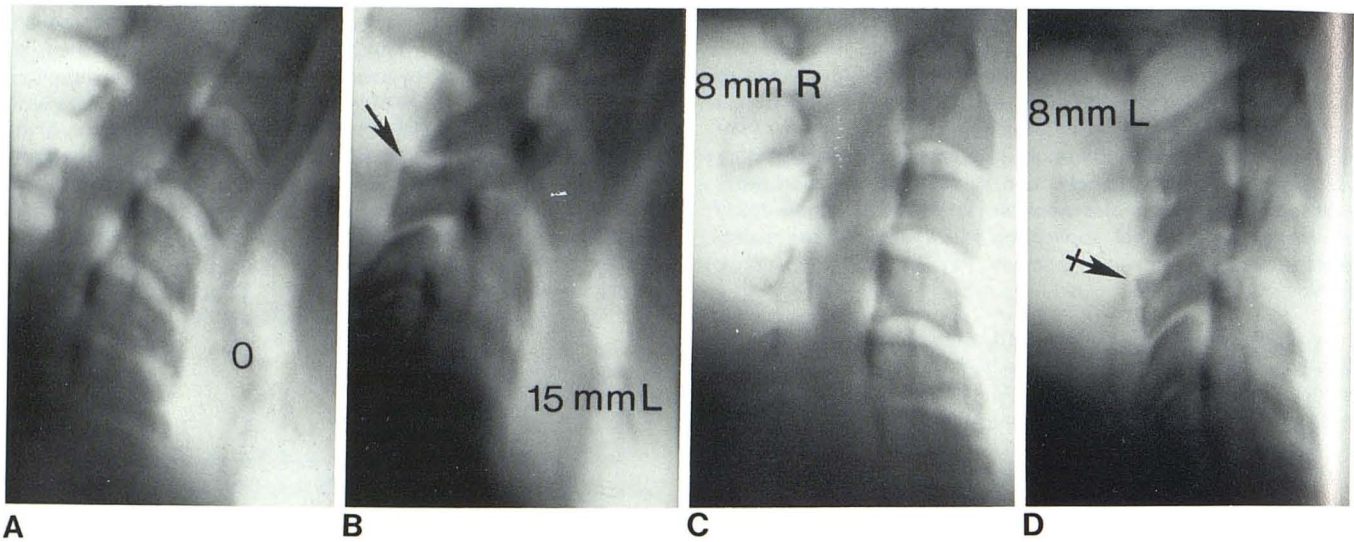


Fig. 1.—Flexion and extension views of cervical spine. **A**, 0 plane of flexion view centered in midline of cervical spine shows 2 mm subluxation of C3 on C4. Marked degenerative changes within vertebral bodies of lower cervical spine. **B**, Tomosynthesized image 15 mm to left of 0 plane clearly shows lateral masses and articular facets. Prominent degenerative spur (arrow) at superior facet of C4. **C**, With patient repositioned in extension, 0 plane of tomogram was inadvertently centered to left of midline. Nonetheless,

true midline of cervical spine was visualized by reconstructing plane 8 mm to right of 0 plane. The 2 mm subluxation at C3–C4 is again noted essentially unchanged when compared with flexion view. **D**, Tomosynthesized image 8 mm to left of 0 (16 mm to left of midline in 1C) shows relation of lateral masses and articular facets. Degenerative spur (arrow) on superior facet of C4 (which prevents complete reduction of these facets) is again seen.

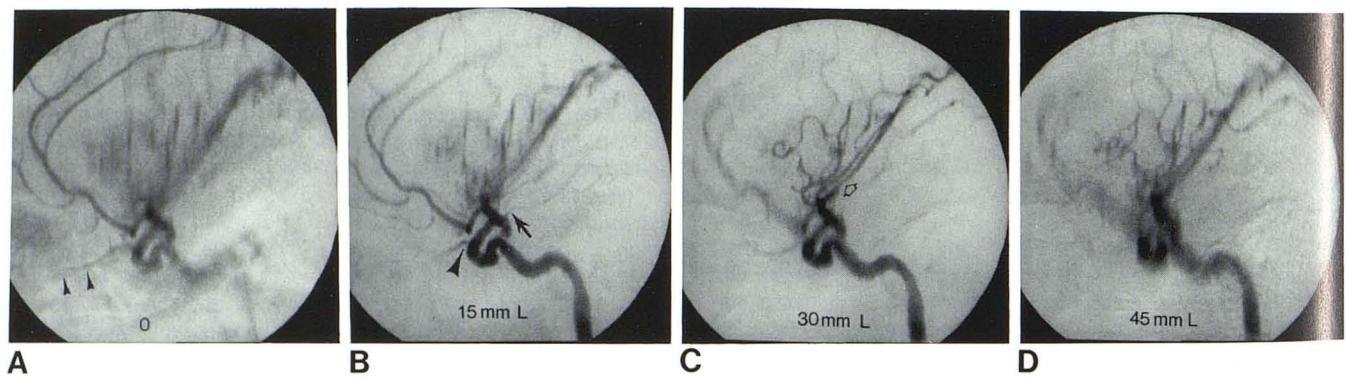


Fig. 2.—Multiple reconstructed views of angiogram after contrast injection into left common carotid artery. **A**, 0 plane lies at midline of head and clearly defines anterior cerebral, pericallosal, and callosomarginal arteries. Intraorbital part of ophthalmic artery (arrowheads) is clearly seen. **B**, Digital tomosynthesis image reconstructed 15 mm to left of 0 plane clearly defines aneurysm and its neck. Note relation with posterior communicating artery (arrow), which indicates site of origin for this aneurysm. Origin of ophthalmic artery (arrowhead) from internal carotid artery is also clearly

defined. **C**, DTS image 30 mm to left of midsagittal plane clearly shows insular loops of middle cerebral artery. Intrasyllian parts of middle cerebral artery are well shown, and small, localized area of spasm (arrow) is seen. This area of spasm was missed on conventional arteriogram because region was partly obscured by overlapping vessels. **D**, DTS image 45 mm to left of midsagittal plane shows peripheral branches of middle cerebral artery as they ascend and descend over cerebral convexity.

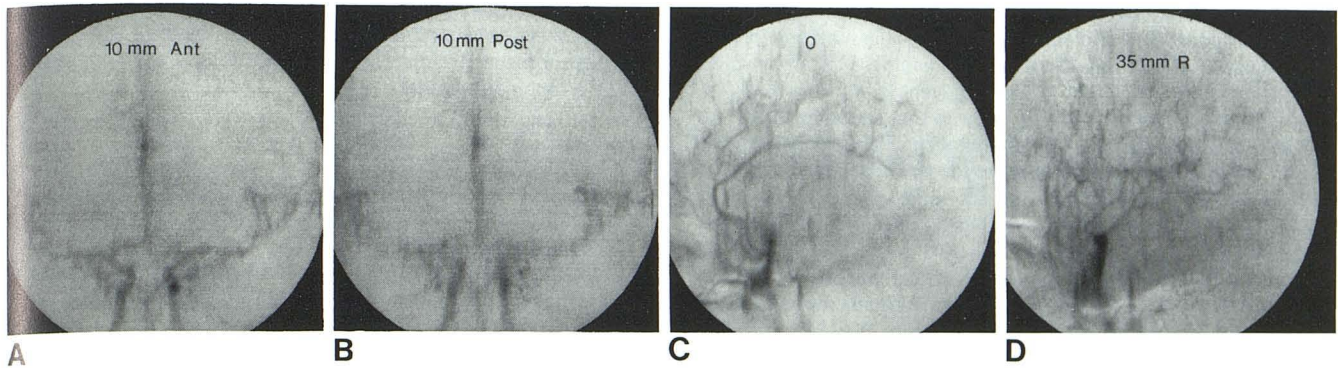


Fig. 3.—Digital tomosynthesis images of an angiogram following intravenous injection of contrast material. **A**, AP view reconstructed 10 mm anterior to 0 plane clearly shows internal carotid bifurcations on both sides together with the A1 segments of anterior cerebral arteries and M1 segments of middle cerebral arteries. **B**, Plane reconstructed 10 mm posterior to 0 plane shows middle cerebral arteries within sylvian fissures together with opercular branches of middle cerebral arteries on both sides. **C**, Digital

tomosynthesis image taken in lateral view shows 0 plane centered at midsagittal position. Anterior cerebral artery and its branches in interhemispheric fissure are well shown. **D**, Reconstructed plane 35 mm to right of 0 shows branches of right middle cerebral artery are unobscured by anterior cerebral artery branches or middle cerebral artery branches from opposite side. This case best shows potential of this technique for selective visualization of different vascular segments unobscured by superimposed vessels.

study is important in illustrating the quality of the DTS angiographic images as well as the ability to easily resolve moderately small vessels such as the ophthalmic and posterior communicating arteries. The potential usefulness of this technique for defining the base of a difficult aneurysm can be seen. It is interesting and revealing that a small area of spasm in the intrasylvian part of the middle cerebral artery was seen on the DTS image but was obscured by superimposed vessels on the conventional angiogram.

Case 3

A 28-year-old woman was evaluated for severe headaches of several weeks duration and increasing severity. CT was normal, and a digital intravenous angiogram was obtained to survey the intracranial vessels for a possible vascular abnormality as the etiology for her symptoms. Standard digital intravenous angiography of the intracranial vessels was done in anteroposterior and lateral projections with no obvious abnormality seen. Because the distal vessels were poorly seen due to superimposition, intravenous subtraction DTS was done in anteroposterior and lateral projections (fig. 3). This study was performed using our standard volume and rate of contrast injection (20 ml/sec for 2 sec of Renografin-76), and it confirmed a normal vascular pattern.

Comment: The intravenous DTS images show good detail of the more peripheral intracranial vessels arising from the middle cerebral artery, without the overlap from other vessels encountered with the standard digital intravenous angiograms. This case illustrates the potential of this technique for improving the small vessel visualization and, subsequently, the diagnostic yield that can be obtained with intravenous digital angiography.

Discussion

In recent years the importance of conventional tomography has rapidly declined and has been in large part replaced by CT [8]. There is no doubt that the superior density discrimination characteristics of CT provide far superior soft-tissue detail than is possible with geometric tomography. Nevertheless, there still remain some real limitations to CT that make conventional tomography a useful supplemental technique [8, 9]. For instance, although CT can provide exceptionally detailed information in the axial plane of the

body, it rather poorly defines structures in the longitudinal plane (i.e., coronal or sagittal views). On the other hand, conventional tomography provides a very rapid and efficient means for evaluating large areas of anteroposterior and lateral anatomy. Further, because CT provides images in the axial plane, one of the major limitations of CT in cervical spine trauma is in patients with fractures oriented in the horizontal plane [10]. Thus, compression fractures of the vertebral body or a horizontal fracture at the base of the dens may be poorly defined or even missed on CT examination. Similarly, subluxations within the spine may not be readily apparent on CT, and dynamic changes such as abnormal movement on flexion and extension of the spine must still be evaluated using conventional radiographic techniques.

The digital tomosynthesis method offers several advantages over conventional film-screen tomography. First, the patient procedure time is much shorter. The raw data images can be obtained in a few seconds and then postprocessed to reconstruct the tomographic pictures even after the patient has left. Second, any desired tomographic level can be synthesized. Third, the contrast of the image can be adjusted through appropriate window and level manipulation of the digital display settings. Fourth, the radiation dose for a DTS study is much lower than for a conventional tomographic study because only a fluoroscopic dose is necessary to obtain the raw data images, and because only one tomographic sweep is needed from which an entire series of cuts is reconstructed. Finally, since the data can be acquired very rapidly, this technique is easily applied to dynamic studies such as angiography.

Angiotomography has been used in many centers, but it has been limited by the fact that usually only one preselected tomographic plane can be viewed. If the wrong plane is selected or an additional tomographic level is needed for evaluation, then the information is lost unless another injection and filming sequence is done. In contrast, DTS allows retrospective selection of any desired plane, which makes angiotomography a far more practical and potentially useful technique in patient studies.

As shown by the illustrations from case 2, the quality of the DTS images is quite good and easily capable of resolving moderately small intracranial vessels. Its potential usefulness in defining the anatomic relationships at the neck of an aneurysm can be seen. Abnormalities that might otherwise be obscured by superimposed vessels (such as the localized vessel spasm shown in case 2) can be diagnosed using DTS.

Finally, digital intravenous angiography is now an established modality in our arsenal of diagnostic radiographic methods. It has several limitations that have hindered its usefulness for intracranial vessel evaluation. One of its major disadvantages in the study of branch arteries anywhere in the body is the superimposition of multiple vascular territories from simultaneous opacification after intravenous injection of contrast material. This makes it difficult or impossible to evaluate anatomy of the small- and medium-sized vessels, which must still be evaluated using selective arterial catheter techniques.

If DTS techniques can be applied to digital intravenous angiographic studies, it then becomes feasible to evaluate superimposed vascular territories that lie in different planes. In this way one may be able to obtain essentially selective vascular studies using intravenous injection of contrast material. We performed initial studies in dogs to evaluate the feasibility of intravenous digital subtraction angiotosynthesis, and our results showed that such studies could be done. Case 3 supports our contention and shows the potential of intravenous DTS in clinical applications. This case indicates that even following intravenous injection of contrast material, there is quite good vessel detail on the DTS images.

It should be emphasized that the images illustrated in this preliminary report were obtained using an in-house prototype system constructed from various components of commercial systems from different manufacturers. Thus, the operating system we used was not optimized for imaging. Furthermore, the x-ray exposure parameters used for our studies were not optimized, and most of the images were acquired at standard fluoroscopic doses. The computer algorithms have not been refined, and the analog video disk recorder used in the system adds additional noise to the images. A digital disk capable of recording 512×512 images at real-time rates of 30 frames/sec would be preferable. In addition, during the course of these studies the video disk often did not perform up to its specifications with the result that considerable additional noise, which was actually visible on the raw data images, was present during tomosynthesis processing. Despite all of these problems, the resulting images illustrated in this report are of very good quality

and provide resolution of fine bony structures and contrast-filled blood vessels, some of less than 1 mm in size. On the basis of these preliminary results we are extremely encouraged and are pursuing the DTS technique further.

REFERENCES

1. Miller ER, McCurry EM, Hruska B. An infinite number of laminagrams from a finite number of radiographs. *Radiology* **1971**;98:249-255
2. Lasser EC, Baily NA, Crepeau RL. A fluoroplanigraphy system for rapid presentation of single plane body sections. *AJR* **1971**;113:574-577
3. Baily NA, Lasser EC, Crepeau RL. Electrofluoroplanigraphy. *Radiology* **1973**;107:669-671
4. Baily NA, Crepeau RL, Lasser EC. Fluoroscopic tomography. *Invest Radiol* **1974**;9:94-103
5. Horner SD, Murry RC. Digital subtraction tomosynthesis. Presented at annual meeting of the Radiological Society of North America, Chicago, November **1981**
6. Maravilla KR, Murry RC, Horner S. Digital tomosynthesis: Description of an electronic tomographic technique. Presented at the International Symposium and Course on Computed Tomography and Other Computed Assisted Imaging Techniques, New Orleans, April, **1982**
7. Maravilla KR, Murry RC, Horner S. Digital tomosynthesis: Description of a technique for electronic reconstructive tomography. *AJNR* **1983**;4 (in press)
8. Carter BL. A comparison of computed and conventional tomography—conflictual or complementary? *J Comput Assist Tomogr* **1982**;6:1040-1041
9. Miller EM. The role of CT scanning in the evaluation of spine trauma. Presented at the annual meeting of American Society of Neuroradiology, Los Angeles, March, **1980**
10. Faerber EN, Wolpert SM, Scott RM, Belkin SC, Carter BL. Computed tomography of spinal fractures. *J Comput Assist Tomogr* **1979**;3:657-661