

Are your **MRI contrast agents** cost-effective?

Learn more about generic **Gadolinium-Based Contrast Agents**.



FRESENIUS  
KABI

caring for life

**AJNR**

**Clinical trial of iotrol for lumbar myelography.**

T Skutta, H Vogelsang, M Galanski, B Hammer and H J  
Weinmann

*AJNR Am J Neuroradiol* 1983, 4 (3) 302-303

<http://www.ajnr.org/content/4/3/302>

This information is current as  
of May 14, 2024.

## Clinical Trial of Iotrol for Lumbar Myelography

Thomas Skutta,<sup>1</sup> Heinzgeorg Vogelsang,<sup>2</sup> Michael Galanski,<sup>2</sup> Benno Hammer,<sup>3</sup> and Hanns-Joachim Weinmann<sup>1</sup>

**Iotrol, a new nonionic, water-soluble, hexiodinated dimeric contrast medium for myelography, was used in clinical trials in 29 patients. The purpose of the study was to acquire information on local and general tolerance, distribution and excretion, and image quality. Preliminary results show that iotrol is well suited for lumbar and thoracolumbar myelography. Side effects observed with the use of iotrol were fewer and less severe than those reported with metrizamide. Iotrol is cleared from the cerebrospinal fluid and excreted by glomerular filtration within the same time range as other water-soluble contrast media.**

After the introduction in 1969 of the nonionic, water-soluble contrast medium metrizamide (Almen), this substance was preferred for intrathecal use. More complete filling of the nerve roots resulted in better pathoanatomical visualization than myelography with oily contrast media. The neurotoxicity of this nonionic monomeric compound was significantly lower than that of ionic contrast media, which made it possible to investigate the entire spinal canal [1]. It was no longer necessary to withdraw the contrast agent after the examination. This was a great advantage for both investigators and patients. Later the nonionic monomeric contrast agents iopamidol [2] and iohexol [3] were also introduced. Neuropsychologic reactions and other side effects after myelography are well known. Spinoradicular symptoms such as radicular pain, hyperesthesia, hyperreflexia, and urinary retention and cerebral or spinocerebral symptoms such as convulsions, visual and auditory disturbances, and confusion have been related to the use of contrast agents, especially metrizamide [4]. For this reason, the search for better tolerated and less toxic water-soluble contrast agents has continued.

A new class of nonionic, water-soluble contrast media has now been developed: dimeric, hexiodinated compounds. One of these, iotrol, was especially developed for myelography (fig. 1). Its molecular weight is 626.4; the iodine content is 46.8%. Iotrol is readily usable and available as a liquorisotonic preparation with a concentration of either 190, 240, or 300 mg I/ml. Extensive pharmacologic testing in animal models has indicated better neural tolerance for iotrol than for nonionic monomeric contrast agents. Improved tolerance for iotrol is related to its pronounced hydrophilic properties; the fact that it has the same osmotic pressure as cerebrospinal fluid in all concentrations; and its low rate of penetration into the brain.

### Materials and Methods

The first clinical trials using iotrol in lumbar and thoracolumbar myelography were carried out in 29 patients (19 men, 10 women). The age distribution of patients was as follows: < 30 years, one patient; 30–40 years, 10; 41–50 years, seven; 51–60 years, eight; > 60 years, three. Standard myelographic technique was used with no premedication. Twenty patients received 10 ml iotrol with 190 mg I/ml; nine patients received 8–10 ml iotrol with 240 mg I/ml. In nearly all cases the contrast medium was administered within 30 sec with the patient in a sitting position. Trials were designed to evaluate the radiologic diagnostic quality achieved, to measure general patient tolerance for the contrast agent, and to investigate any changes in laboratory findings. In addition, pharmacokinetic reactions were measured and recorded in eight patients. In these patients, blood was sampled at intervals during the first 3 days after intrathecal injection. Urine was sampled in fractions and the balance determined by analysis of the total amount of urine and feces excreted during the 3 days immediately after myelography. The iodine content of the individual blood and urine samples was determined by x-ray fluorescence.

### Results

#### *Diagnostic Quality*

The radiologic diagnosis was disk herniation in 23 cases and arachnoiditis in one case. There were no pathologic findings in five cases. In all 29 cases, opacification and resulting visualization was judged good to very good using either concentration of the contrast agent.

#### *General tolerance*

Nineteen of the 29 patients examined showed no side effects after iotrol myelography. The other 10 developed the following adverse reactions: mild headache, three patients; mild neck pain, three; disturbed circulation, two; spinoradicular pain, one; and subjective visual disturbance, one. Therapy for side effects was required in only two patients, one with disturbed circulation and one with radicular pain. Blood chemistry and hematologic testing before

<sup>1</sup> Schering Berlin (West) and Bergkamen Research Laboratories, Postfach 650311, D-1000 Berlin 65, West Germany. Address reprint requests to T. Skutta.

<sup>2</sup> Department of Neuroradiology, Hannover Medical School, D-3000 Hannover 61, West Germany.

<sup>3</sup> Department of Radiology, Wagner-Jauregg Hospital, A-4020 Linz, Austria.

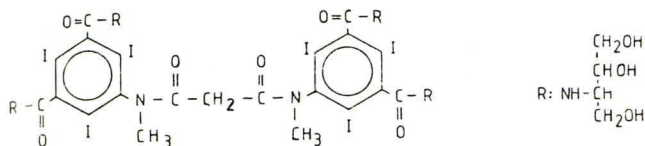


Fig. 1.—Structural formula of iotrol. Molecular weight is 626.4; iodine content is 46.8%.

after administration of the contrast medium failed to demonstrate any definite influence attributable to the substance.

#### Pharmacokinetics

In five of the patients examined, the maximum plasma concentration was 7.8% of the total dose at 1 hr after injection of the contrast medium. In the other three patients, the peak concentration was measured 2–6 hr after injection. The urine samples in these patients contained 27% of the given dose after 6 hr, 67% after 12 hr, and 80% after 24 hr. After 3 days,  $87\% \pm 4\%$  of the contrast medium had been renally eliminated. Extrarenal excretion was less than 0.5%. No metabolites were detected.

#### Discussion

The quality of contrast and the sharpness of delineation with iotrol myelography was good. The miscibility of this dimeric contrast agent with cerebrospinal fluid appeared the same as that of other water-soluble, nonionic, monomeric substances. These results have yet to be confirmed with the more highly concentrated but still liquorisotonic preparation of iotrol containing 300 mg I/ml.

Mild side effects after lumbar myelography occur with the same frequency with the use of ionic and nonionic contrast media [4–7]. Headache, nausea, dizziness, and vomiting are adverse reactions determined primarily by the lumbar puncture as such; these occur with a frequency ranging from 15% [8] to 57% [1]. In comparative studies the incidence of such side effects is about the same for the compared substances [6, 9]. The present data for iotrol indicate only mild side effects. Neurotoxic reactions such as mental disorders, spinoradicular symptoms, and cerebral or spinocerebral symptoms, reported after the use of metrizamide and other water-soluble contrast media [4, 10, 11], did not occur with iotrol.

The pharmacokinetic behavior of iotrol after lumbar administration is comparable to that of metrizamide [12, 13]. Resorption of the contrast medium from the cerebrospinal fluid is subject to a range of individual variation; for this reason, resorption-related differences between the nonionic dimer iotrol and nonionic monomers were not documented.

In summary, initial clinical trials confirm the preclinically proven superiority of iotrol over monomeric contrast media and support the further use of iotrol in lumbar myelography. Results of preliminary clinical trials using iopamidol in lumbar myelography [7] have shown a higher frequency of side effects than we found with iotrol. A better general tolerance for this new contrast medium can therefore be assumed. Further trials using higher concentrations, especially in thoracic and cervical myelography, are indicated.

#### REFERENCES

1. Gonsette E. Metrizamide as contrast medium for myelography and ventriculography. Preliminary clinical experiences. *Acta Radiol [Suppl]* (Stockh) **1973**;335:346–358
2. Felder E, Pitré D, Tirone P. Radiopaque contrast media. XLIV. Preclinical studies with a new non-ionic contrast agent. *Far-maco [Sci]* **1977**;23:835–844
3. Haavaldsen J. Iohexol. Introduction. *Acta Radiol [Suppl]* (Stockh) **1980**;362:9–11
4. Hauge O, Falkenberg H. Neuropsychologic reactions and other side effects after metrizamide myelography. *AJNR* **1982**; 3:229–232, *AJR* **1982**;139:357–360
5. Grainger RG, Kendall BE, Wylie IG. Lumbar myelography with metrizamide—a new non-ionic contrast medium. *Br J Radiol* **1976**;49:996–1003
6. Hammer B, Lackner W. Iopamidol, a new non-ionic hydrosoluble contrast medium for neuroradiology. *Neuroradiology* **1980**;19:119–121
7. Drayer B, Suslavich F, Luther J, et al. Clinical trial of iopamidol for lumbosacral myelography. *AJNR* **1982**;3:59–64
8. Sortland O, Lundervold A, Svare A, Hauglie-Hansen E. Metrizamide in radiography of the central nervous system. A preliminary report. *Acta Radiol [Suppl]* (Stockh) **1975**;347:477
9. Hindmarch T. Lumbar myelography with meglumine iocarmate and metrizamide. *Acta Radiol [Diagn]* (Stockh) **1975**;16:209–222
10. Schmidt RC. Mental disorders after myelography with metrizamide and other water-soluble contrast media. *Neuroradiology* **1980**;19:153–157
11. Agnoli AL, Constantinidis C. Das Psychosyndrom bei intrathekaler Anwendung von Metrizamid: eine klinisch-computer-tomographische Untersuchung. *CT-Sonography* **1982**;2:21–27
12. Golman K. Absorption of metrizamide from cerebrospinal fluid to blood: pharmacokinetics in humans. *J Pharm Sci* **1975**;64:405–407
13. Speck U, Schmidt R, Volkhardt V, Vogelsang H. The effect of position of patient on the passage of metrizamide (Amipaque), meglumine iocarmate (Dimer X) and ioserinate (Myelografine) into the blood after lumbar myelography. *Neuroradiology* **1978**;14:251–256