

Are your **MRI contrast agents** cost-effective?

Learn more about generic **Gadolinium-Based Contrast Agents**.



FRESENIUS
KABI

caring for life

AJNR

Absorption after subarachnoid and subdural administration of iohexol, ^{51}Cr -EDTA, and ^{125}I -albumin to rabbits.

E Holtz, A A Michelet and T Jacobsen

AJNR Am J Neuroradiol 1983, 4 (3) 338-341

<http://www.ajnr.org/content/4/3/338>

This information is current as of April 17, 2024.

Absorption after Subarachnoid and Subdural Administration of Iohexol, ^{51}Cr -EDTA, and ^{125}I -Albumin to Rabbits

E. Holtz,¹ Å. Aulie Michelet, and T. Jacobsen

The absorption of the nonionic contrast medium iohexol, the clearance tracer ^{51}Cr -ethylenediaminetetraacetic acid, and the blood-pool marker ^{125}I -human serum albumin was studied after subarachnoid and subdural injection in rabbits. Subdural deposition of the contrast medium and ^{51}Cr -ethylenediaminetetraacetic acid resulted in a faster absorption rate and higher achieved blood levels than a subarachnoid injection of the two substances, where a slow absorption to lower blood concentrations was observed. No significant differences in absorption rate could be shown after subdural and subarachnoid administration of iodine-labelled albumin. The excretion of iohexol was observed for 1 week after the intrathecal injection. For both the subdural and subarachnoid depositions, about 83% of the injected iohexol was found in urine within 24 hr after injection. The total recovery of iohexol after 1 week was 96% (range, 87%–101%).

The elimination of water-soluble contrast media from the subarachnoid space has been studied in both animals and man [1–9]. In most of the reported studies care was taken not to include cases where the contrast medium was injected partly extraarachnoidally; however, in practical myelography subdural location of contrast media does occur [10].

Little is known about the elimination of contrast media after subdural administration. We studied the elimination of the nonionic contrast medium iohexol after subarachnoid and subdural deposition in rabbits. The contrast medium was injected together with two well known tracers, ^{51}Cr -ethylenediaminetetraacetic acid (^{51}Cr -EDTA) and ^{125}I -human serum albumin (^{125}I -HSA).

Materials and Methods

Thirteen rabbits (Norwegian land albinos) of either gender, weighing 1.5–2.5 kg, were anesthetized with pentobarbital sodium (Nembutal, Abbott). An initial intravenous dose of 25–35 mg pentobarbital sodium/kg (median 30 mg/kg) was given. Total doses given during the experiments were 50–100 mg pentobarbital sodium/kg (median, 70 mg/kg). The animals had free access to food and water before the experiment, and no fluids were given during the study. The rabbits were placed in a prone position with the head elevated 13°. A heat blanket with constant temperature control was used to maintain the body temperature at 39°C.

The cisterna magna was punctured suboccipitally with a 21 gauge cannula connected to polyethylene tubing. When free cerebrospinal fluid (CSF) flow was established, the test solution contain-

ing iohexol, ^{51}Cr -EDTA, and ^{125}I -HSA was injected at a rate of 0.1 ml/sec. Iohexol was given at a dose equivalent to 71–82 mg iodine/kg (median 79 mg I/kg). The concentration was 285 mg I/ml test solution (range 269–307 mg I/ml). ^{51}Cr -EDTA was given at a dose of 0.19 MBq/kg; and ^{125}I -HSA at a dose of 74–130 kBq/kg. The total volume of the test solutions ranged from 0.25 ml/kg to 0.30 ml/kg (median 0.28 mg/kg). ^{51}Cr -EDTA (3.7 MBq/ml, 0.3–0.7 mg ^{51}Cr -EDTA/ml) was obtained from Amersham International, Amersham, England; ^{125}I -HSA (14.8 and 23.9 MBq/ml, 1.7 MBq/mg serum albumin) from Energiteknikk, Kjeller, Norway; and iohexol (Omnipaque, 370 mg I/ml) from Nyegaard, Oslo, Norway. Radiographs of the skull and the spine were taken 1, 11, and 61 min after completion of the injection in order to evaluate the flow of the contrast medium. Arterial blood samples (2 ml) were obtained from a polyethylene catheter (PP60) inserted in the common carotid artery, and taken 5, 10, 15, 30, 45, 60, 75, 90, 105, 120, 150, 180, and 240 min after injection. The artery was then ligated, the catheter withdrawn, and the wound closed with clips. The rabbit was returned to a horizontal position and no further pentobarbital doses were given. Blood samples at 5 and 24 hr and 7 days after injection were taken from a lateral ear vein.

Ten of the 13 rabbits were placed in metabolic cages until day 7 after injection of the test solutions. Urine and feces were collected quantitatively daily for 1 week. At the end of the experiment the metabolic cages were rinsed with 1 L tap water and all washing water was preserved. Aliquots of urine and wash water were centrifuged (10 min, 2,500 rpm, Wifug X-1) and the iohexol concentration was determined in aliquots of the supernatant by means of high-pressure liquid chromatography (Jacobsen T, Børresen S, unpublished data).

The fecal samples were pooled 0–4 and 5–7 days after injection. The samples were homogenized (Ultra-Turrax Model TP18–10 or T45) in 10 times their weight of distilled water. Aliquots of homogenized feces were analyzed for iodine content using neutron activation (Energiteknikk, Kjeller, Norway). The blood samples were analyzed for their content of ^{125}I -HSA and ^{51}Cr -EDTA by gamma-counting (LKB Wallac 1280 Ultragramma). Serum was analyzed for the content of iohexol by high-pressure liquid chromatography.

Results

No adverse reactions such as seizures were observed in any of the rabbits. Evaluation of the radiographs revealed two groups of animals: group 1 ($n = 6$) showed subdural deposition of the contrast

¹ All authors: Research Department, Nyegaard & Company, P.O. Box 4220 Torshov, Oslo 4, Norway. Address reprint requests to E. Holtz.

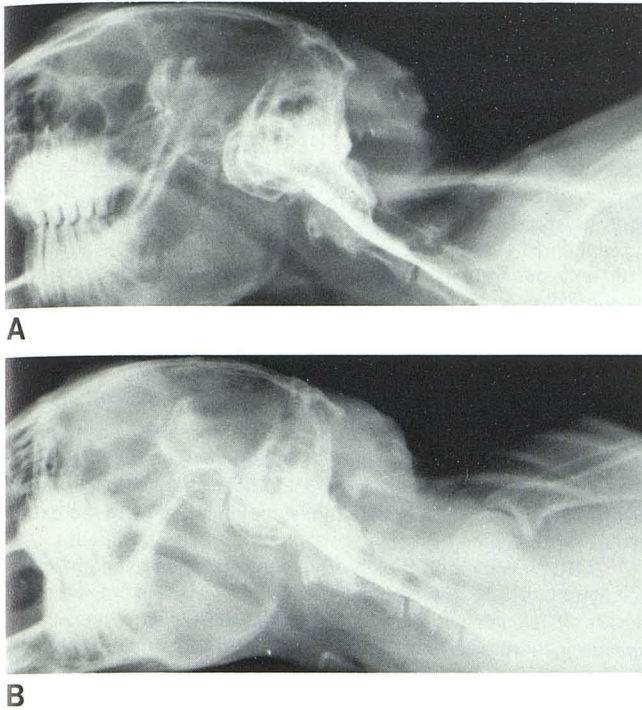


Fig. 1.—Distribution of contrast media 1 min after injection. Subdural (A) and subarachnoid (B) depositions.

medium and group 2 ($n = 7$) showed subarachnoid deposition of iohexol (fig. 1).

An injection is defined as subdural if the contrast medium appears irregularly on either the dorsal or ventral side of the cervical spine, showing a patchy contrast enhancement with relatively sharp boundaries (scalloping). "Punched-out defects" are often seen. Subarachnoidally injected contrast medium is distributed homogeneously into the CSF and delineates both dorsal and ventral borders of the spine. Contrast enhancement in the basal cisterns is only observed after a subarachnoid injection.

In animals injected subdurally (group 1) the serum concentration of iohexol (fig. 2A) increased rapidly and reached maximum values (130–260 μg iohexol/ml serum) 45–75 min after the injection. The rabbits injected subarachnoidally (group 2) showed a relatively slow increase to lower maximum concentrations (55–76 μg iohexol/ml serum) 105–300 min after the injection.

Nearly the same absorption pattern was observed for ^{51}Cr -EDTA (fig. 2B), showing a faster increase to higher serum concentrations in the subdural group than in the subarachnoid group. There was a close relation between the absorption of iohexol and ^{51}Cr -EDTA in all rabbits of both groups (fig. 3).

^{125}I -HSA showed a different absorption pattern. The ^{125}I -HSA concentration in blood increased continuously after both subdural and subarachnoid injections (fig. 4). The highest blood concentrations of ^{125}I -HSA were obtained 5 hr ($n = 2$) and 24 hr ($n = 9$) after injection. No correlation between the mode of intrathecal deposition of ^{125}I -HSA and its absorption could be established. However, the absorption curves of four of the six animals injected subdurally reached higher concentrations than those of the animals injected subarachnoidally.

A median of 83% of the injected iohexol was recovered in urine within 24 hr after injection. After 1 week a median of 91% (range 81%–97%) was excreted in urine (table 1). Including the amount in

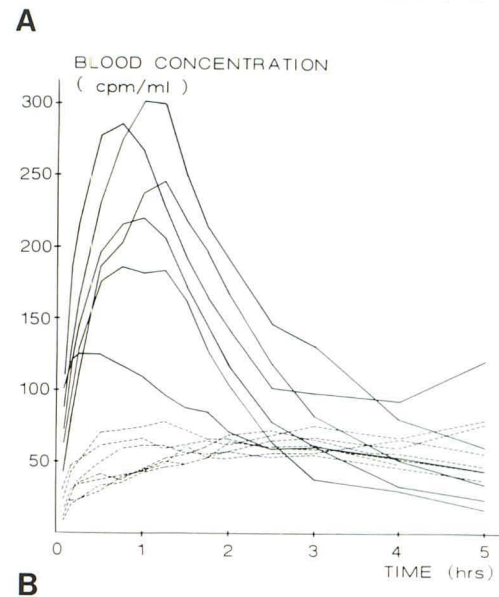
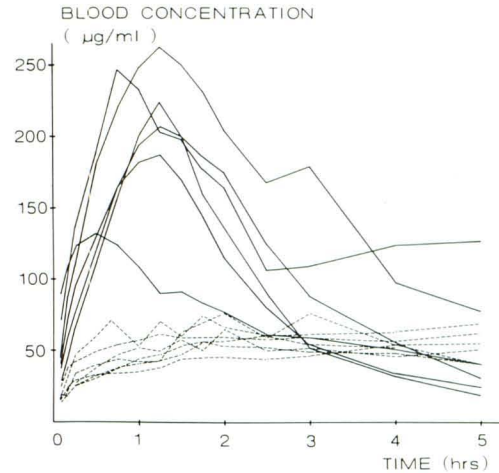


Fig. 2.—Blood concentrations of iohexol (A) and ^{51}Cr -EDTA (B) after intrathecal injection. Subdural ($n = 6$) (solid lines) and subarachnoid ($n = 7$) (broken lines) depositions.

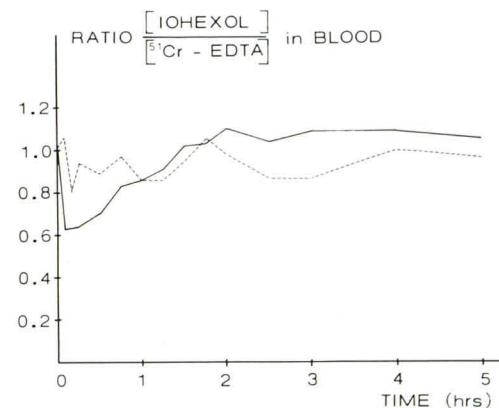


Fig. 3.—Ratio of iohexol ($\mu\text{g}/\text{ml}$) to ^{51}Cr -EDTA (counts/min/ml) in blood after intrathecal injection. Ratio in injection solution has been set equal to 1.0, and median values are shown. Subdural ($n = 6$) (solid line) and subarachnoid ($n = 7$) (broken line) depositions of iohexol and ^{51}Cr -EDTA.

feces the median total recovery of injected iohexol was 96% (range 87%–101%). No correlation between the intrathecal deposition of the contrast medium and its excretion pattern was observed.

Discussion

All animals had free access to water before the experiment, and no fluids were given during the study. The general state of hydration/dehydration may therefore be assumed to be equal for the animals in both groups, and the state of hydration should be excluded as a reason for the different rates of transfer from CSF to blood [1]. Differences in kidney function could be another cause for the observed grouping of the serum values; however, 24 hr after injection of the test substances the percentage of iohexol recovered from urine was 84.5% (range 30%–89%) in the subdural group and 83.4% (range 38%–85%) in the subarachnoid group, indicating no difference in excretion capacity of the kidneys. The absorption

pattern of group 2 animals is in accordance with results from Golman et al. [6], who studied the absorption of a nonionic contrast agent after lumbar and intracisternal injection in rabbits. They concluded that the rate of absorption of a nonionic contrast agent from the spinal subarachnoid space of the rabbit is dependent on the region of contrast medium deposition, having found a slow absorption rate after intracisternal and a fast absorption rate after lumbar injection. Partain et al. [11] showed in a human CSF flow study quite different absorption rates in different areas of the human subarachnoid space.

In only one rabbit in each group did we observe detectable amounts of contrast medium in the lumbar area, where fast absorption might be expected. The thorough radiographic examination in our study revealed the differences in the deposition of the test solutions that led to the observed unequal pattern of absorption.

$^{51}\text{Cr-EDTA}$ (molecular weight 423) is distributed rapidly into and is confined to the extracellular space. It is excreted only by glomerular filtration [12–14]. Clearance [15] and excretion [16] studies after intravenous injection of iohexol indicate that iohexol is also cleared by glomerular filtration and is confined mainly to the extracellular space.

$^{51}\text{Cr-EDTA}$ is cleared rapidly from blood after intravenous injection in rabbits [17]. Its biological half-life is 37 ± 5 min (unpublished results). The sustained blood levels of $^{51}\text{Cr-EDTA}$ in both groups of animals in this study represent transport from CSF and the subdural space to blood. Blood levels were not measured long enough to obtain pharmacokinetic data from either $^{51}\text{Cr-EDTA}$ or iohexol.

The absorption pattern of $^{125}\text{I-HSA}$ could not clearly be related to the subdural or subarachnoid injection. However, because albumin leaves the vascular compartment slowly after having entered it from the subarachnoid or subdural space, the increased blood levels in four of six animals in group 1 may indicate a somewhat faster absorption to blood after subdural than after subarachnoid injection.

Although a subarachnoid deposition of the test substances was intended, nearly 50% of the injections were radiologically identified to be subdural. A subdural injection may occur despite obtaining a free CSF flow from the puncture site before introducing a test solution. It is difficult to decide at which moment during the infusion the needle partly or totally leaves the subarachnoid space. Therefore, it is quite possible that some of the injections, finally proved to be subdural, began as subarachnoid injections.

Lankelma et al. [18] reported results from a methotrexate absorption study in humans after multiple injections in the lumbar area

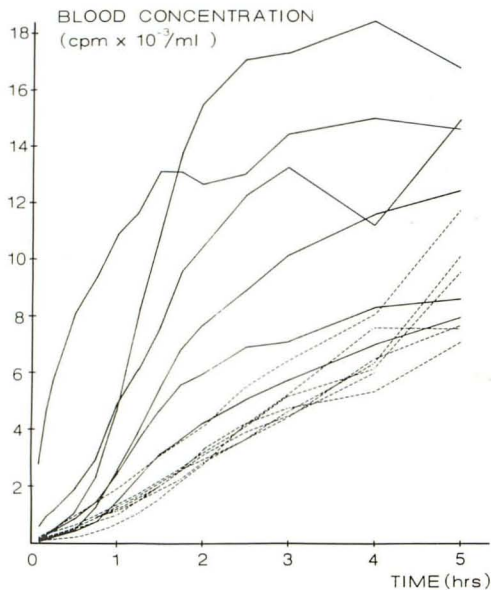


Fig. 4.— ^{125}I -albumin (counts/min/ml) concentrations in blood after intrathecal injection. Subdural ($n = 6$) (solid lines) and subarachnoid ($n = 7$) (broken lines) depositions of ^{125}I -albumin.

TABLE 1: Excretion of Iohexol after Intrathecal Injection to Rabbits

Rabbit No.	Iohexol Injected (mg)	Iohexol Excreted in Urine (% of Injected Dose)					Iohexol Recovery from Feces (%)	Total Recovery of Injected Iohexol in mg (%)
		Day 1	Day 2	Day 3	Wash Water*	7 Day Total		
4	353	83.4	11.3	neg	2.2	96.9	2.4	351 (99.4)
5	378	88.9	2.8	neg	2.3	94.0	4.1	371 (98.2)
6	374	89.3	2.2	neg	2.4	93.9	3.4	364 (97.3)
7	418	83.5	6.7	neg	3.6	93.8	1.9	400 (95.7)
8	418	80.1	2.7	4.8	2.8	90.4	10.3	421 (100.7)
11	338	84.7	†	†	1.5	91.7	3.5	322 (95.3)
12	391	†	33.9	31.4	7.9	81.4	5.2	338 (86.5)
14	420	30.3	52.6	1.7	1.2	85.8	3.0	374 (89.1)
16	324	37.9	37.9	4.6	7.5	88.3	8.7	314 (96.9)
18	332	72.2	7.1	1.9	6.3	88.1	2.7	302 (91.0)
Median		83.4	7.1	...	2.6	91.1	3	...
Range		30.3–89.3	2.2–52.6	...	1.2–7.9	81.4–96.9	1.9–10.3	...

* From the metabolic cages.

† No urine.

without radiologic control. They showed a "slow" type and a "fast" type of absorption, the latter occurring generally after one to three "slow" type absorptions. They suggested mechanical damage at the injection site caused by repeated lumbar punctures as a reason for the changed absorption. Similarly, we could speculate that a partial or complete extraarachnoid injection may also lead to a changed mode of absorption. Therefore, accurate deposition of test solutions in either the sub- or extraarachnoid spaces confirmed radiologically is necessary if valid conclusions from a study are to be drawn.

REFERENCES

1. Eldevik OP, Haughton VM, Sasse EA. The effect of dehydration on the elimination of aqueous contrast media from the subarachnoid space. *Invest Radiol* **1980**;15:155-157
2. Eldevik OP, Haughton VM, Sasse EA. Elimination of aqueous myelographic contrast media from the subarachnoid space. *Invest Radiol* **1980**;15:S260-263
3. Eldevik OP, Haughton VM, Sasse EA, Ho KC. Excretion of aqueous myelographic contrast media in animals undergoing a repeat myelogram. *Invest Radiol* **1980**;15:507-510
4. Golman K, Dahl SG. Absorption of labelled metrizamide, diatrizoate, inulin and water from cerebrospinal fluid to blood. *Acta Radiol [Suppl]* (Stockh) **1973**;355:276-285
5. Golman K. Absorption of metrizamide from cerebrospinal fluid to blood: pharmacokinetics in humans. *J Pharm Science* **1975**;64:405-407
6. Golman K, Wiik I, Salvesen S. Absorption of a non-ionic contrast agent from cerebrospinal fluid to blood. *Neuroradiology* **1979**;18:227-233
7. Hindmarsh T. Elimination of water-soluble contrast media from the subarachnoid space. Investigation with computer tomography. *Acta Radiol [Suppl]* (Stockh) **1975**;346:45-49
8. Haughton VM, Eldevik OP, Lipman BT. Excretion of contrast medium from the lumbar subarachnoid space of monkeys. *Radiology* **1982**;142:673-676
9. Haughton VM, Eldevik OP, Sasse EA, Lipman BT. Excretion of aqueous contrast media from the subarachnoid space of primates. In: Amiel M, ed. *Contrast media in radiology*. Berlin: Springer-Verlag, **1982**:129-133
10. Sackett JS. Myelographic technique with water-soluble contrast media. In: Sackett JS, Strother CM, eds. *New techniques in myelography*. New York: Harper & Row, **1979**:45-68
11. Partain CL, Wu HP, Staab EV, Johnson RE. A multiregional kinetics model for cerebrospinal fluid. *Radiology* **1978**;127:705-711
12. Stacy BD, Thorburn GD. Chromium-51 ethylenediaminetetraacetate for estimation of glomerular filtration rate. *Science* **1966**;152:1076-1077
13. Brading AF, Jones AW. Distribution and kinetics of CoEDTA in smooth muscle, and its use as an extracellular marker. *J Physiol* **1969**;200:387-401
14. Fenstermacher JD, Bradbury MWB, du Boulay G, Kendall BE, Radu EW. The distribution of ¹²⁵I-metrizamide and ¹²⁵I-diatrizoate between blood, brain and cerebrospinal fluid in the rabbit. *Neuroradiology* **1980**;19:171-180
15. Olsson B, Aulie Å, Sveen K, Andrew E. Human pharmacokinetics of iohexol—a new non-ionic contrast medium. *Invest Radiol* **1983**;18:(in press)
16. Mützel W, Speck U. Pharmacokinetics and biotransformation of iohexol in the rat and the dog. *Acta Radiol [Suppl]* (Stockh) **1980**;362:87-92
17. Tvedegaard E, Kamstrup O. Radioactive chromium-ethylene-diaminetetraacetic acid for determination of glomerular filtration rate in rabbits. *Lab Anim Sci* **1981**;31:688-692
18. Lankelma J, Lippens RJJ, Drenthe-Schonck A, Termond EFS, van der Klien E. Change in transfer rate of methotrexate from spinal fluid to plasma during intrathecal therapy in children and adults. *Clin Pharmacokinet* **1980**;5:465-475