

# Unilateral Ventricular Reflux and Asymmetric Ventricular Distribution of Intrathecally Introduced Contrast Medium or Tracer

E. Deisenhammer<sup>1</sup> and B. Hammer<sup>2</sup>

Fourteen cases of totally or predominantly unilateral ventricular reflux and stasis of intrathecally injected radioisotope or contrast medium were demonstrated by scintigraphy or computed tomographic cisternography. All showed asymmetric enlargement of the lateral ventricles and nine had ipsilateral brain lesions. Four case reports are presented. The pathophysiologic mechanism of communicating hydrocephalus and possible causes of unilateral ventricular reflux are discussed, as well as indications for ventricular shunt installation.

Communicating hydrocephalus (the so-called normal pressure hydrocephalus) is usually caused by subarachnoid hemorrhage, trauma, or meningitis with consecutive meningeal adhesions and obstruction of the cerebrospinal fluid (CSF) flow into the superior sagittal sinus. The flow of intrathecally injected tracer or contrast medium into the lateral ventricles is called ventricular reflux. In 1975 we reported a case of ventricular reflux of radioisotope [1]. Since then we have seen 13 other cases of totally or predominantly unilateral reflux of tracer or contrast medium.

## Subjects and Methods

Examinations were conducted as a diagnostic test for possible ventricular shunting in patients with suspected communicating hydrocephalus. Tracers used for the scintigraphic examinations were radioiodinated (iodine-131) serum albumin or technetium-99m-labelled protein or complex salt; contrast media used for computed tomographic (CT) cisternography were metrizamide or iopamidol.

## Representative Case Reports

### Case 1

After subarachnoid hemorrhage and surgical clipping of a left pericallosal artery aneurysm, a 24-year-old man had a left frontal brain infarct and a right frontal meningeal empyema. After further surgery, moderate symmetrical hydrocephalus developed. CT cisternography with metrizamide 4 months later demonstrated reflux of contrast medium in the right lateral ventricle. Periventricular lucency was seen on the right side and periventricular attenuation increased after 24 hr. Marked psychoorganic syndrome developed.

### Case 2

A 51-year-old woman had a left middle cerebral artery infarct after removal of a left sphenoid wing meningioma. Left-sided hydrocephalus developed. After lumbar injection of technetium-99m DTPA, unilateral ventricular reflux occurred with an accumulation of isotope at the site of surgery after 24 hr. The ventricular dilatation was confirmed by autopsy.

### Case 3

A 2-year-old girl, mentally retarded, was born with left spastic hemiparesis. Pneumoencephalography demonstrated marked dilatation of the left lateral ventricle. After lumbar injection of radioiodinated serum albumin, right-sided ventricular reflux and stasis occurred (fig. 1). Direct injection of radioisotope into the left lateral ventricle produced tracer in the right lateral ventricle within 20 min.

In four other cases a similar unilateral ventricular reflux was demonstrated. These patients all had prenatal or early childhood brain damage.

### Case 4

A 10-month-old boy had developed retardation with epileptic seizures at 4 months of age. CT demonstrated severe dilatation of the left lateral ventricle. Marked hypodensity around the occipital horns and small bilateral frontal hygromas were seen. CT cisternography with metrizamide resulted in marked, predominantly unilateral ventricular reflux with stasis of contrast medium on the left side (fig. 2). Biopsy revealed demyelination.

In six other cases a predominantly unilateral ventricular reflux of contrast medium was seen.

## Discussion

The pathophysiologic mechanism of communicating hydrocephalus is unclear. One theory is that ependymal or subependymal damage caused by dilatation of the lateral ventricles permits transependymal migration of CSF into the brain parenchyma and resorption of the CSF into the periependymal layer [2-5]. Other theories are based on reports of CSF flow from the dilated ventricles

<sup>1</sup>Department of Nuclear Medicine, Wagner-Jauregg Hospital, A-4020 Linz, Austria. Address reprint requests to E. Deisenhammer.

<sup>2</sup>Department of Radiology, Wagner-Jauregg Hospital, A-4020 Linz, Austria.

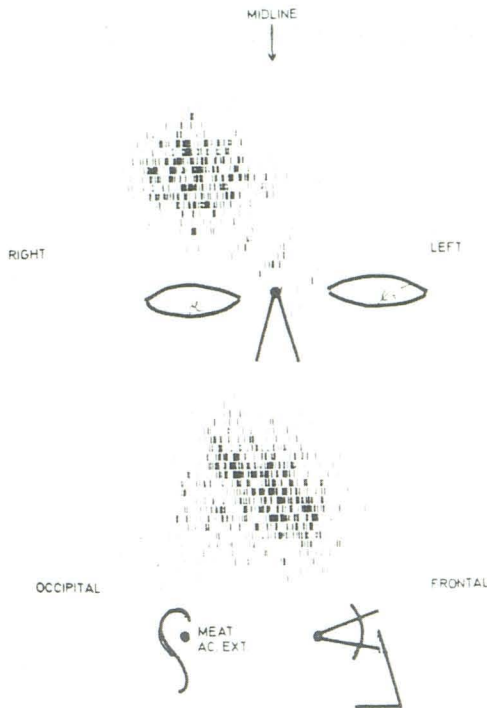


Fig. 1.—Case 3. Scintigram 2 hr after lumbar intrathecal injection of 10  $\mu$ Ci (370 kBq) radioiodinated (iodine-131) serum albumin. Complete reflux of tracer into right ventricle.

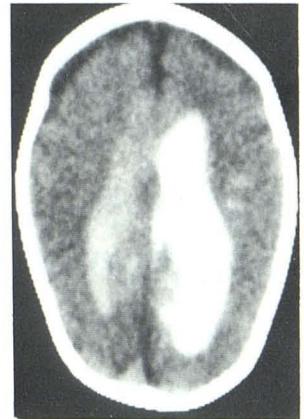into the spinal subarachnoid space and resorption in this region [6–8].

Our cases, characterized by asymmetric ventricular dilatation and unilateral ventricular reflux with stasis of the tracer or contrast agent, are difficult to explain. In nine of 14 cases, the unilateral ventricular dilatation and reflux was seen in combination with an ipsilateral brain lesion. Brain lesions (e.g., arachnoid cysts, porencephalies, cerebral hemiatrophy, scars, demyelination) produce changes in brain consistency, which can lead to intensification of intracranial pressure due to arterial pulsations and respirations, resulting in hydrocephalus [9, 10]. In cases of a unilateral brain lesion, an asymmetric intensification of intracranial pressure may occur, resulting in unilateral ventricular dilatation. However, the possibility of unilateral brain atrophy with ventricular dilatation *ex vacuo* cannot be ruled out. In two cases, where radioisotope was injected into the narrower lateral ventricle, the tracer flowed quickly into the wider lateral ventricle, with stasis. This would indicate a transependymal migration of the CSF from the wider lateral ventricle.

We cannot explain the asymmetric distribution of contrast material in normal or symmetrically dilated lateral ventricles in the absence of evidence of transependymal CSF resorption. An asymmetric diffusion of contrast medium [11] without an active bulk flow of CSF is possible.

We believe that ventricular reflux and stasis of tracer or contrast medium, together with a periventricular lucency and typical clinical

Fig. 2.—Case 4. CT cisternogram 3 hr after lumbar intrathecal injection of 4 ml metrizamide (150 mg iodine/ml). CT attenuation value in left lateral ventricle, 118 H; in right lateral ventricle, 38 H. Ventricular reflux predominantly unilateral. (H = Hounsfield units.)



findings, are indications for a shunt installation [12]. If there is no stasis, a shunt operation is not necessary. But the occurrence of totally or predominantly unilateral reflux with stasis requires insertion of an intraventricular shunt catheter in the affected ventricle.

#### REFERENCES

1. Deisenhammer E, Gund A, Hammer B, Steinhäusl H. Unilateral ventricular reflux: case report. *J Nucl Med* 1975;16:716–717
2. Hammer B. The pathophysiology of intrathecally-injected contrast medium. In: Felix R, Kazner E, Wegener OH, eds. *Contrast media in computed tomography*. Amsterdam: Excerpta Medica, 1981: 52–57
3. Milhorat TH, Clark RG, Hammock MK, McGrath PP. Structural, ultrastructural and permeability changes in the ependyma and surrounding brain favoring equilibration in progressive hydrocephalus. *Arch Neurol* 1970;22:397–407
4. Ogata J, Hochwald GM, Cravioto H, Ransohoff J. Light and electron microscopic studies of experimental hydrocephalus. *Acta Neuropathol (Berl)* 1972;21:213–223
5. Weller RO, Wisniewski H, Shulman K, Terry RD. Experimental hydrocephalus in young dogs. *J Neuropathol Exp Neurol* 1971;30:613–626
6. Becker DP, Wilson JA, Watson GN. The spinal cord central canal: Response to experimental hydrocephalus and canal occlusion. *J Neurosurg* 1972;36:416–424
7. Dohrman GJ. Cervical spinal cord in experimental hydrocephalus. *J Neurosurg* 1972;37:538–542
8. Torvik A, Stenwig AE. The pathology of experimental obstructive hydrocephalus. *Acta Neuropathol (Berl)* 1977;38:21–26
9. Du Boulay G, O'Connell J, Cuvrie J, Bostick T, Verity P. Further investigation on pulsatile movements in the cerebrospinal fluid pathways. *Acta Radiol [Diagn]* (Stockh) 1972;13:496–523
10. DiRocco C, Pettorossi VE, Caldarelli M, Mancinelli R, Velardi F. Communicating hydrocephalus induced by mechanically increased amplitude of the intraventricular cerebrospinal fluid pressure: experimental studies. *Exp Neurol* 1978;59:40–52
11. Schossberger PF, Touya JJ. Dynamic cisternography in normal dogs and in human beings. *Neurology (NY)* 1976;26:254–260
12. Hammer B. Experiences with intrathecally enhanced computed tomography. *Neuroradiology* 1980;19:221–228