

Are your **MRI contrast agents** cost-effective?

Learn more about generic **Gadolinium-Based Contrast Agents**.



FRESENIUS  
KABI

caring for life

# AJNR

## **Percutaneous transluminal angioplasty in arteriosclerotic internal carotid artery stenosis.**

S A Bockenheimer and K Mathias

*AJNR Am J Neuroradiol* 1983, 4 (3) 791-792

<http://www.ajnr.org/content/4/3/791>

This information is current as  
of May 14, 2024.

# Percutaneous Transluminal Angioplasty in Arteriosclerotic Internal Carotid Artery Stenosis

Stephan A. M. Bockenheimer<sup>1</sup> and Klaus Mathias<sup>2</sup>

Percutaneous transluminal angioplasty (PTA) of carotid arteries has been rarely reported. Dilatation of internal carotid artery stenosis has so far been performed only for fibromuscular dysplasia. Because of the risk of cerebral embolization the technique has not been used for arteriosclerotic stenosis, particularly since endarterectomy is known as a safe procedure. Three cases are reported of successful dilatation of arteriosclerotic internal carotid artery stenosis. A neurologic complication occurred in one patient. The primary indication for performing PTA in such cases is limited operability for medical reasons.

The introduction of the dilatation catheter by Grüntzig and Hopf [1] in 1974 provided a practicable tool for percutaneous transluminal angioplasty (PTA) in arteriosclerotic occlusive disease. Supraaortic vessels were at first avoided because of the risk of cerebral embolization. Fibromuscular dysplasia of the internal carotid artery, however, was successfully treated [2, 3]. In arteriosclerotic disease, dilatation of the external and common carotid arteries during surgical procedures have been reported [4, 5] as well as dilatations of other brachiocephalic branches [3, 5, 6].

Successful dilatation of electrically induced thrombosis of the carotid artery has been carried out in a canine model [7]. Pathologic anatomic specimens of the canine brains revealed no cerebral embolization. This experimental model does not exactly duplicate human arteriosclerotic occlusive disease. Nevertheless, these experiments and the encouraging results in our treatment without complications of 35 arteriosclerotic subclavian stenoses with the steal syndrome led us to attempt PTA of arteriosclerotic internal carotid artery stenosis in nonoperable cases.

## Subjects and Methods

Four patients with left internal carotid artery stenosis were treated with PTA. Two were men (56 and 74 years of age, respectively) and two were women (54 and 64 years of age, respectively).

A 7 French Grüntzig balloon catheter 3.5 cm long and 6 mm in diameter was used. The balloon was inflated manually with dilute contrast medium. Immediately after catheterization, 5,000 U of heparin was administered intraarterially. After the dilatation, 5,000 U of heparin was administered subcutaneously three times/day for 2 days. Platelet-suppressant drug therapy was maintained.

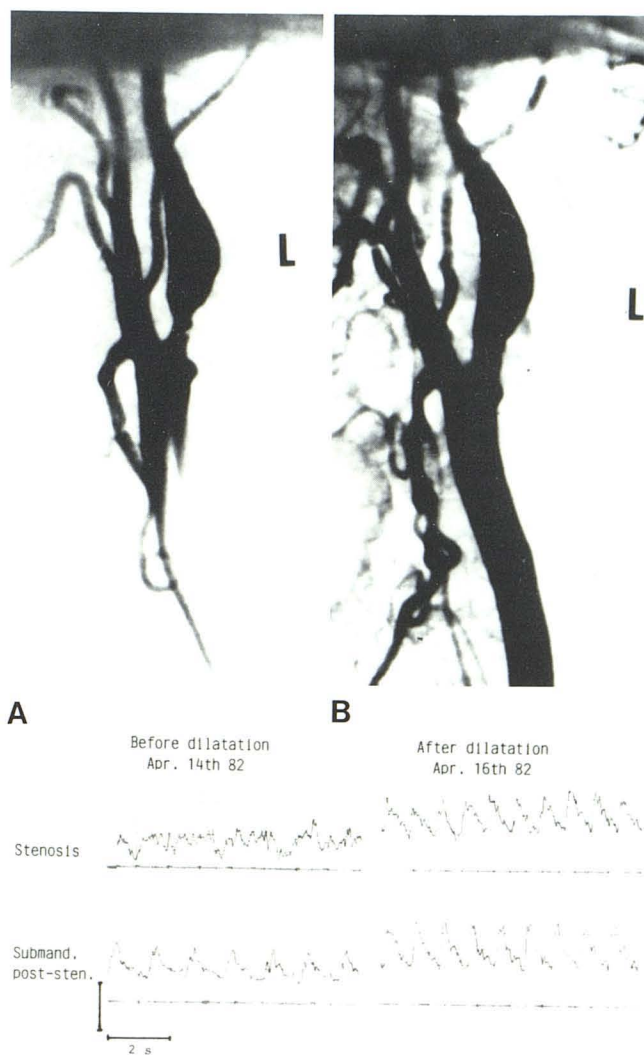


Fig. 1.—Left carotid artery stenosis in 54-year-old woman before (A) and after (B) percutaneous angioplasty. C, Doppler sonographic measurements in same patient before and after dilatation.

<sup>1</sup> Department of Diagnostic Radiology, Section of Neuroradiology, University of Freiburg, Hauptstr. 5, D-7800 Freiburg, West Germany. Address reprint requests to S. Bockenheimer.

<sup>2</sup> Department of Diagnostic Radiology, University of Freiburg, D-7800 Freiburg, West Germany.

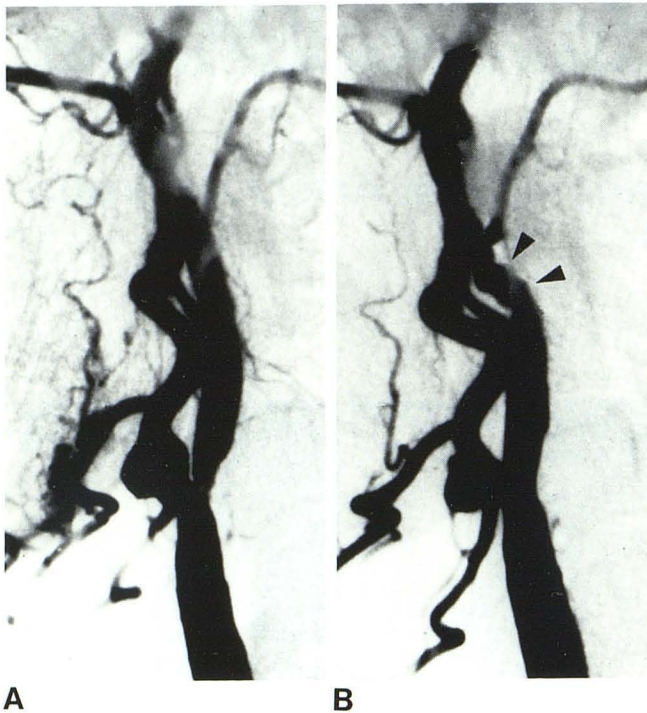


Fig. 2.—Left carotid artery stenosis in 64-year-old woman before (A) and after (B) successful dilatation. Spasm (arrowheads) 2 cm above original stenosis.

### Results

Angiograms showing the stenosis and the result of dilatation in the 54-year-old woman are shown in figures 1A and 1B; figure 1C shows the Doppler-sonographic measurements of the blood flow in the same patient before and after dilatation. The treatment was done without anesthesia. No complications occurred in this patient or in the 74-year-old-man. In the 56-year-old-man angioplasty was unsuccessful because we were unable to pass a wire through the filiform stenosis. There were no complications, however, and a successful endarterectomy was later performed. In the 64-year-old-

woman, dilatation was successful (fig. 2). Twenty min after the procedure a right hemiparesis with aphasia occurred, with complete recovery in 20 hr.

### Discussion

We have successfully treated arteriosclerotic internal carotid stenosis with PTA in two cases. In a third case which was unsuccessful, no complications ensued. The cause of the complication in the fourth case is obscure. On the postdilatation angiogram, spasm could be observed 2 cm above the original stenosis (fig. 2B). Since complications due to arterial spasms are known to occur in diagnostic arterial catheterization, the question of whether embolization or spasms led to the complication in our case cannot be answered. Because of the risks involved, PTA is certainly not the method of choice for treatment of arteriosclerotic internal carotid artery stenosis. Nonetheless, it should be attempted in selected cases deemed otherwise inoperable for medical reasons.

### REFERENCES

1. Grüntzig A, Hopff H. Perkutane Rekanalisation chronischer arterieller Verschlüsse mit einem neuen Dilatations-Katheter. *Dtsch Med Wochenschr* 1974;99:2502-2505
2. Hasso AN, Bird CR, Zinke DE, Thompson JR. Fibromuscular dysplasia of the internal carotid artery: percutaneous transluminal angioplasty. *AJNR* 1981;2:175-180
3. Mathias K, Heiss HW, Gospos C. Subclavian-Steal-Syndrom—operieren oder dilatieren? *Langenbecks Arch Chir* 1982;356:279-283
4. Kerber CW, Cromwell LD, Loehden OL. Catheter dilatation of proximal carotid stenosis during distal bifurcation endarterectomy. *AJNR* 1980;1:348-349
5. Motarjeme A, Keifer JW, Zuska AJ. Percutaneous transluminal angioplasty of the brachiocephalic arteries. *AJNR* 1982;3:169-174
6. Motarjeme A, Keifer JW, Zuska AJ. Percutaneous transluminal angioplasty of the vertebral artery. *Radiology* 1981;139:715-717
7. Mathias K. Die perkutane transluminale Katheterangioplastik (PTA) unter besonderer Berücksichtigung der selektiven perkutanen Dilatation (SPTD). Freiburg: Habilitationsschrift, 1979