

## Computed Tomography of Chiasmal Optic Neuritis

Mary K. Edwards,<sup>1</sup> Richard L. Gilmor, and James M. Franco

Three cases of chiasmal optic neuritis are described with bitemporal visual field loss and enlargement of the optic chiasm as demonstrated by computed tomography (CT). Exploratory craniotomies were performed in two of the patients, but no tumor was found. After corticosteroid treatment, all three patients experienced virtually complete restoration of normal vision. Although the CT presentation in these patients was indistinguishable from that of a chiasmal glioma, the clinical presentation of acute visual loss in an older child or adult should suggest chiasmal optic neuritis. A period of observation, with or without a trial of corticosteroids, might permit the latter diagnosis and obviate exploratory craniotomy.

Radiographic evidence of chiasm enlargement in patients with chiasmal visual field defects strongly suggests an optic chiasm glioma. Hoyt and Baghdassarian [1] have stated that exploratory craniotomy and biopsy are not necessary because neuroradiologic procedures alone can accurately diagnose chiasmal glioma. Our experience with three patients indicates that optic neuritis rather than optic chiasm glioma should be considered in cases of acute bitemporal visual field loss with computed tomographic (CT) evidence of chiasm enlargement. Exploratory craniotomy was performed in two such patients, and no tumor was found. Because the visual field loss cleared in all three patients and follow-up CT showed normal optic chiasms, the diagnosis of optic neuritis was made.

### Case Reports

#### Case 1

A 41-year-old man had a 4 week history of decreasing vision in both eyes, left worse than right. Visual acuity was 20/100 on the right and reduced to finger counting on the left. A bitemporal visual field defect was present, indicating a probable chiasmal lesion. A CT scan showed enlargement of the optic chiasm with uniform contrast enhancement suggestive of a chiasmal glioma (fig. 1). A craniotomy was performed 5 days later. No chiasmal enlargement or tumor was seen. No biopsy was performed because of the risk of permanent damage to the optic chiasm. The patient was treated with corticosteroids. In the month after surgery, visual acuity improved to 20/25 in both eyes, leaving only minimal visual field defects. Because of the marked clinical improvement, the diagnosis of chiasmal optic neuritis was made. Five months later the patient developed weakness in the lower extremities. Brainstem-evoked potentials were abnormal, and the presumed diagnosis of multiple sclerosis was made.

#### Case 2

A 9-year-old girl had a 3 month history of progressive loss of vision in her left eye. Visual examination showed optic atrophy on the left with visual acuity of 20/400. Visual acuity on the right was 20/20. Because a bitemporal visual field loss was demonstrated, a chiasmal lesion was suspected. A CT scan showed enlargement of the optic chiasm with contrast enhancement on the left (fig. 2). A craniotomy was performed, revealing diffuse enlargement of the left optic nerve and chiasm (about 2 × normal size). No gross tumor of the nerve and chiasm was seen and no biopsy was performed. After surgery, the patient was given a 2 week course of corticosteroids. Within 1 month her visual acuity improved to 20/30 on the left and 20/15 on the right. The visual fields showed only minimal bitemporal loss. A follow-up CT scan 3 months after surgery was normal and showed no chiasmal enlargement.

#### Case 3

A 15-year-old girl had a 2 month history of progressive loss of vision in her right eye. On admission her visual acuity was 20/15 on the left and reduced to light perception on the right. A temporal field defect was found in the left eye; there was optic atrophy on the right. A CT scan showed enlargement of the optic chiasm without contrast enhancement (fig. 3). The CT appearance was believed to be most compatible with an optic chiasm glioma; however, considering the clinical presentation and our past experience, the decision was made to treat the patient with a 2 week course of corticosteroids. Within 1 week her temporal field defect had largely cleared, and visual acuity on the right had improved to finger counting. Her vision continued to improve and returned to normal within 1 month. A follow-up CT scan 3 months after the initial scan showed a normal optic chiasm.

### Discussion

Optic neuritis is a well recognized cause of acute loss of vision, with spontaneous recovery in about 85% of cases [2]. The term refers to inflammatory or toxic conditions of the optic nerves resulting in acute unilateral or bilateral visual loss [2-6]. There are many causes of optic neuritis, but the most common associated disease is multiple sclerosis. In American and European studies multiple sclerosis followed optic neuritis in about one-third of affected patients, although various series reported an incidence between 13% and 85% [2-5].

During the episode of acute visual loss, CT demonstration of enlargement of the optic nerve is common, with or without associ-

<sup>1</sup> All authors: Department of Radiology, Indiana University School of Medicine, 926 W. Michigan St., Indianapolis, IN 46223. Address reprint requests to M. K. Edwards.

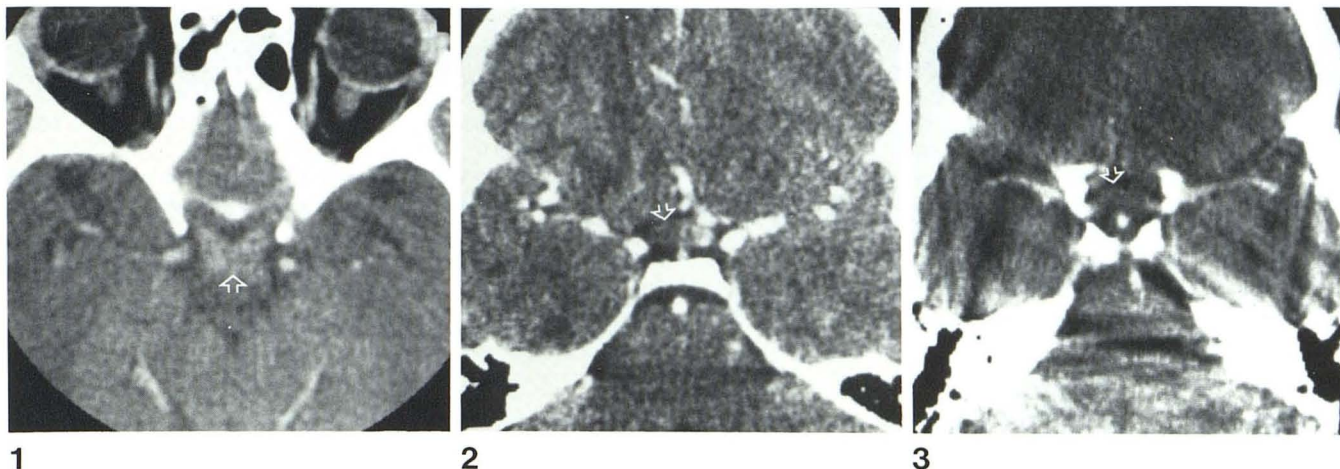


Fig. 1.—Case 1. 41-year-old man. Diffuse enlargement of optic chiasm with uniform contrast enhancement (arrow). (Courtesy of V. M. Haughton, Medical College of Wisconsin, Milwaukee, WI.)

Fig. 2.—Case 2. 9-year-old girl. Chiasmal enlargement with contrast

enhancement of optic chiasm on left (arrow).

Fig. 3.—Case 3. 15-year-old girl. Optic chiasm has uniform globular appearance with no evidence of contrast enhancement (arrow).

ated contrast enhancement [5]. The contrast enhancement is believed to reflect vascular permeability in the inflamed neural tissue [6]. The common presentation of central scotomas suggests that most demyelinating lesions occur in the prechiasmal part of the optic nerve [7]. Bitemporal hemianopsia has been reported in patients with multiple sclerosis, indicating that demyelinating lesions can occur in the region of the chiasm [7]. A single autopsy case of swollen optic chiasm in a 22-year-old woman with widespread multiple sclerosis is proof that optic neuritis can cause chiasmal enlargement [8]. There is disagreement about the efficacy of systemic corticosteroid therapy for optic neuritis, but such agents have been recommended during the acute stages, when vision is severely reduced [7].

The initial radiographic appearance of the chiasmal enlargement in our three cases is not diagnostic of either optic neuritis or a chiasmal glioma. Each case shows definite bilateral symmetric enlargement of the chiasm in a pattern consistent with previous descriptions of small chiasmal gliomas [9, 10]. Two of the patients in our series showed contrast enhancement of the chiasm. Both optic neuritis and optic nerve gliomas have been described with either the presence or absence of contrast enhancement; therefore, neither diagnosis is favored [5, 9, 10].

The initial clinical presentation in our three patients, although not pathognomonic, is sufficiently suggestive of optic neuritis to justify a period of observation. Although optic gliomas can occur in adults, the median age of presentation is in early childhood and has been reported as 2.3 and 4 years [11, 12]. In a series of 29 patients with biopsy-proven optic chiasm gliomas, 21 occurred in patients age 6 or younger [12]. In contrast, although optic neuritis has been reported in young children, it generally occurs in young adults (mean age, 33.7 years) [2].

The acute onset of the symptoms also favors the diagnosis of optic neuritis rather than glioma. Each patient in our series experienced rapidly progressive loss of vision over a period of 3 months or less. This is the common presentation in patients with optic neuritis, whereas patients with optic gliomas typically have a long history of visual disturbance [1, 13]; in a study of 36 children with optic gliomas, 80% had chronic ocular symptoms when first seen [1].

Optic chiasm gliomas have a high frequency of associated dis-

orders including hydrocephalus, neurofibromatosis, diencephalic syndrome, and hypothalamic signs [1, 11, 12]. Any of these findings in the presence of an enlarged optic chiasm strongly favors the diagnosis of tumor. None of these associated disorders was seen in our three patients. Moreover, the observed rapid clearing of the ocular signs and resolution of the chiasmal swelling was incompatible with the diagnosis of chiasmal tumor, but diagnostic of chiasmal optic neuritis.

Neuroradiologic evidence of chiasmal enlargement in patients with visual field defects is such strong evidence for chiasmal glioma that other diagnostic possibilities are seldom considered. Some investigators advocate that the diagnosis of chiasmal glioma be made on the basis of neuroradiologic evidence without incurring the risk of craniotomy [1]. Others disagree, stating that all masses of the optic nerve and chiasm should be biopsied [12]. Neither approach is necessary or advisable in patients with suspected chiasmal optic neuritis. If the diagnosis of glioma is made solely on the basis of the CT presentation, it may be erroneous. If all masses of the optic chiasm are biopsied, there is an unnecessary risk of associated permanent visual loss or damage.

Although chiasmal optic neuritis is uncommon, it should be included in the differential diagnostic considerations of chiasmal enlargement. When a patient's clinical presentation is not characteristic of tumor, a period of observation with or without a trial of corticosteroids, may spare the patient an incorrect diagnosis and an exploratory craniotomy.

#### REFERENCES

1. Hoyt WF, Baghdassarian SA. Optic glioma of childhood. *Br J Ophthalmol* 1969;53:793-798
2. Isayama Y, Takahashi T, Shimoyama T, Yamadori A. Acute optic neuritis and multiple sclerosis. *Neurology (NY)* 1982;32:73-76
3. Percy AK, Nobrega FT, Kurland LT. Optic neuritis and multiple sclerosis: an epidemiologic study. *Arch Ophthalmol* 1972;87:135-139
4. Cohen MM, Lesell S, Wolf PA. A prospective study of the risk of developing multiple sclerosis in uncomplicated optic neuritis. *Neurology (NY)* 1979;29:208-213

5. Howard CW, Osher RH, Tomask RL. Computed tomographic features in optic neuritis. *Am J Ophthalmol* **1980**;89:699-702
6. Hogan MJ, Zimmerman LE. *Ophthalmic pathology*, 2d ed. Philadelphia: Saunders, **1962**:423-424
7. Spector RH, Glaser JS, Schatz NJ. Demyelinative chiasmal lesions. *Arch Neurol* **1980**;37:757-762
8. Lindenberg R, Walsh FB, Sacks JG. *Neuropathology of vision: an atlas*. Philadelphia: Lea & Febiger, **1973**:250-251
9. Savolardo M, Harwood-Nash DC, Tadmor R, Scotti G, Musgrave MA. Gliomas of the intracranial anterior optic pathways in children. *Radiology* **1981**;138:601-610
10. Daniels DL, Haughton VM, Williams AL, Gager WE, Berns TF. Computed tomography of the optic chiasm. *Radiology* **1980**;137:123-127
11. DeSousa AL, Kalsbeck JE, Mealey J, Ellis FD, Muller J. Optic chiasmatic glioma in children. *Am J Ophthalmol* **1979**;87:376-381
12. Miller NR, Iliff WJ, Green WR. Evaluation and management of gliomas of the anterior visual pathways. *Brain* **1974**;97:743-754
13. Oxenhandler DC, Sayers MP. The dilemma of childhood optic gliomas. *J Neurosurg* **1978**;48:34-41