

Bacterial Meningitis in Infants: Sonographic Features

Henrietta Kotlus Rosenberg,¹ Richard S. Levine,² Kris Stoltz,¹ and David R. Smith³

Twenty-three infants with clinically proven bacterial meningitis were studied with real-time cranial sonography at the time of initial diagnosis and in several cases subsequently. A spectrum of sonographic abnormalities was observed, including bright convolitional markings, focal or diffuse increased and/or decreased parenchymal echoes, ventricular debris, and hydrocephalus. In three infants with virulent Gram-negative meningitis serial sonographic studies showed the development of encephalomalacia. Because clinical neurologic assessment of the infant is limited, a diagnostic imaging method that is sensitive to early structural change and suitable for serial observations is advantageous. Transfontanelle real-time sonographic examination of the brain was found to be a reliable, informative, and relatively inexpensive method of documenting and monitoring complicated bacterial meningitis.

Despite early treatment with antibiotics, bacterial meningitis in infants carries a significant morbidity and mortality. About half of the survivors are left with some abnormality [1-9]. The clinical neurologic assessment of the infant is limited, and so a reliable diagnostic imaging method that could demonstrate early structural change and monitor the sequelae of these findings would be advantageous. It is well known that infant intracranial anatomy can be clearly shown with transfontanelle real-time sonography [10, 11]. We therefore undertook a prospective study to determine the efficacy of this method for initial evaluation and follow-up studies of infants with proven bacterial meningitis.

Subjects and Methods

A prospective study was performed in 23 patients with clinically proven bacterial meningitis. The patient population comprised 13 boys and 10 girls, aged 3 days to 11 months. The bacterial etiologies for the meningitis were *Hemophilus influenzae* (12); pneumococcus (four); group B *Streptococcus* (one); nonenterococcal group D *Streptococcus* (one); *Citrobacter diversus* (two); *Enterobacter sahzackai* (one); and *E. coli* (two).

All the infants had sonography on admission, with sequential studies performed if the initial study showed parenchymal or ventricular abnormalities, if new symptoms appeared, if the cerebrospinal fluid (CSF) did not clear with antibiotic therapy, or if the infant's condition deteriorated acutely. All studies were done using the ATL Mark 300 real-time unit, equipped with 5 and 3 MHz scanning heads and multiformat camera. The examinations were

performed either in the sonography room or at the patient's bedside. Transfontanelle coronal and sagittal views, together with axial oil bath views (with an oil glove placed between the anterior fontanelle and transducer to better visualize the convexities of the brain [12]) were routinely obtained. The scans were assessed as to the presence of unusually bright convolutions, ventricular size, intraventricular debris, increased and/or decreased diffuse or focal parenchymal echoes, and evidence of encephalomalacia or abscess. The sonographic findings in six patients were correlated with computed tomographic (CT) studies, and in one patient with postmortem examination.

Results

A spectrum of sonographic abnormalities was observed in the 23 patients. These included bright convolitional markings (18 cases), diffuse increased echogenicity (five cases), focal areas of increased echogenicity (three cases), hydrocephalus or ventriculitis (six cases), tiny ventricles (five cases), and encephalomalacia (three cases). In those infants with only prominent convolitional markings, no complications were observed with serial studies. The combination of tiny ventricles and diffuse increased parenchymal echoes, suggesting inflammation and/or edema, was observed in four patients. Three of them had *H. influenzae* meningitis; one of these died. Postmortem examination showed exudate over the convexities of the brain and diffuse parenchymal swelling and hemorrhage; the other two had no sequelae. The fourth infant with this combination had *E. coli* meningitis and died, but no autopsy was done. Focal areas of increased echogenicity were present in five infants. The two infants with *H. influenzae* meningitis had complete resolution, with complications noted on follow-up sonograms. Serial studies of the infant with *E. sahzackai* showed progressive development of a large area of encephalomalacia in the right parietal region in the initially bright area. This was probably a hemorrhagic infarct. The two infants with *C. diversus* meningitis had the most severe parenchymal damage, with the initial focal areas of increased echogenicity becoming progressively anechoic, and with the eventual development of multiple areas of encephalomalacia (table 1).

Representative Case Reports

Case 1

A 2-month-old girl had lethargy, irritability, diarrhea, fever, and a history of recent otitis media treated with Amoxicillin. No focal

¹ Subdivision of Ultrasound, Department of Radiology, Children's Hospital of Philadelphia, 1 Children's Center, Philadelphia, PA 19104. Address reprint requests to H. K. Rosenberg.

² Department of Radiology, Hospital of the University of Pennsylvania, Philadelphia, PA 19104.

³ Department of Pediatrics, Children's Hospital of Philadelphia, Philadelphia, PA 19104.

TABLE 1: Complications of Bacterial Meningitis in 23 Infants, by Etiology

Bacterial Etiology	Type and No. of Complications				No. Deaths
	Seizure	Hydrocephalus	Diffuse Edema or Inflammation	Encephalomalacia	
<i>Hemophilus influenzae</i> (n = 12)	4	3	4	0	1
<i>Pneumococcus</i> (n = 4)	2	1	0	0	0
<i>Citrobacter diversus</i> (n = 2)	2	2	0	2	0
<i>Enterobacter sahzackai</i> (n = 1)	0	1	0	1	0
<i>E. coli</i> (n = 2)	1	0	1	0	1
Totals	9	7	5	3	2

Note.—None of these complications followed meningitis caused by group B *Streptococcus* (n = 1) or nonenterococcal group D *Streptococcus* (n = 1).

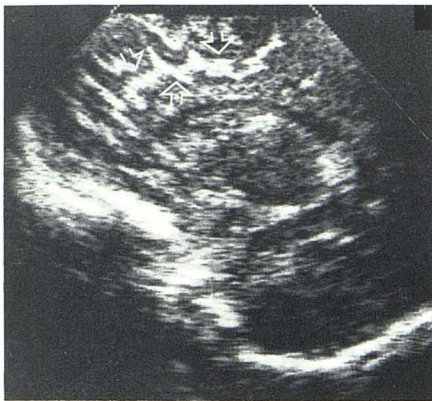
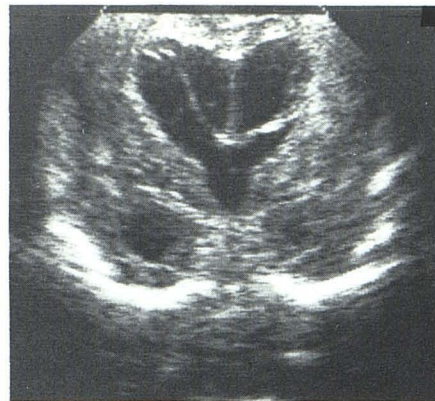
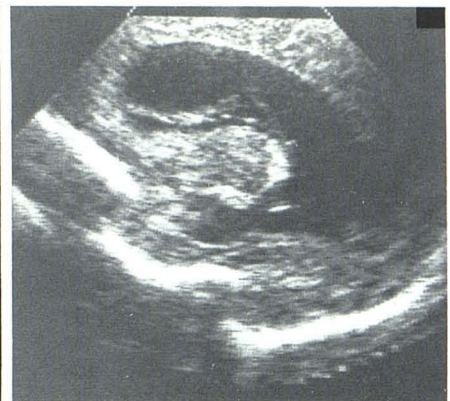Fig. 1.—Left sagittal section showing bright convoluted markings (arrows).



A



B

Fig. 2.—Coronal (A) and left sagittal (B) sections show diffuse hazy increased parenchymal echogenicity and marked dilatation of lateral and third ventricles with intraventricular debris.

neurologic signs were noted. CSF revealed 14,100 red blood cells/mm³, 3,200 white blood cells/mm³, 100% polymorphonuclear neutrophils, glucose 69 mg/dl, and protein 250 mg/dl. Gram stain showed moderate polymorphonuclear neutrophils with no bacteria. Culture grew *H. influenzae*, which was sensitive to chloramphenicol and resistant to ampicillin. Brain sonography revealed very bright convoluted markings (fig. 1). The child was treated with the appropriate antibiotics and was discharged in good condition.

Case 2

A 5-month-old twin girl was born premature (at 30 weeks gestation), and mechanical ventilation was needed for respiratory distress syndrome. No cranial sonography was done during the neonatal period. She had been brought to an outside hospital because of fever, eye deviations, and flaccidity. A lumbar puncture was performed and *H. influenzae* grew from the CSF. She was treated with ampicillin and chloramphenicol. She developed a clonic seizure disorder, was treated with phenobarbital and Dilantin, and was transferred to Children's Hospital of Philadelphia 2 days after admission to the first hospital. Sonography showed hazy diffuse increased parenchymal echogenicity and progressive hydrocephalus with debris within the ventricles (fig. 2). Partial decompression was achieved with a ventriculoperitoneal shunt tube.

Case 3

A 6-week-old boy with an uncomplicated premature birth developed lethargy and poor feeding about 4 hr before admission to an outside hospital. On arrival, he had an apneic spell with 30 sec of cyanosis, bradycardia, and obvious flaccidity. He required oxygen and intubation. CSF revealed 2,500 white blood cells/mm³, 80 red blood cells/mm³, 100% polymorphonuclear neutrophils, glucose 63/127 mg/dl, and protein 424 mg/dl. Ampicillin and chloramphenicol were started intravenously and he was transferred to our hospital. The CSF culture grew *E. sahzackai*. Initial sonography of the brain showed a bright area of increased echogenicity in the right parietooccipital region, suggesting a hemorrhagic infarct or a localized area of inflammation (fig. 3A). Nine days later the CSF was still positive for the same bacteria, and therapy was changed to carbenicillin and moxalactam. Sonography at 19 days after initiation of therapy showed moderate dilatation of the lateral ventricles and encephalomalacia in the right parietooccipital region (fig. 3B). At 3½ months of age, the baby had a seizure disorder with sharp wave activity on the right, hypertonicity of the left arm and leg, and reflexes +3 bilaterally, with a hint of clonus on the left.

Case 4

A male infant was the product of an uncomplicated 35 week pregnancy and delivery. He was well until day 9 of life when he

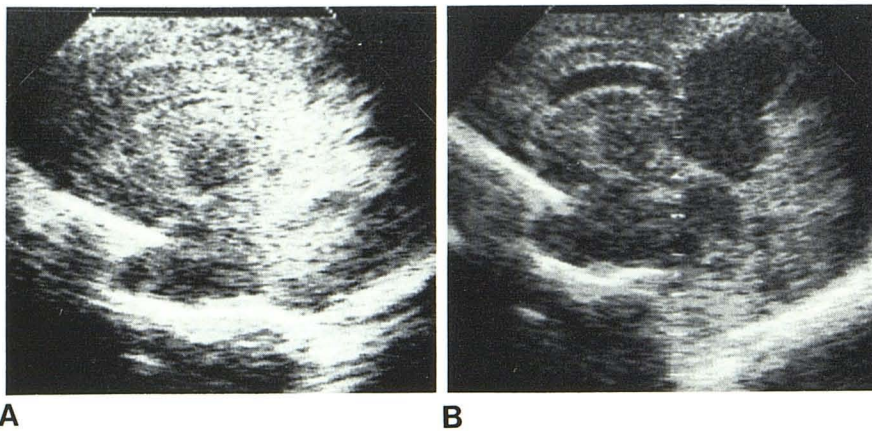


Fig. 3.—**A**, Right parasagittal view showing area of bright increased echogenicity in right parietooccipital region. **B**, Same section, 19 days later. Moderate dilatation of lateral ventricle and evidence of hypoechoogenicity in right parietooccipital region, suggesting encephalomalacia.

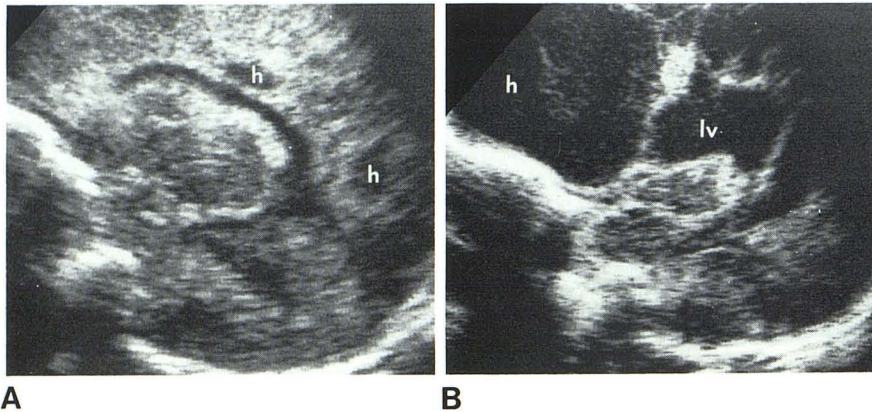


Fig. 4.—**A**, Parasagittal view on day 12 of life shows patchy parenchymal appearance, focal periventricular hypoechoic areas (h), and slight ventricular enlargement. **B**, Parasagittal view on day 29 shows dilated lateral ventricles (lv) and huge hypoechoic area (h) in frontal region, representing encephalomalacia.

became febrile and had an episode of cyanosis and apnea. His CSF was turbid and yellow, containing 14,410 white blood cells/mm³, 100% polymorphonuclear neutrophils, 20 red blood cells/mm³, glucose 6 mg/dl, and protein 310 mg/dl. Gram stain revealed Gram-negative rods. Cultures of CSF, urine, and nasopharynx grew *C. diversus*. Treatment was begun with ampicillin, followed by gentamycin and chloramphenicol. Sonography on day 12 of life showed abnormally bright cortical convolutions, scattered areas of increased echogenicity of the brain parenchyma, and several focal hypoechoic periventricular areas (fig. 4A). Although the patient was neurologically normal at age 18 days, serial sonography showed progressive enlargement of the hypoechoic areas with cystic degeneration and hydrocephalus (fig. 4B). The next week he developed seizure activity and remained irritable, with mild hypertonicity and hyperreflexia.

Discussion

The range of parenchymal changes reflects the variability in virulence of the infecting organisms and the spectrum of neuropathologic changes due to bacterial meningitis. Convolutional prominence may reflect arachnoiditis and exudate over the convexities of the brain [2], or small amounts of subdural effusion [3]. Brightness of the gyri does not appear to have any pathologic consequence. Diffuse hazy increased parenchymal echogenicity may reflect brain edema and/or diffuse cerebritis [6], which further can cause sufficient venous compression to produce irreversible cerebral damage.

Parenchymal abnormalities were observed most often in Gram-negative infections.

The sonographically most severe sequelae were observed in the two infants with *C. diversus* meningitis, who developed large areas of encephalomalacia and hydrocephalus over a period of only a few weeks. In the infant with *E. sakazackai*, a single large, brightly echogenic area progressed to an area of encephalomalacia. Focal parenchymal areas of increased echogenicity may reflect focal cerebritis, infarction, and possibly hemorrhage. It has been suggested that arteritis with thrombosis is the underlying etiology. The large anechoic areas representing encephalomalacia are believed to be the sequelae of the vasculitis. However, in infants with severe bradycardia and apneic spells, hypoxia or anoxia may be a contributing factor to the cystic degeneration.

Ventricular dilatation can be a manifestation of ventriculitis [13]. Hydrocephalus may be communicating if there is impairment of the reabsorption of the CSF from the subarachnoid space, or if there are intraventricular septations that can cause obstruction at various levels. A gliotic process in the subependymal region can produce tufts that act as a nidus for the formation of the septa [14]. The small slitlike ventricles appear to be due to generalized parenchymal inflammation and edema.

We have found that transfontanelle real-time sonography of the brain is a reliable, informative, and relatively inexpensive method of evaluating and monitoring infants with bacterial meningitis. Because the neurologic criteria for assessment of neonates are limited, there may be no way clinically to evaluate impairment in these infants until they are substantially older. Because sonography can accu-

rately detect early structural damage and the sequelae as well as hydrocephalus [17], this method can be used to evaluate the extent of brain damage and therefore can be an aid in prognosis. It can also be used to determine the necessity for shunting or septal lytic procedures.

On the basis of this prospective study, we recommend that an initial sonographic study be done at the time of diagnosis of bacterial meningitis. A follow-up study should be performed within 1 week if the initial scan demonstrates ventricular or parenchymal abnormalities. This will help to assess the development of further complications such as hydrocephalus, encephalomalacia, and/or abscess. In addition, we recommend a repeat scan if new symptoms appear, if the CSF does not clear with antibiotic therapy, or if the infant's condition deteriorates acutely. The real-time sector scanning head can also be used in the operating room for shunt placement and cyst drainage [15, 16].

REFERENCES

1. Fitzhardinge PM, Kazemi M, Ramsey M, Stern L. Long-term sequelae of neonatal meningitis. *Develop Med Child Neurol* **1974**;16:3-10
2. Berman PH, Banker BQ. Neonatal meningitis—a clinical and pathological study of 29 cases. *Pediatrics* **1966**;38:6-24
3. Dodge PR, Swartz MN. Bacterial meningitis—a review of selected aspects. *N Engl J Med* **1965**;272:1003-1010
4. Cussen LJ, Ryan GB. Hemorrhagic cerebral necrosis in neonatal infants with enterobacterial meningitis. *J Pediatr* **1967**;71:771-776
5. Friede RL. Cerebral infarcts complicating neonatal leptomeningitis—acute and residual lesions. *Acta Neuropathol (Berl)* **1973**;23:245-253
6. Buchan GC, Alvord EC. Diffuse necrosis of subcortical white matter associated with bacterial meningitis. *Neurology (NY)* **1969**;19:1-9
7. Smith JF, Landing BH. Mechanisms of brain damage in *H. influenzae* meningitis. *J Neuropathol* **1960**;19:248-265
8. Vogel LC, Ferguson L, Gotoff S. *Citrobacter* infections of the central nervous system in early infancy. *J Pediatr* **1978**;93:86-88
9. Overall JC. Neonatal bacterial meningitis—analysis of predisposing factors and outcome compared with matched control subjects. *J Pediatr* **1970**;76:499-511
10. Pigadas A, Thompson JR, Grube GL. Normal infant brain anatomy: correlated real-time sonograms and brain specimens. *AJNR* **1981**;2:339-344, *AJR* **1981**;137:815-820
11. Shuman WP, Rogers JV, Mack LA, Alvord EC, Christie DP. Real-time sonographic sector scanning of the neonatal cranium: technique and normal anatomy. *AJNR* **1981**;2:349-356, *AJR* **1981**;137:821-828
12. Rosenberg HK, Stoltz K. A new technique to visualize the convexities of the brain. *JCU* **1983**;11:56-58
13. Hill AH, Shackelford GD, Volpe JJ. Ventriculitis with neonatal bacterial meningitis: identification by real-time ultrasound. *J Pediatr* **1981**;99:133-136
14. Schultz P, Leeds NE. Intraventricular septations complicating neonatal meningitis. *J Neurosurg* **1973**;38:620-626
15. Shkolnik A, McLone DG. Intra-operative real-time ultrasonic guidance of ventricular shunt placement in infants. *Radiology* **1981**;141:515-517
16. Shkolnik A, McLone DG. Intra-operative real-time ultrasonic guidance of intracranial shunt tube placement in infants. *Radiology* **1982**;144:573-576
17. Edwards MK, Brown DL. Complicated infantile meningitis: evaluation by real-time sonography. *AJNR* **1982**;3:431-434