

Are your **MRI contrast agents** cost-effective?

Learn more about generic **Gadolinium-Based Contrast Agents**.



FRESENIUS
KABI

caring for life

AJNR

NMR imaging in the recognition of giant intracranial aneurysms.

B S Worthington, D M Kean, R C Hawkes, G N Holland, W S Moore and R Corston

AJNR Am J Neuroradiol 1983, 4 (3) 835-836

<http://www.ajnr.org/content/4/3/835>

This information is current as of May 2, 2024.

NMR Imaging in the Recognition of Giant Intracranial Aneurysms

B. S. Worthington,¹ D. M. Kean,¹ R. C. Hawkes,² G. N. Holland,^{2,3} W. S. Moore,² and R. Corston⁴

Most giant aneurysms present clinically as intracranial mass lesions. Many contain an organized lamellated thrombus with only a small eccentric lumen remaining that can be opacified at angiography. Four patients with such aneurysms were studied using flow-dependent nuclear magnetic resonance scanning sequences. The aneurysms show a smooth rounded margin, and the thrombus within is clearly distinguishable from the blood flowing through the patent lumen, which gives a low signal. By using different scan sequences it is possible to prove that the area of low signal is indeed fluid in rapid motion, thus confirming the diagnosis.

Although the classification of intracranial aneurysms by size is arbitrary, those with a diameter exceeding 25 mm are by convention called giant aneurysms [1]. In several large series of intracranial aneurysms they constituted about 5% of the total. Most are discovered because of their space-occupying qualities rather than because of spontaneous subarachnoid hemorrhage [2]. It is seldom possible to distinguish on clinical grounds alone a giant aneurysm from other space-occupying lesions around the base of the brain. Plain skull films are often normal but may reveal calcification in the wall if partial or complete thrombosis has occurred. Giant aneurysms are easily detected on computed tomography (CT) and their features are now well documented, but attention to detail is still required if a correct diagnosis is to be made [3, 4]. Care is particularly necessary with basal parasellar masses showing calcification and an enhancement pattern simulating meningioma. Giant basilar aneurysms have been confused with a retroclival chordoma [5].

Materials and Methods

We have studied four patients with giant aneurysms on the nuclear magnetic resonance (NMR) scanner at the Queen's Medical Centre, Nottingham. We believe that, apart from the rare totally thrombosed aneurysm, a precise and unequivocal diagnosis should be possible using two flow-dependent steady-state free-precession (SSFP) pulse sequences, which vary in their dependence on the length of the T_1 relaxation time. With our standard pulse sequence, regions with a T_1 greater than 800 msec give no signal, so that the ventricular cerebrospinal fluid (CSF) appears black, despite its high proton density; however, in a sequence embracing long T_1 values CSF gives a high signal and appears white. The sensitivity of both

multiple pulse techniques to motion (which modifies contrast by selective removal of signal from moving protons) allows us to infer from an application of both sequences that areas of zero signal on both represent fast-moving blood. The alternatives of zero proton density from a mass of dense bone or loculus of air would not apply in this context.

Results and Discussion

The first patient we studied with NMR had a giant aneurysm. She was a 59-year-old woman who presented with right orbital pain and double vision due to third nerve palsy [6]. Plain skull radiography showed a large ring of calcification in the right parasellar region extending into the middle cranial fossa. The true size of the aneurysm was indicated by the elevation of the middle cerebral artery; the residual lumen was far smaller, indicating the majority of its bulk was made up by thrombus within it. The parasagittal scan showed the outline of the aneurysm and the patent, eccentrically disposed lumen (which gave a zero signal) surrounded by organized clot.

The NMR scans of a middle-aged woman with a history of progressive visual failure are shown in figure 1. In the transverse NMR sections through the suprasellar region (fig. 1A) the ventricular CSF is black; in the modified sequence (fig. 1B) it appears white. In both, however, the midline circular lesion gives a zero signal. We hypothesized that it was a suprasellar aneurysm containing blood in rapid motion. Figures 1C and 1D show the coronal and sagittal sections through the aneurysm. The predicted diagnosis of giant aneurysm was confirmed by angiography.

Figure 2 is an NMR scan from a patient with a long history of temporal lobe epilepsy. CT had shown a mass with smooth margins lying in the position of the right sylvian fissure. The overall density was slightly higher than brain and there was an eccentric cleft of enhancement posteriorly. There was no surrounding edema. NMR shows that the area of enhancement on CT gave a zero signal, thus confirming the diagnosis of giant aneurysm. The high signal in the surrounding brain on the NMR scan is due to edema. There was no evidence of recent leakage of blood when it was explored and excised.

NMR is a reliable technique for demonstrating the presence of giant aneurysms and, except where thrombosis has completely obliterated the lumen, precise diagnosis is possible by flow-dependent sequences. Where the aneurysm is treated by carotid

¹ Department of Academic Radiology, Queen's Medical Centre, University of Nottingham, Nottingham NG7 2UH, England. Address reprint requests to B. S. Worthington.

² Department of Physics, University of Nottingham, Nottingham, England.

³ Present address: Picker International, Highland Heights, OH 44143.

⁴ Department of Neurology, University of Nottingham, Nottingham, England.

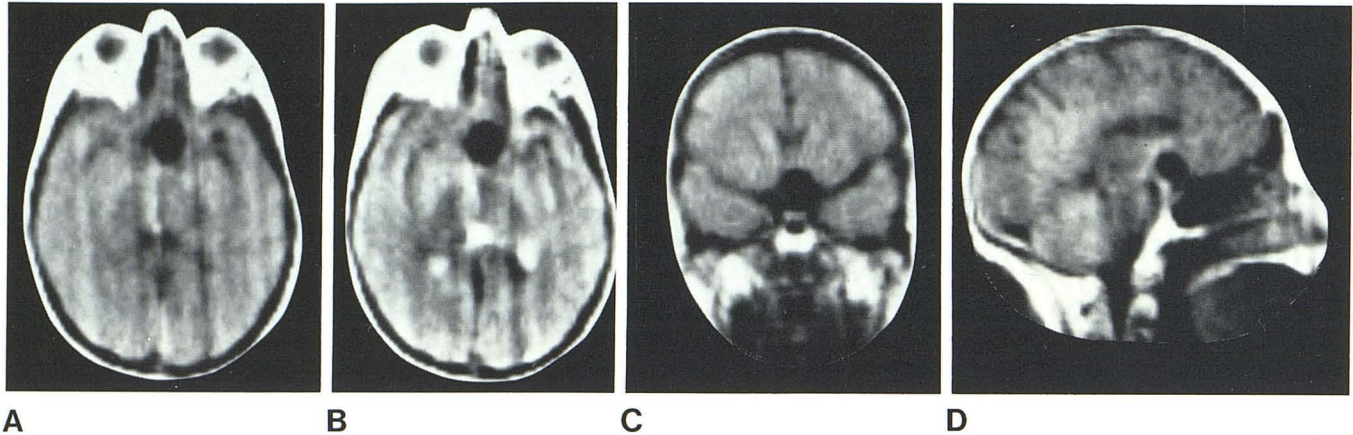


Fig. 1.—NMR scans in patient with giant suprasellar aneurysm. Contents of aneurysm gives zero signal with both spin sequences, indicating presence of blood in motion. On standard sequence (A) CSF appears black; on other

(B) CSF appears white (see text). Position of aneurysm and its relation to other brain features are well shown on coronal (C) and sagittal (D) sections.

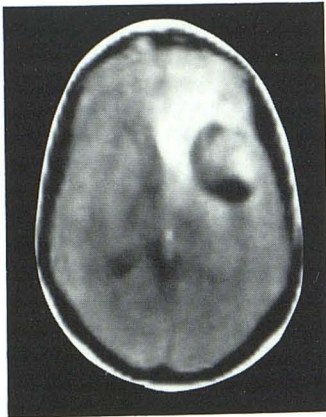

Fig. 2.—Axial transverse NMR scan in patient with giant middle cerebral artery aneurysm. Persisting lumen is a dark cleft posteriorly with laminated clot anteriorly. There is considerable edema anterior and medial to aneurysm.

ligation, follow-up studies can easily be carried out to document change in size and the occurrence of progressive thrombosis of the contents.

REFERENCES

1. Morely TP, Barr HWK. Giant intra-cranial aneurysms: diagnosis, cause and management. *Clin Neurosurg* 1968;16:73-94
2. Bull JWD. Massive aneurysms at the base of the brain. *Brain* 1969;92:535-570
3. O'Neill M, Hope T, Thomson G. Giant intra-cranial aneurysms: diagnosis with special reference to computerized tomography. *Clin Radiol* 1980;31:27-39
4. Golding R, Peatfield RC, Shaevdon HH, Rice-Edwards JM. Computer tomographic features of giant intra-cranial aneurysms. *Clin Radiol* 1980;31:41-48
5. Nadjmi M, Ratzka M, Wodarz M. Giant aneurysms in CT and angiography. *Neuroradiology* 1978;16:284-286
6. Hawkes RC, Holland GN, Moore WS, Worthington BS. Nuclear magnetic resonance (NMR) tomography of the brain: a preliminary assessment with demonstration of pathology. *J Comput Assist Tomogr* 1980;4:577-586