

Are your **MRI contrast agents** cost-effective?

Learn more about generic **Gadolinium-Based Contrast Agents**.



FRESENIUS
KABI

caring for life

AJNR

Dandy-Walker syndrome: recognition by sonography.

G A Taylor and R C Sanders

AJNR Am J Neuroradiol 1983, 4 (6) 1203-1206

<http://www.ajnr.org/content/4/6/1203>

This information is current as
of May 16, 2024.

Dandy-Walker Syndrome: Recognition by Sonography

George A. Taylor^{1,2}
Roger C. Sanders¹

The sonographic appearance of the Dandy-Walker malformation is not well known. Experience with sonography in the recognition of the Dandy-Walker syndrome in four neonates is presented. Three cases were discovered serendipitously: one during obstetric evaluation for uncertain gestational age and two in asymptomatic neonates. The typical sonographic features are a triangular posterior fossa cyst, a dilated aqueduct of Sylvius in communication with the cyst, elevation and hypoplasia of the cerebellum, and variable dilatation of the third and lateral ventricles. Sonography is often the first diagnostic procedure performed on these patients and can be very useful in recognizing the anomaly.

The Dandy-Walker malformation is an unusual cystic deformity in the posterior fossa; it is thought to be caused by a developmental abnormality of the fourth ventricle and cerebellum. Although the ability of sonography to detect this lesion has been reported in six patients [1-3], its sonographic appearance is not well known. Since sonography is often the first method in the evaluation of intracranial pathology, both in utero and in the neonatal period, we report our experience with its use in the recognition of Dandy-Walker cysts.

Materials and Methods

We reviewed the medical and sonographic records of four neonates with the Dandy-Walker malformation seen at our institution between March 1981 and August 1982. All neonatal examinations were performed with an ATL real-time unit using a 5 MHz transducer and standard coronal, sagittal, and axial views. Obstetric examinations were undertaken with a variety of commercially available real-time and B-mode static scanners. All sonographic diagnoses were confirmed by computed tomography (CT), clinical examination, or autopsy.

Case Reports

Case 1

A 30-day-old full-term female infant was transferred to the Johns Hopkins Hospital for evaluation of cyanotic congenital heart disease and multiple congenital anomalies. Her head circumference was within normal limits. An intracranial sonographic examination was performed to exclude intraventricular hemorrhage as the cause of her temperature instability and hypotonia. Sonography (figs. 1A and 1B) showed a small cystic lesion in the posterior fossa with superior displacement and hypoplasia of the cerebellar vermis. There was very minimal dilatation of the lateral ventricles. She died 6 days later because of worsening cyanosis and heart failure. A Dandy-Walker cyst was confirmed at autopsy (fig. 1C).

Received October 21, 1982; accepted after revision April 4, 1983.

¹Department of Radiology and Radiological Science, Johns Hopkins Hospital, Baltimore, MD 21205. Address reprint requests to R. C. Sanders.

²Present address: Department of Radiology, Children's Hospital, Boston, MA 02115.

AJNR 4:1203-1206, Nov/Dec 1983
0195-6108/83/0406-1203 \$00.00
© American Roentgen Ray Society

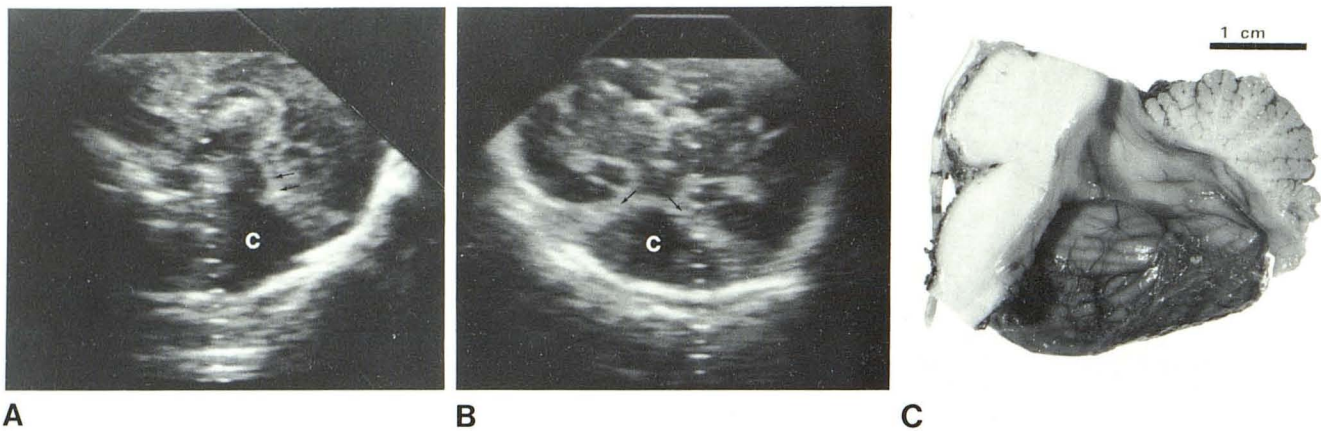


Fig. 1.—Case 1. **A**, Midline sagittal sonogram. Small cystic lesion (c) in posterior fossa communicates with third ventricle through dilated aqueduct of Sylvius (arrows). **B**, Coronal sonogram with posterior angulation shows fourth ventricle cyst (c) outlined anterolaterally by small mounds of hypoplastic cerebellum (arrows). Minimal temporal horn dilatation. **C**, Midline sagittal section of gross autopsy specimen confirms large fourth ventricle cyst with dilatation of aqueduct and hypoplastic vermis.

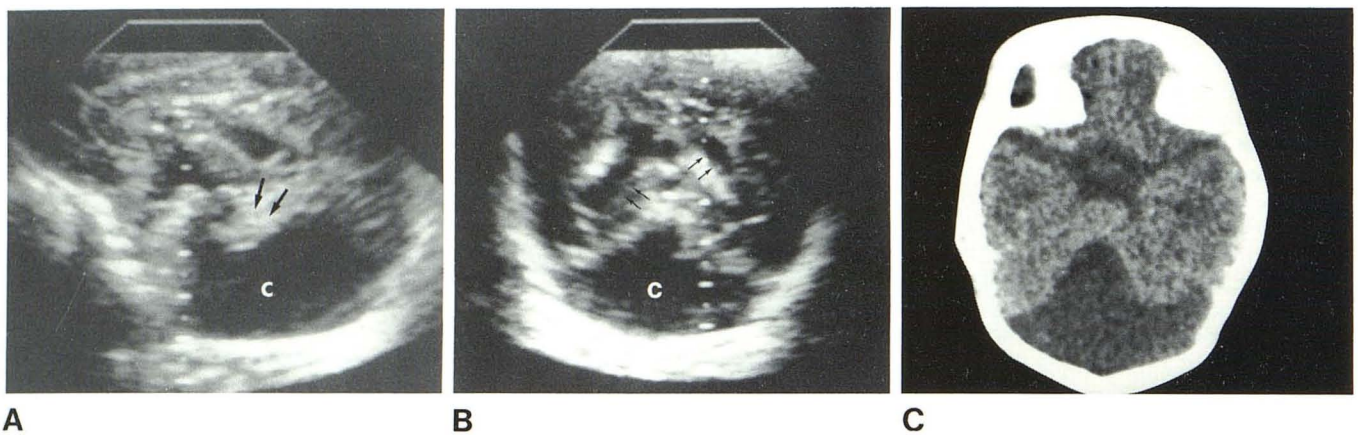


Fig. 2.—Case 2. **A**, Midline sagittal sonogram shows large fourth ventricle cyst (c). Vermis is displaced superiorly (arrows). **B**, Coronal sonogram. Large triangular cystic structure occupies most of posterior fossa (c). Dilated atria of lateral ventricle (arrows). **C**, CT scan shows cystic dilatation of fourth ventricle, with hypoplasia of cerebellar midline structures.

Case 2

A 31-week-old premature female infant with respiratory distress was examined by sonography because she was at high risk for intracranial hemorrhage from her prematurity. There were no neurologic symptoms. The study showed a triangular cyst of the posterior fossa with characteristic superior displacement and hypoplasia of the vermis and minimal hydrocephalus (figs. 2A and 2B). CT (fig. 2C) confirmed the diagnosis of cystic dilatation of the fourth ventricle. Serial follow-up examinations showed no progression of the hydrocephalus, and the patient remained asymptomatic without ventricular shunting.

Case 3

A 27-year-old gravida 1 with an uncomplicated early pregnancy was examined at 29 weeks of gestation because of rapidly increasing fundal height. A sonogram elsewhere revealed hydramnios and ventricular dilatation. She was referred to our institution for further evaluation. Repeat examination at 31 weeks (fig. 3A) showed a

large posterior fossa cyst with marked dilatation of the lateral and third ventricles compatible with a Dandy-Walker malformation. The patient experienced premature labor at 33 weeks and delivered a female infant with multiple congenital anomalies. These included hypertelorism, cloudy corneas, low-set ears with preauricular tags, and micrognathia. Sonography soon after birth (figs. 3B and 3C) confirmed a very large posterior fossa cyst. Direct communication between the cyst and the third ventricle could be demonstrated during real-time examination. Small remnants of the cerebellum were identified along the superior border of the tentorium. There was no progression of the hydrocephalus on subsequent examinations. No surgical procedure was performed, and the patient was being followed expectantly.

Case 4

A 24-year-old gravida 1 with a normal pregnancy through the second trimester was examined by sonography because of uncertain dates. Moderate fetal hydrocephalus with a posterior fossa cyst

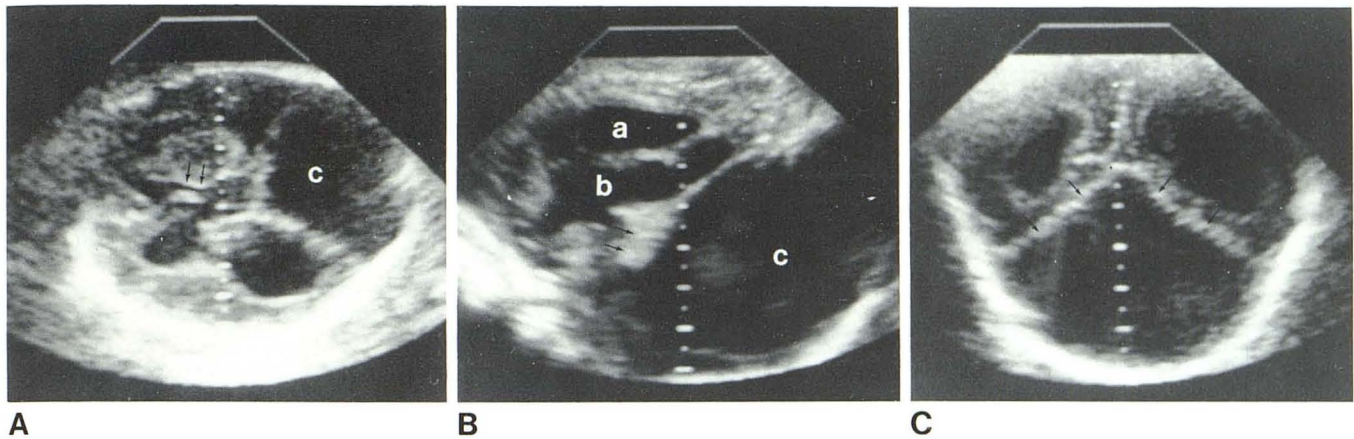


Fig. 3.—Case 3. **A**, In utero axial sonogram at level of foramen of Monro (arrows). Large cyst (c) occupies entire posterior fossa. Marked hydrocephalus. **B**, Oblique sagittal sonogram after birth. Dilatation of third ventricle (a) and left temporal horn (b), very large fourth ventricle cyst (c), and hypoplastic cerebellum anterior to fourth ventricle (arrows). **C**, Coronal sonogram. Thin rim of cerebellum outlines dilated fourth ventricle (arrows).

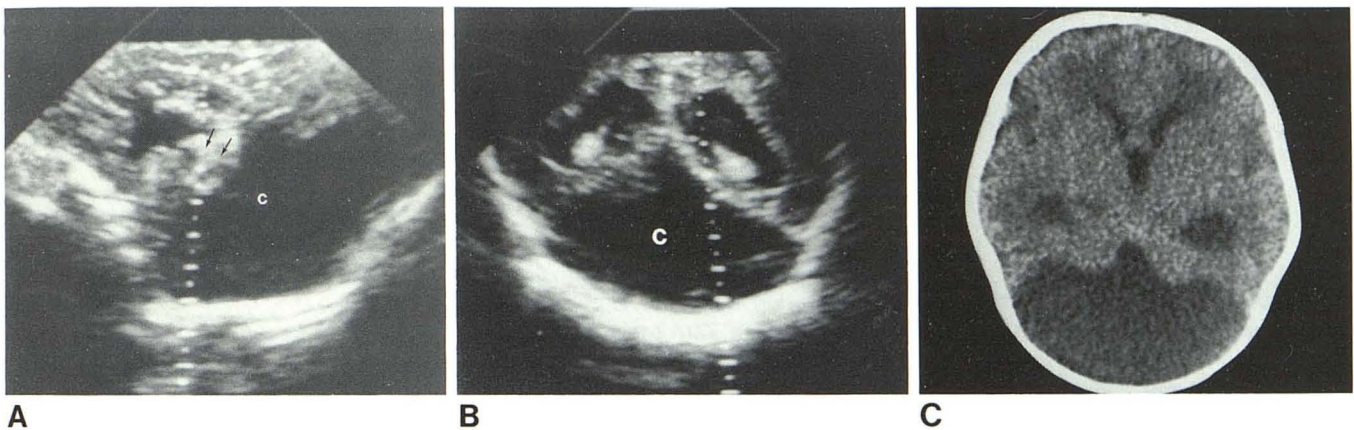


Fig. 4.—Case 4. **A** and **B**, Sagittal midline and coronal sonograms. Large cyst occupies entire posterior fossa (c) with superior displacement and hypoplasia of vermis (arrows). Note dilated ventricles. **C**, CT scan confirms cystic fourth ventricle and hypoplastic cerebellum.

was detected. Serial examination showed progressive ventricular dilatation, and the infant was delivered by elective cesarean section at 37 weeks of gestation. Sonography immediately after delivery and CT at 1 week of age (fig. 4) confirmed a Dandy-Walker malformation. A shunt was placed in the cyst at 6 weeks of age because of progressive hydrocephalus.

Discussion

The essential components of the Dandy-Walker malformation are hypoplasia of the cerebellar vermis, a posterior fossa cyst continuous with the fourth ventricle, a variable degree of hydrocephalus, and, frequently, atresia of the foramina of Luschka and Magendie [2, 4]. The lesion has been regarded by some as a dorsal neural tube defect similar to the Arnold-Chiari malformation. Others have considered it a true dysraphic disorder because of the relatively high (17%) incidence of coincident agenesis of the corpus callosum. Other malformations of the brain, including non-

specific gyral anomalies, posterior fossa lipoma, hamartoma, and aqueductal stenosis, have been reported [5-7].

Sonography was the first diagnostic study performed in all cases. A correct diagnosis was suggested in three. The small lesion in case 1 was initially interpreted as probably from an artifact in the posterior fossa. When reviewed by an experienced examiner, however, it was clear that the sonograms showed the typical features of a Dandy-Walker cyst.

Three of our cases were discovered serendipitously: one during obstetric evaluation of uncertain gestational age and two in newborn infants whose clinical examination was not suggestive of any structural abnormality in the posterior fossa. Case 2 remained asymptomatic with minimal, nonprogressive ventricular dilatation on follow-up examinations. This case raises the possibility of small fourth ventricle cysts remaining asymptomatic for long periods of time, perhaps indefinitely. It is interesting to speculate on how long the malformation would have remained undetected.

These posterior fossa cysts were best demonstrated on

coronal sonograms angled posteriorly, and showed a characteristic triangular appearance. On midline sagittal sonograms, a dilated aqueduct of Sylvius in direct communication with the cyst was seen, even in cases with small cysts and minimal hydrocephalus. Small mounds of tissue representing hypoplastic cerebellar structures were well visualized, except in cases having marked dilatation of the fourth ventricle. In the latter cases, only a thin rim of tissue could be discerned. As expected, various degrees of associated hydrocephalus were detected.

Differentiation between a Dandy-Walker cyst and other cystic lesions of the posterior fossa (such as arachnoid cysts or extraaxial posterior fossa cysts) may not always be possible with sonography. However, the latter two entities are not associated with midline cerebellar deformities and do not communicate directly with the ventricular system [1, 4, 8]. Sonography is often the first diagnostic procedure performed on these patients in the neonatal period and can be very useful in recognizing the abnormality.

ACKNOWLEDGMENTS

We thank John Reeder and Mary Henciak for assistance in manuscript preparation.

REFERENCES

1. Roach ES, Laster DW, Summer TE, Volberg FM. Posterior fossa arachnoid cyst demonstrated by ultrasound. *JCU* **1982**;10:88-90
2. Newman GC, Buschi AI, Sugg NK, et al. Dandy-Walker syndrome diagnosed in utero by ultrasonography. *Neurology (NY)* **1982**;32:180-184
3. Sauerbrei EE, Cooperberg PL. Neonatal brain: sonography of congenital anomalies. *AJNR* **1981**;2:125-128, *AJR* **1981**;136:1167-1170
4. Dempsey PJ, Koch HJ. In-utero diagnosis of the Dandy-Walker syndrome: differentiation from extra-axial posterior fossa cyst. *JCU* **1981**;9:403-405
5. Gardner E, O'Rahilly R, Prolo D. The Dandy-Walker and Arnold-Chiari malformations: clinical, developmental and teratological considerations. *Arch Neurol* **1975**;32:393-409
6. Padgett DH. Development of so-called dysraphism: with embryological evidence of clinical Arnold-Chiari and Dandy-Walker malformation. *Johns Hopkins Med J* **1972**;130:127-165
7. Sawaya R, McLaurin R. Dandy-Walker syndrome clinical analysis of 23 cases. *J Neurosurg* **1981**;55:89-98
8. Vaquero J, Carrillo R, Cabezudo J, et al. Arachnoid cyst of the posterior fossa. *Surg Neurol* **1981**;16:117-121