

Are your **MRI contrast agents** cost-effective?

Learn more about generic **Gadolinium-Based Contrast Agents**.



FRESENIUS
KABI

caring for life

AJNR

Digital subtraction arteriography for spinal arteriovenous malformation.

J M Levy, S J Hessel, F K Christensen and J K Crowe

AJNR Am J Neuroradiol 1983, 4 (6) 1217-1218

<http://www.ajnr.org/content/4/6/1217.citation>

This information is current as
of April 18, 2024.

Digital Subtraction Arteriography for Spinal Arteriovenous Malformation

Jonathan M. Levy,¹ Samuel J. Hessel,¹ Fred K. Christensen,² and John K. Crowe¹

Selective spinal cord angiography is the established method for evaluating patients with vascular lesions of the cord. This technique is technically demanding, and the examination takes considerable amounts of time and radiation [1]. Digital subtraction angiography (DSA) with venous injections produces arterial images with decreased patient risk. This procedure is also valuable in conjunction with direct arterial catheterization [2]. DSA was used to study the spinal cord in a patient with a spinal arteriovenous malformation (AVM).

Case Report

A 40-year-old man felt a sudden, sharp pain in the right subcostal region while straining to loosen a nut underneath his car. He went

to a hospital, where he was evaluated and released. Immediately after this episode, he began experiencing weakness in his legs, which was constant and nonprogressive. Three months later, he was referred to a neurosurgeon by his family practitioner, with a diagnosis of possible ruptured thoracic intervertebral disk.

On neurologic examination, the patient had generalized right leg weakness and could not hold his leg in the air against resistance. Left leg strength was within the range of normal. Position sense was absent on the right, and there was hypalgesia of the left leg. The findings were typical of a Brown-Séquard lesion at about T8 or T9.

A Pantopaque thoracic myelogram showed serpiginous vessels characteristic of spinal AVM (fig. 1A). A spinal arteriogram was obtained the next day. A selective Simmons I femorocerebral catheter [3] was placed in the thoracic aorta and manipulated into the first intercostal artery encountered. Two and one-half ml of Conray-60 (Mallinckrodt, St. Louis) diluted with 2.5

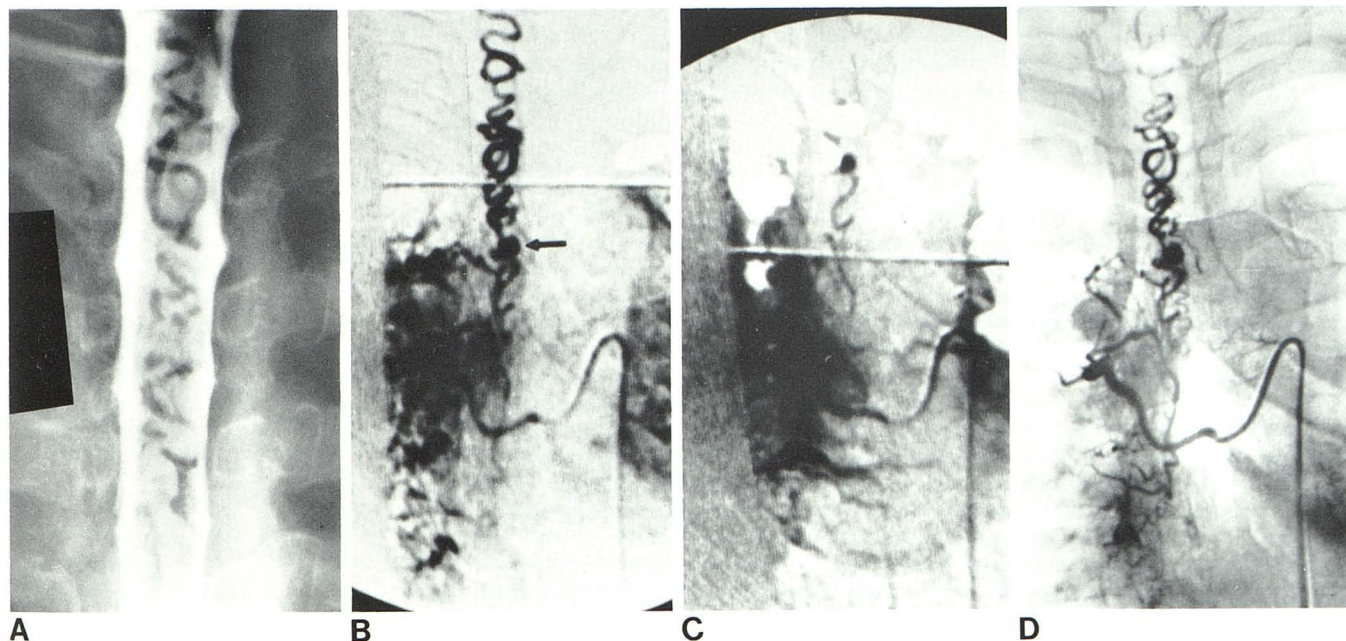


Fig. 1.—A, Myelogram shows serpiginous vessels characteristic of spinal AVM. B, DSA image of right sixth intercostal arteriogram. Small aneurysm (arrow) is opacified. C, Right seventh intercostal arteriogram shows slight opacification of AVM. D, Conventional (analog) subtraction arteriogram confirms findings in B.

Received September 7, 1982; accepted September 30, 1982.

¹ Department of Diagnostic Radiology, Scottsdale Memorial Hospital, 7400 E. Osborn Rd., Scottsdale, AZ 85251. Address reprint requests to J. M. Levy.

² Department of Neurosurgery, Scottsdale Memorial Hospital, Scottsdale, AZ 85251.

ml of normal saline was injected by hand into the intercostal artery after a preliminary mask image was taken with the digital subtraction machine. One image/sec was then obtained for 10 sec, and the mask was subtracted from the contrast images in real time. Multiple selective injections were done in this manner. The malformation was opacified by injection of the right sixth intercostal artery (fig. 1B). There was slight opacification of the malformation from the seventh right intercostal artery as well (fig. 1C), but no opacification from other sources. To confirm the DSA findings, routine film arteriograms were then obtained in anteroposterior and lateral projections with the catheter tip in the sixth right intercostal artery (fig. 1D). Total catheter time was 45 min, with a contrast dose equivalent to 40 ml of Conray-60.

The patient had surgery on hospital day 3 and was discharged 5 days later. Some residual loss of position sense in his right leg remained.

Discussion

The preoperative evaluation of an AVM of the spinal cord requires spinal cord arteriography, both for definitive diagnosis and for mapping of the vascular supply of the lesion [1]. This procedure involves selective injection of multiple intercostal, lumbar, and/or vertebral arteries for complete demonstration of the malformation; large amounts of contrast material must be used, and the procedure is time-consuming. The midthoracic segment of the cord is particularly sensitive to high doses of contrast material, as the anterior spinal artery in this region is small and collateral circulation is minimal [1]. Thus, in our patient, the location of the malformation required careful husbandry of the amount of contrast material used.

The use of DSA for spinal cord angiography has two major advantages. Since DSA has higher contrast sensitivity than conventional angiography [4], dilute contrast material can be used. This decreases the osmotic load on the spinal artery and cord, as well as the total amount of contrast material required for spinal cord angiography. DSA also produces images in real time; there is no additional time needed to load, develop, and if necessary subtract multiple angiographic runs. As soon as an artery is injected, the DSA images can be reviewed and the angiographic anatomy of the AVM defined. This decreases procedure time considerably over standard angiography, which is important in decreasing complications of the procedure [1]. The increased availability of DSA equipment should establish the procedure as the primary method for studying vascular abnormalities of the spine, as well as in other areas in which routine selective arteriography is a substantial risk to the patient.

REFERENCES

1. Di Chiro G, Wener L. Angiography of the spinal cord: a review of contemporary techniques and applications. *J Neurosurg* **1973**;39:1-29
2. Foley WD. Digital arterial portography. *Gen Elect X-ray Clin Symp* **1982**;1
3. Levy JM, Sheedy PF II, Fulton RE, Stanson AW. Use of the Simmons "sidewinder" femoral-cerebral catheter for abdominal angiography. *Radiology* **1979**;131:251
4. Mistretta CA, Crummy AB, Strother CM. Digital angiography: a perspective. *Radiology* **1981**;139:273-276