

Are your MRI contrast agents cost-effective?

Learn more about generic Gadolinium-Based Contrast Agents.



FRESENIUS
KABI

caring for life

AJNR

Robert H. Ackerman, MD, MPH (1935–2018)

M.H. Lev, J.M. Romero, L.H. Schwamm, M.E. Cudkowicz
and J.A. Brink

AJNR Am J Neuroradiol 2019, 40 (3) E12-E13

doi: <https://doi.org/10.3174/ajnr.A5989>

<http://www.ajnr.org/content/40/3/E12>

This information is current as
of April 19, 2024.

Robert H. Ackerman, MD, MPH (1935–2018)

Robert Harold Ackerman, MD, MPH, Emeritus Director of the Massachusetts General Hospital Neurovascular Laboratory and Associate Professor at Harvard Medical School, died on December 18 at 83 years of age after a long and productive career in the Departments of Neurology and Radiology. He was a pioneer in stroke imaging and prevention, who devoted his professional life to studying blood flow to the brain for the diagnosis and treatment of stroke and stroke-prone patients.

Bob grew up in New York City, attending Horace Mann School in Bronx-Riverdale. He received his BA degree from Brown University in 1957 and his MD degree from the University of Rochester in 1964. His immediate postcollege years—just at the start of the “Sputnik” era—were spent largely as a journalist in Great Britain; it was the subsequent “space race” however that, at least in part, sparked his enthusiasm for science. He interned at the Mary Imogene Bassett Hospital in Cooperstown, New York, and completed residencies in neurology (1970) and radiology (1975) at the Massachusetts General Hospital (MGH). Bob was unique in having earned Board Certification from both the American Boards of Radiology and Psychiatry and Neurology; he continued to practice clinically in these departments throughout his tenure at MGH.

Dr Ackerman trained under Drs C. Miller Fisher and Michael Moskowitz to become an international expert in the imaging evaluation of carotid disease and cerebral blood flow and metabolism; during his lengthy career he, in turn, served as a mentor to many of the leading stroke neurologists and neuroradiologists worldwide. He was an MGH Dalton Scholar at the Neurologic Institute Queen Square, London, from 1970 to 1971, where he studied cerebral blood flow techniques. In 1974, back at MGH, he founded the first consultative noninvasive neurovascular lab in the country. Since then, his research interests continued to focus on building a “diagnostic armamentarium” of noninvasive tools for the detection and management of patients with acute stroke or at risk of stroke.¹

From 1977 to 2009, Dr Ackerman served as Co-Principal Investigator with Dr Moskowitz on a National Institute of Neurological Disorders and Stroke–funded Interdepartmental Stroke Program Project Grant and was one of the first to image acute cerebral ischemia in vivo with positron-emission tomography. His seminal, highly cited 1981 article, “Positron Imaging in Ischemic Stroke Disease Using Compounds Labeled with Oxygen 15: Initial Results of Clinicophysiological Correlations,” reported alterations in brain tissue metabolism following stroke that are still highly relevant to current, novel “late window” (6–24 hours postonset) treatment trials.² He reported that in acute stroke, PET data on oxygen metabolism correlated better with tissue viability than data reflecting cerebral blood flow.

Dr Ackerman’s bibliography includes nearly 100 scientific publications on neurovascular disease. Bob helped develop and champion the use of extracranial and transcranial Doppler sonography as a safer, noninvasive alternative to conventional angiography for the diagnosis and monitoring of carotid artery stenosis.



FIG 1. Robert Ackerman.

He was also among the first to advance the “new” technology of head CT scanning—as an extension of the neurologic physical examination—when, in 1974, MGH installed what was then the second CT scanner in North America.

From July 1991 to June 1992, Dr Ackerman was selected as Distinguished Scientist in the Department of Radiologic Pathology at the Armed Forces Institute of Pathology, where he made important contributions to research and education.³ In 2013, he was honored at an MGH Ether Dome ceremony, where it was announced that the Neurovascular Laboratory would be renamed the R.H. Ackerman Neurovascular Lab; Ackerman served as its director until 2001, and subsequently as emeritus director.

The list of trainees and colleagues who rotated through Bob’s neurovascular lab reads like a “Who’s Who” of vascular neurology. Notables include but are not limited to “first ever” cerebral blood flow fellow Dr Jean-Claude Baron, followed closely by IV-tPA and Mobile Stroke Unit innovator Dr Jim Grotta—both members of the “original” MGH “stroke team”—as well as Dr Stephen Davis, Director of the Melbourne Brain Centre at the Royal Melbourne Hospital and Immediate Past President of the World Stroke Organization. Dr Ackerman mentored and helped advance the neurology-related careers of numerous other former neurovascular lab fellows, among them Dr Viken Babikian (Boston University Medical Center Vascular Diagnostic Lab), Dr Kevin Barrett (Mayo Clinic, Jacksonville), and Drs Shin, Romero, and Lev (all currently at MGH). Through his many collaborations



FIG 2. Javier Romero, Robert Ackerman, and Michael Lev.

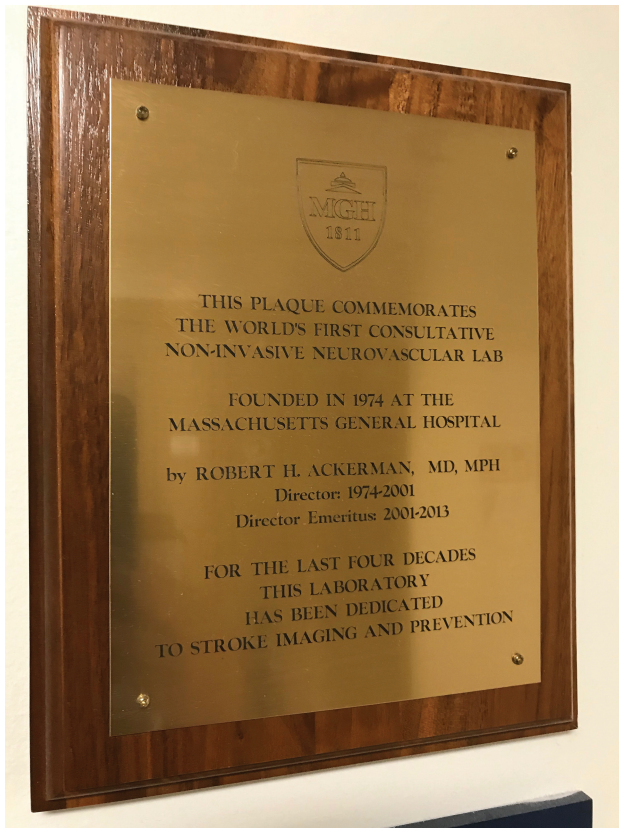

FIG 3.



FIG 4. The “first-ever” MGH stroke team, from left to right and top to bottom: Gouliamos (2nd CBF fellow), Nat Alpert, Jack Correia, Mrs Taveras, Prof Juan Taveras, Bob’s Doppler technician, Bob Ackerman, Jean Claude Baron (1st CBF fellow), Wang (physicist/IT engineer), John (2nd CBF technician on the PET stroke grant).

and during his several years leading the Boston Stroke Society, Bob remained a highly valued and respected member of the vascular neurology community and interacted closely with such luminaries as Drs C. Miller Fisher, Juan Taveras, Ken Davis, Jay P. Mohr, J. Philip Kistler, Louis Caplan, Geoffrey Donnan, Gordon Brownell, Carlos Kase, Walter Koroshetz, Ferdi Buonanno, Lee Schwamm, Gil Gonzalez, and Michael Pessin.⁴

Bob’s achievements and contributions were celebrated at a dinner he attended last October, hosted by MGH Neuroradiology Division Chief Dr R. Gil Gonzalez. In tributes posted this past week, his friends, patients, and fellow members of the Cambridge




FIG 5.

Rowing Club praised his thoughtful and caring nature, positive attitude and intellect, and skill and persistence in tracking down and treating the “causes of illness”; many remarked that Bob was a “true gentleman” who “took care of friends near and far,” and “always made me feel good.” Perhaps Dr Stephen Davis best summed up the feelings of all when he observed:

“He was a wonderful mentor and highly valued friend. He has contributed hugely to the developments in stroke diagnosis and treatment. He performed early seminal work on the imaging of ischemic penumbra at the Massachusetts General Hospital and Harvard University. He was a leader in the evaluation of carotid artery disease and its clinical significance. He has been a great teacher and mentor to many stroke neurologists. He was a renaissance man, a lover of literature and music. He will also be remembered for his enthusiasm for rowing and of course his beloved home in Gloucester. He will be sorely missed.”

Dr Ackerman will be remembered by friends, colleagues, and family as a devoted teacher, scholar, and mentor, as well as an avid rower who competed for decades in the Head of the Charles Regatta and a raconteur with a deep knowledge of medical history. His wit, wisdom, gentle humor, and keen insights will indeed be sorely missed by his patients and by all who knew him; his impact and legacy will continue.

REFERENCES

1. Ackerman RH. **Neuroimaging looks to the future.** *J Neurol Sci* 1995; 128:117–21 CrossRef Medline
2. Ackerman RH, Correia JA, Alpert NM, et al. **Positron imaging in ischemic stroke disease using compounds labeled with oxygen 15: initial results of clinicophysiological correlations.** *Arch Neurol* 1981;38: 537–43 CrossRef Medline
3. Buck JL. **Robert H. Ackerman, MD, Distinguished Scientist, Department of Radiologic Pathology, Armed Forces Institute of Pathology.** *Radiology* 1991;180:281 <https://doi.org/10.1148/radiology.180.1.281>. Accessed 23 December, 2018
4. Ackerman RH. **Celebrating the life of C. Miller Fisher.** *Int J Stroke* 2012;7:444–46 CrossRef Medline

M.H. Lev
J.M. Romero
L.H. Schwamm
M.E. Cudkovic
J.A. Brink

<http://dx.doi.org/10.3174/ajnr.A5989>