

Are your MRI contrast agents cost-effective?

Learn more about generic Gadolinium-Based Contrast Agents.



FRESENIUS
KABI

caring for life

AJNR

**Celebrating 35 Years of the AJNR: May 1985
edition**

AJNR Am J Neuroradiol 2020, 41 (5) 941

doi: <https://doi.org/10.3174/ajnr.P0099>

<http://www.ajnr.org/content/41/5/941.citation>

This information is current as
of April 19, 2024.

Celebrating 35 Years of the AJNR

May 1985 edition

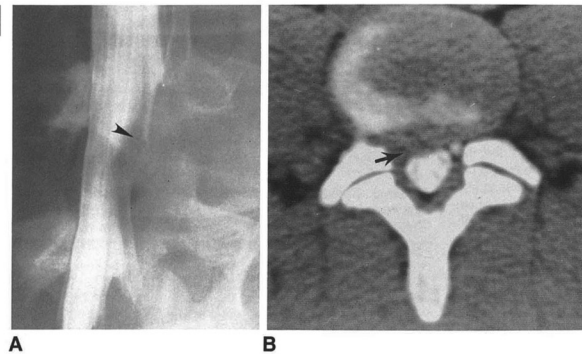
Chymopapain Chemonucleolysis: Correlation of Diagnostic Radiographic Factors and Clinical Outcome

Lindell R. Gentry^{1,2}
Charles M. Strother¹
Patrick A. Turski³
Manucher J. Javid³
Joseph F. Sackett¹

The therapeutic response to treatment of lumbar disk herniation with chymopapain chemonucleolysis is significantly influenced by the criteria used for patient selection. Although careful clinical selection of patients reduces the frequency of treatment failure, some patients do not achieve satisfactory relief of pain with chemonucleolysis. In an attempt to identify objective pretreatment radiographic findings that might refine selection criteria and further reduce the failure rate of chemonucleolysis, a retrospective correlation of pretreatment radiographs and clinical responses was made of 200 consecutive chemonucleolysis patients. Marked improvement in sciatica occurred in 79.9% and 73.2% of patients at early and late follow-up, respectively. There was a significantly higher response rate, however, in patients who had definite radiographic evidence of focal disk herniation and in those patients with definite radiographic evidence of nerve-root compression (marked nerve-root deviation, nerve-root flattening or edema, root-sleeve amputation) by disk material. Those patients with a preinjection disk height greater than the mean had a slightly better response rate (91.1%) than those whose disk height was smaller than the mean (80.0%). Most cases of treatment failure could be attributed to an incorrect radiographic diagnosis, treatment of patients with equivalent diagnosis studies, the presence of "free" disk fragments, and causes of nerve-root compression unresponsive to chymopapain.

Chymopapain, a proteolytic enzyme derived from papaya latex, catalyzes the rapid hydrolysis of the chondromucoprotein part of the nucleus pulposus of the intervertebral disk. In 1964, Smith [1] first demonstrated the possibility of using chymopapain to enzymatically treat lumbar disk herniations (chymopapain chemonucleolysis). Clinical trials designed to establish the safety and efficacy of this procedure quickly followed.

By 1975, over 17,000 people had been treated with chymopapain chemonucleolysis in 75 centers [2, 3]. Wide variations were reported in the frequency of successful results, ranging from 50% to 80%, and controversy concerning its



This article appears in the May/June 1985 issue of *AJNR* and the August 1985 issue of *AJR*.
Received December 27, 1983; accepted after revision May 3, 1984.

Presented in part at the annual meeting of the American Society of Neuroradiology, San Francisco, June 1983.

¹ Department of Radiology, University of Wisconsin Hospital and Clinics, Madison, WI 53792.

² Present address: Department of Radiology, University of Iowa Hospitals and Clinics, 7006 Carver, Iowa City, IA 52242. Address reprint requests to L. R. Gentry.

³ Division of Neurosurgery, University of Wisconsin Hospital and Clinics, Madison, WI 53792.
AJNR 6:111-120, May/June 1985
0195-6108/85/0603-0311
© American Roentgen Ray Society

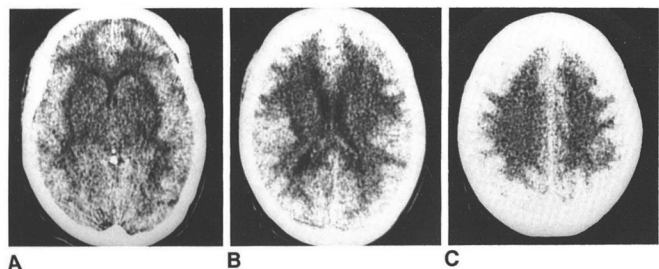
395

Computed Tomographic Changes of Hypertensive Encephalopathy

Karen L. Weingarten¹
Robert D. Zimmerman²
Richard S. Pinto¹
Margaret A. Whelan¹

Computed tomographic (CT) scans of hypertensive encephalopathy. Hypertensive severe rise in blood pressure associates mental status, and focal neurologic deficits. The systolic blood pressure 170 mm Hg. The most common CT finding affecting the supratentorial compartment in eight. These changes resolved after it studied by follow-up CT. Permanent in patients. These abnormalities are correct hypertensive encephalopathy.

Hypertensive encephalopathy is an hypertension is associated initially with convulsions, stupor, and coma [1-4]. F and renal failure are usually present. seen after institution of antihypertensive findings in 11 patients with hypertension to the pathogenesis of this condition.



Materials and Methods

The hospital records and CT scans of 11 patients with hypertensive encephalopathy from Montefiore Medical Center and New York University Medical Center were reviewed. In all cases, CT scans were obtained during the acute phase of blood pressure elevation. Six patients had follow-up CT scans.

The six male and five female patients were 10-59 years old (mean, 46). The diagnosis of hypertensive encephalopathy was made by the clinical criteria of an acute, severe rise in blood pressure associated with headache, nausea, vomiting, altered mental status, and focal neurologic deficits, and rapid improvement after control of blood pressure. The range of systolic blood pressure was 200-280 mm Hg (mean, 250 mm Hg); the range of diastolic pressure was 130-170 mm Hg (mean, 130 mm Hg).

Results

The CT findings in hypertensive encephalopathy can be divided into supratentorial and infratentorial abnormalities. All cases demonstrated supratentorial abnormalities in the acute stage of hypertensive encephalopathy, characterized by edema and expansion of the white matter, compression of the ventricles, and obliteration of sulci and cisternal spaces (figs. 1-5). This diffuse white-matter edema resolved after the blood pressure was lowered in all patients in whom follow-up scans were obtained (figs. 2-5). Other supratentorial abnormalities observed during the acute phase of the disease were ganglionic edema in two patients (fig. 1), bilateral

Received May 30, 1984; accepted after revision September 20, 1984.

Presented at the annual meeting of the American Society of Neuroradiology, San Francisco, June 1983.

¹ Department of Radiology, New York University Medical Center, 560 First Ave., New York, NY 10016. Address reprint requests to K. L. Weingarten.

² Department of Radiology, New York Hospital-Cornell Medical Center, New York, NY 10021.

AJNR 6:395-398, May/June 1985
0195-6108/85/0603-0395
© American Roentgen Ray Society