

Are your MRI contrast agents cost-effective?
Learn more about generic Gadolinium-Based Contrast Agents.



AJNR

Erratum

AJNR Am J Neuroradiol 2020, 41 (8) E72
doi: <https://doi.org/10.3174/ajnr.A6660>
<http://www.ajnr.org/content/41/8/E72>

This information is current as
of April 19, 2024.

In the article “A Practical Review of Functional MRI Anatomy of the Language and Motor Systems” (Hill VB, Cankurtaran CZ, Liu BP, et al. *AJNR Am J Neuroradiol* 2019;40:1084–90) the legend for Fig 1 contained an error. The correct legend is the following:

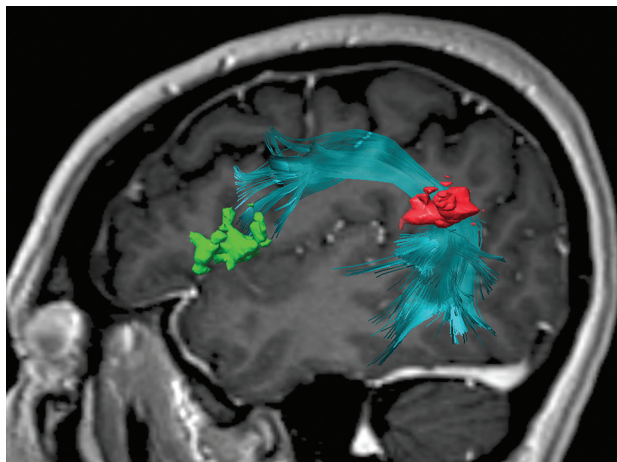


FIG 1. Sagittal 3D-FLAIR image with a superimposed diffusion tensor image of the arcuate fasciculus between the inferior frontal gyrus (pars opercularis and pars triangularis) (green) and the angular gyrus (red). The frontotemporal segment of the arcuate fasciculus connects the Broca area at the inferior frontal gyrus with the Wernicke area more posteriorly, traditionally at the posterior-superior temporal gyrus. However, this connection is variable, and in this case, it is at the angular gyrus/posterior superior temporal area. The authors regret the error.

<http://dx.doi.org/10.3174/ajnr.A6660>