

**Are your MRI contrast agents cost-effective?**

Learn more about generic Gadolinium-Based Contrast Agents.



**FRESENIUS  
KABI**

caring for life

**AJNR**

**Fair Performance of CT in Diagnosing  
Unilateral Vocal Fold Paralysis**

F. Deng

*AJNR Am J Neuroradiol* 2022, 43 (12) E64

doi: <https://doi.org/10.3174/ajnr.A7593>

<http://www.ajnr.org/content/43/12/E64>

This information is current as  
of February 17, 2025.

## Fair Performance of CT in Diagnosing Unilateral Vocal Fold Paralysis

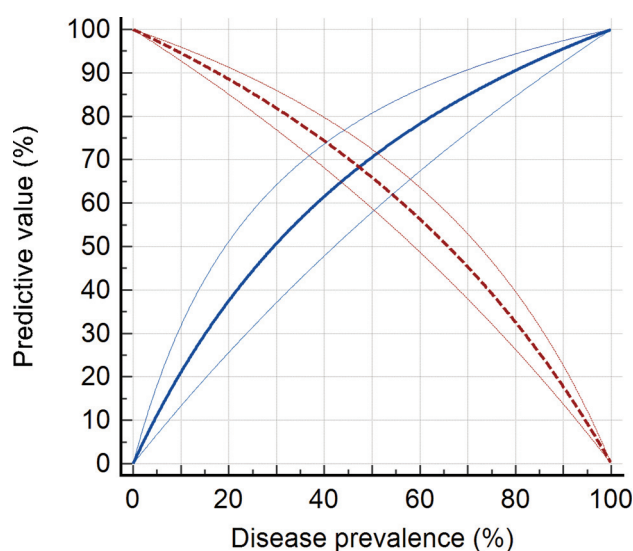
**B**ashir et al<sup>1</sup> reported the diagnostic performance of CT signs of unilateral vocal fold paralysis as evaluated by blinded radiologists. They highlighted the 2 best signs combined, medialization of the posterior vocal fold margin and laryngeal ventricle dilation, as having a positive predictive value of 87%, specificity of 74%, and interrater reliability of  $\kappa = 0.50$ – $0.54$ . The authors concluded that these CT signs should raise concern for ipsilateral vocal fold paralysis. However, important limitations apply.

The first limitation pertains to the study design. In this retrospective, case-control study, only patients who underwent laryngoscopy by an otolaryngologist were included, while patients were excluded if they had a history of cancer, trauma, radiation, or surgery involving the larynx or pharynx. Spectrum bias arises when the study sample differs in case mix from that encountered in the clinical setting where these signs are intended to be used.<sup>2</sup> Patients who undergo laryngoscopy may have more advanced disease, such as obvious dysphonia, resulting in overestimation of sensitivity. Excluding controls likely to have anatomic distortions for other reasons results in overestimation of specificity. This study may not generalize to many common scenarios for neck CT, such as surveillance for head and neck cancer or trauma.

The second limitation pertains to the results interpretation. Predictive values depend on the underlying disease prevalence (Figure), especially when the inherent test characteristics are overall fair as in this case (sensitivity 62%, specificity 74%). Case-control studies typically do not reflect the prevalence of disease in the relevant clinical population, rendering predictive values misleading.<sup>2,3</sup> The positive predictive values in this study are inflated from those expected in real clinical practice because the prevalence of unilateral vocal fold paralysis was 73%. If the prevalence is 10%, which is still likely an overestimate on typical neck CTs in my opinion, the positive predictive value of these CT signs would only be 21%.

I agree with the authors' conclusion that "care must be taken to translate suspicious findings appropriately." Clinicians should consider the patient's risk factors and pretest probability of vocal fold paralysis, as well as the fair diagnostic performance and reliability of these CT signs, demonstrated in this study within the limitations of its design.

<http://dx.doi.org/10.3174/ajnr.A7593>



**FIGURE.** Conditional probability for the diagnosis of unilateral vocal fold paralysis based on CT. Predictive values (blue/solid lines, positive predictive value; red/dashed lines, negative predictive value) with 95% confidence intervals (thin lines) were calculated from the sample sizes and estimated sensitivity and specificity of the 2-sign model in Bashir et al,<sup>1</sup> using a standard logit method (MedCalc, Version 20.109; MedCalc Software).

Disclosure forms provided by the authors are available with the full text and PDF of this article at [www.ajnr.org](http://www.ajnr.org).

### REFERENCES

1. Bashir MH, Joyce C, Bolduan A, et al. Revisiting CT signs of unilateral vocal fold paralysis: a single, blinded study. *AJNR Am J Neuroradiol* 2022;43:592–96 CrossRef Medline
2. Pavlou A, Kurtz RM, Song JW. Diagnostic accuracy studies in radiology: how to recognize and address potential sources of bias. *Radiol Res Pract* 2021;2021:e5801662 CrossRef Medline
3. Deng F. Reporting predictive values for diagnostic tests. *AJR Am J Roentgenol* 2018;211:W278 CrossRef Medline

**F. Deng**

The Russell H. Morgan Department of Radiology and  
Radiological Science  
Johns Hopkins University School of Medicine  
Baltimore, Maryland