

Generic Contrast Agents

Our portfolio is growing to serve you better. Now you have a *choice*.



[VIEW CATALOG](#)

AJNR

WEB Treatment of Ruptured Intracranial Aneurysms: Long-Term Follow-up of a Single-Center Cohort of 100 Patients

H. Kortman, S.B.T. van Rooij, U. Mutlu, I. Boukrab, W.J. van Rooij, B. van der Pol, B. Burhani and J.P.P. Peluso

This information is current as of May 3, 2025.

AJNR Am J Neuroradiol 2023, 44 (1) 60-64

doi: <https://doi.org/10.3174/ajnr.A7748>

<http://www.ajnr.org/content/44/1/60>

WEB Treatment of Ruptured Intracranial Aneurysms: Long-Term Follow-up of a Single-Center Cohort of 100 Patients

 H. Kortman,  S.B.T. van Rooij,  U. Mutlu,  I. Boukrab,  W.J. van Rooij,  B. van der Pol, B. Burhani, and  J.P.P. Peluso



ABSTRACT

BACKGROUND AND PURPOSE: The Woven EndoBridge device (WEB) was introduced for the intrasaccular treatment of wide-neck aneurysms without the need for adjunctive devices. We used the WEB as a primary treatment for 100 ruptured aneurysms regardless of neck size or location. In this study, we present the long-term follow-up of 78 surviving patients.

MATERIALS AND METHODS: Between February 2015 and April 2017, one hundred ruptured aneurysms were treated with the WEB. For surviving patients, angiographic and clinical follow-up was scheduled at 3 months, and 3T MRA and clinical follow-up, at 6, 12, 36, and 60 months. Of 100 patients, 18 died during hospital admission, and in 4, the ruptured aneurysm was additionally treated. The remaining 78 patients had a mean follow-up of 51 months (median, 52 months; range, 5–84 months). There were 57 women and 21 men, with a mean age of 58.5 years (median, 59 years; range, 24–80 years). Of 78 aneurysms with long-term follow-up, 52 (66%) had a wide neck.

RESULTS: Of 78 ruptured aneurysms, 56 (72%) remained completely occluded and 17 (22%) had a stable small neck remnant. Five of 78 aneurysms (6%; 95% CI, 2.4%–14.5%) reopened during follow-up and were additionally treated. There were no rebleeds during follow-up.

CONCLUSIONS: Treatment of ruptured aneurysms with the WEB was safe and effective and has long-term results comparable with those of simple coiling of small-neck aneurysms. The WEB proved to be a valuable alternative to coils for both wide- and small-neck ruptured aneurysms without the need for stents, balloons, or antiplatelet therapy.

Endovascular treatment is recognized as the first therapeutic option for ruptured and unruptured intracranial aneurysms.¹ Endovascular treatment of wide-neck bifurcation aneurysms is challenging, and these aneurysms are associated with a higher rate of recanalization.² Bridging neck devices such as stents require dual-antiplatelet therapy and are associated with a higher rate of complications. With this anti-aggregation regimen, stent-assisted coiling in ruptured aneurysms has a higher inherent risk of early rebleed or hemorrhage in the postoperative period.^{3–5} Despite anti-aggregation, thromboembolic complications still occur.^{6,7}

Primarily for the endovascular treatment of wide-neck bifurcation aneurysms, the intrasaccular flow disruptor Woven

EndoBridge (WEB; MicroVention) has been developed, without the need for adjunctive devices. The first clinical results of the WEB device show good safety and efficacy.⁸ However, publications investigating WEB treatment for ruptured aneurysms are limited with short-term follow-up of up to 1 year on average.^{9,10} We published our first series of 100 ruptured aneurysms treated with the WEB device,¹¹ and in this publication, we will report the long-term follow-up.

MATERIALS AND METHODS

This observational study with prospectively collected data was compliant with our institutional privacy policy. The institutional review board gave exempt status for approval and informed consent. The study was performed in the Elisabeth Tweesteden Ziekenhuis in Tilburg, the Netherlands.

Population

This is the long-term follow-up of the previously published¹¹ cohort of 100 patients with ruptured aneurysms who were treated with the WEB between February 2015 and April 2017.

Received August 23, 2022; accepted after revision November 25.

From the Division of Neuroradiology (H.K., U.M., I.B.), Department of Radiology, and Department of Neurosurgery (B.v.d.P., B.B.), Elisabeth Tweesteden Ziekenhuis Hospital, Tilburg, the Netherlands; Department of Radiology (S.B.T.v.R.), Catharina Ziekenhuis, Eindhoven, the Netherlands; Department of Radiology (W.J.v.R.), Algemeen Ziekenhuis Turnhout, Turnhout, Belgium; and Division of Neuroradiology (J.P.P.), Department of Radiology, Universitair Ziekenhuis Leuven, Leuven, Belgium.

Please address correspondence to Hans Kortman, MD, Division of Neuroradiology, Department of Radiology, ETZ Elisabeth Hospital, PO Box 90151, 5000 LC Tilburg, the Netherlands; e-mail: h.kortman@etz.nl

<http://dx.doi.org/10.3174/ajnr.A7748>

WEB Device

The WEB is a self-expanding, retrievable, electrothermally detachable, nitinol braided device, which is placed in the aneurysm sac. The device existed in several iterations: initially, WEB dual-layer (WEB-DL), followed by a single layer in 2 shapes (barrel: WEB Single-Layer [SL], and spherical: WEB Single-Layer Sphere [SLS]), followed by a version that enhanced visualization (WEB-SL EV and WEB-SLS EV) by incorporating composite wire strands made from nitinol and platinum. The WEB-SL device is available in diameters ranging from 4 to 11 mm and heights ranging from 3 to 9 mm. The WEB-SLS has a spherical shape and is available in diameters ranging from 4 to 11 mm, each with a fixed height ranging between 2.6 and 9.6 mm. The WEBs with diameters of 4–7 mm can be delivered through a 0.021-inch internal diameter microcatheter; the WEBs with diameters of 8–9 mm, through a 0.027-inch microcatheter; and the WEBs with diameters of 10–11 mm, through a 0.033-inch microcatheter (VIA 21, 27, and 33; MicroVention). Last, a lower-profile range of WEBs compliant with a 0.017-inch microcatheter (VIA 17) has become available in clinical practice. Placed in the aneurysm, the WEB modifies the blood flow at the level of the neck and induces aneurysmal thrombosis. The WEB can be fully retrieved until final detachment by an electrothermal detachment system contained in a hand-held controller.

General Indications and Treatment

In our institution, the indication and technique of aneurysmal treatment are based on a multidisciplinary discussion for all admitted patients. However, the treatment of patients with ruptured aneurysms is primarily endovascular within 24 hours after admission. Because of previous poor results with stent-assisted coiling in ruptured aneurysms,⁷ from January 2015 onward, we tried to avoid using stents with inherent antiplatelet medication. Wide-neck aneurysms were treated with either the WEB device with coiling or surgical clipping. Immediate surgery was an option in good-grade patients with wide-neck anterior circulation aneurysms. In poor-grade patients with wide-neck aneurysms not suitable for endovascular treatment, the operation was generally postponed several days. The WEB device was initially developed for the treatment of wide-neck intracranial aneurysms as an alternative to balloon- or stent-assisted treatment. After our first encouraging experiences in unruptured wide-neck aneurysms, during the study period, we gradually expanded the indication to all aneurysms suitable for the WEB regardless of neck size, location, or rupture status.

With the patient under general anesthesia and using a femoral approach, a microcatheter was advanced into the aneurysm via a coaxial or triaxial approach. Hence, the aneurysm was occluded with coils or with a WEB. The WEB was slightly oversized according to the recommendations of the manufacturer. WEB sizes and shapes were recorded. WEB-DLs were not used. Apart from a single bolus of 5000 IU of heparin IV and continuous heparin in the pressure bags for flushing (1000 IU/L), no additional anticoagulation was used.

Data Collection and Follow-up

Patient demographics, treatment, and aneurysm characteristics were collected. Clinical grading during admission was according

to the Hunt and Hess scale, and clinical follow-up was classified in the mRS. For surviving patients, angiographic follow-up was scheduled at 3 months, and 3T MRA follow-up at 6, 12, 36, and 60 months. All imaging follow-up was accompanied by a clinical follow-up visit. Imaging data were interpreted by 2 experienced interventional neuroradiologists (H.K. and I.B.).

Statistical Analysis

Quantitative variables were expressed as means with descriptive statistics, and qualitative variables were expressed as frequencies or percentages with corresponding 95% confidence intervals.

RESULTS

Population

Between February 2015 and April 2017, two hundred forty-two patients with ruptured aneurysms were treated in our institution. Of these, 100 patients with ruptured aneurysms were selectively treated with the WEB. The results of this study are published elsewhere.¹¹ Seventeen patients (17%) died during hospitalization as a consequence of SAH. One patient (1%) died after a thromboembolic complication during WEB placement; and, we additionally treated 4 aneurysms (4%): In 1 patient with a 13-mm ruptured pericallosal artery aneurysm, a WEB was placed to protect the dome only. This aneurysm was later additionally clipped. In 1 patient, the WEB was undersized, but this feature was only noticed after detachment. Follow-up angiography after 1 week showed an aneurysm remnant that was then occluded with coils. In 2 patients, coils were placed in the aneurysm daughter sac through a jailed second microcatheter before a detachment of the WEB in the main dome of the aneurysm. The remaining 78 patients are the subjects of this study.

There were 21 men and 57 women, with a mean age of 58.5 years (median, 59 years; range, 24–80 years). The clinical condition at the time of treatment was Hunt and Hess 1–2 in 48 patients, 3 in 24 patients, and 4–5 in 6 patients. The timing of treatment after SAH was 0–1 day in 68 patients, 2–4 days in 5 patients, and >4 days in 5 patients. The aneurysm location was the anterior communicating artery in 35 patients, the posterior communicating artery in 15 patients, the middle cerebral artery in 15 patients, the pericallosal artery in 4 patients, the basilar tip in 4 patients, the superior cerebellar artery in 3 patients, the carotid tip in 1 patient, and the ophthalmic artery in 1 patient. The mean aneurysm size was 5.4 mm (median, 5 mm; range, 3–12 mm). Of 78 aneurysms, 52 (66%) had a wide neck, defined as ≥ 4 mm or a dome-to-neck ratio of ≤ 1.5 . Four patients had 1 additional unruptured aneurysm treated in the same session, 1 with WEB and 3 with coils. One patient had 3 additional unruptured aneurysms treated with the WEB in the same session.

Follow-up

The mean follow-up of 78 patients was 51 months (median, 52 months; range, 5–84 months). Sixty-four patients (82%) had all imaging and clinical visits. The mean follow-up in this subgroup was 56 months (median, 54 months; range, 41–84 months). Fourteen patients (18%) discontinued follow-up; 9 opted out of scheduled follow-up visits. Three patients ended up depending on long-term care after SAH, and the family opted out of follow-up

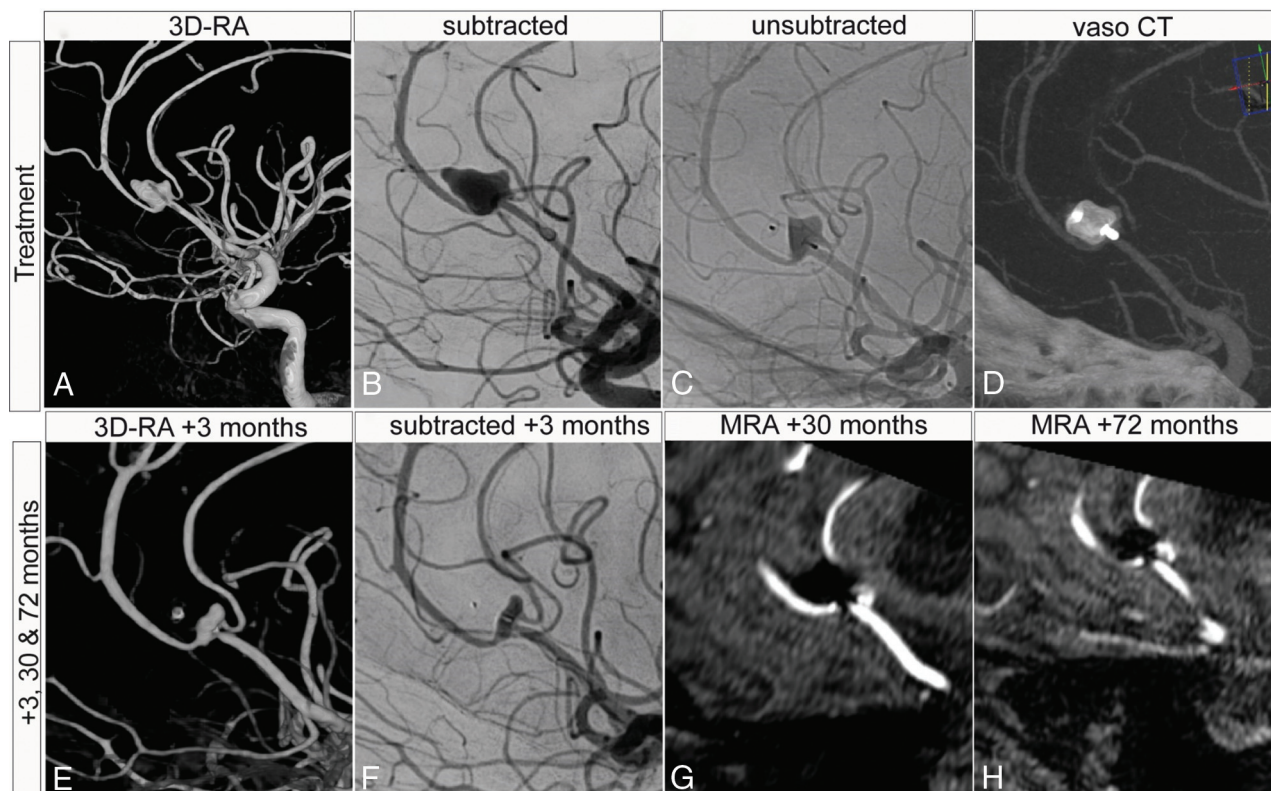


FIG 1. A 58-year-old woman presenting with an SAH, Hunt and Hess grade 3, from a pericallosal aneurysm. The patient had 2 additional aneurysms (not shown). A–D, Treatment of the aneurysm with a WEB-SL 6 × 4. A small neck remnant was accepted to keep the pericallosal artery patent. E–H, Long-term follow-up with DSA and MRA up to 72 months demonstrates stable aneurysm occlusion and patency of the pericallosal artery. VasoCT (Phillips Healthcare).

after discharge. Finally, 2 patients (2.6%) were lost to follow-up and could not be contacted. The last imaging and clinical visits were at 5 and 6 months after treatment, respectively. The average follow-up in this subgroup was 17 months (mode, 18; range, 5–34 months).

Morbidity and Mortality

Of 78 patients, 71 (91%) had mRS 0–2, and 7 (9%) had mRS 3–5 at discharge from our hospital.¹¹

At last follow-up, 73 (94%) patients had mRS 0–2, and 5 (6%) had mRS 3–5. Two patients went from mRS 3–5 to mRS 0–2. There were no rebleeds from the ruptured aneurysm or thromboembolic events, either clinically or on MR imaging during long-term follow-up.

Aneurysm Occlusion and Retreatment

Of 78 ruptured aneurysms, 56 (72%) remained completely occluded (illustrative case, Fig 1), and 17 (22%) had a small neck remnant that was accepted at 3-month angiographic follow-up and remained stable with time on MRA. Five patients (6%) had a reopening of the aneurysm requiring additional treatment. One patient with a reopening of the aneurysm had additional treatment with pCONus (phenox) and coiling. This did not stop aneurysm growth, and the patient was retreated for a third time with an LVIS stent (MicroVention) and coiling. This third procedure was complicated by a small thalamus infarct. One patient underwent aneurysm clipping, and 3 patients received

an additional WEB (illustrative case, Fig 2), of which 1 had to be treated with coiling for the third time (Table).

DISCUSSION

This long-term follow-up study demonstrates that primary treatment of ruptured intracranial aneurysms with the WEB device is both safe and effective, with no rebleeds during follow-up. Of 100 patients initially treated with the WEB device in our series, 18 died in the first 3 months of follow-up.¹¹ After almost 5 years of follow-up, no additional deaths or deterioration in mRS scores was identified. Two patients increased their clinical condition to mRS 0–2 with time. This change brought the overall mortality rate after long-term follow-up in our series of 100 patients with ruptured aneurysm to 18% (95% CI). This is more than the percentage quoted in the 5-year long-term follow-up International Subarachnoid Aneurysm Trial (ISAT),¹² in which 1073 patients underwent coil embolization for ruptured aneurysms, and the overall mortality rate after 5 years was 11% (95% CI). However, 23% of our study patients were admitted in severe clinical conditions (Hunt and Hess grades 4–5) compared with 12% in ISAT. In addition, our study included wide-neck aneurysms that were not suitable for coiling and were excluded from ISAT.

Prevention of rebleeding is the primary goal in the treatment of ruptured aneurysms. In our long-term follow-up, there were no rebleeds and 6% required retreatment after 3 months. This outcome is slightly better compared with ISAT, in which the rate

of rebleeding was 1.9% in the first 30 days¹³ and late retreatment (>3 months after the first treatment) was 9%.

As mentioned in our previously published series, 66% had a wide neck, and treatment complications occurred in 9%. These percentages are relatively low compared with those in stent-assisted coiling, which is another commonly used technique for the treatment of wide-neck bifurcation aneurysms. Two recently published meta-analyses examining the efficacy of stent-assisted

coiling in the treatment of ruptured wide-neck bifurcation aneurysms demonstrated total complication rates of around 20%.^{6,14} In the meta-analysis by Bsai et al,⁶ the thromboembolic complication rate was 9.1%, which is comparable with that in our cohort. However, the rates of postinterventional rebleeding and hemorrhagic complications were 2.5% and 8.7%, respectively, in stent-assisted coiling compared with 0% in our series. This result is likely due to the dual-antiplatelet therapy necessary for stent-

assisted coiling. When using the WEB device, we have not used anti-aggregation therapy in any of our patients with ruptured aneurysms. This result demonstrates the safety profile of the WEB device when treating ruptured wide-neck bifurcation aneurysms without antiplatelet therapy.

In our series, 72% of aneurysms were angiographically completely occluded, and 22% had a small neck remnant. This neck remnant is a frequently observed phenomenon after WEB implantation in the aneurysm sack also called “WEB Shape Modification.”¹⁵ WEB Shape Modification describes a decrease in the device height due to the deepening of the central recess of the device, probably due to compression. These neck remnants generally do not require retreatment because they are expected to be stable.^{15,16} Nevertheless, there are currently no supporting long-term data, and the clinical significance of neck remnants remains a matter of debate. Critics argue that neck remnants due to WEB compression should not be neglected because neck remnants carry an inherent risk of rerupture, as demonstrated for coiling.¹⁷ However, our series demonstrates that WEB Shape Modification after treatment of ruptured aneurysms does not lead to aneurysm growth or rerupture during long-term follow-up.

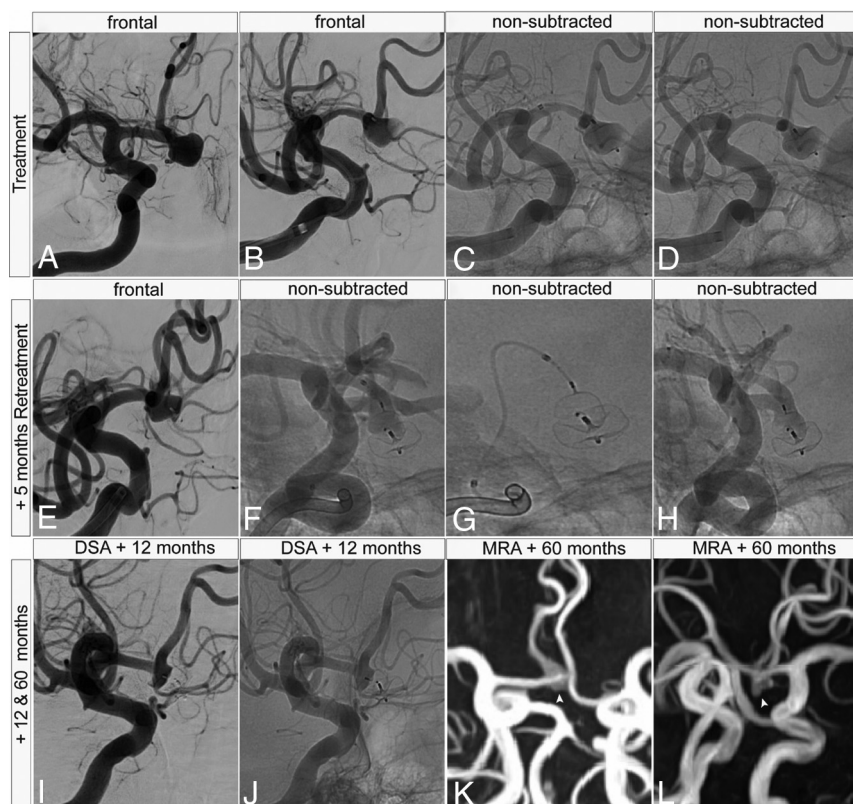


FIG 2. A 52-year-old woman presenting with SAH, Hunt and Hess grade 3, from an 8-mm anterior communicating artery aneurysm. A–D, WEB-SL 9 × 3 placement in the aneurysm. After detachment, there was unintended impaction of the proximal portion of the WEB (D), indicating potential undersizing and resulting in a small neck remnant that was accepted in the acute phase of the SAH. E–H, Follow-up angiography demonstrates WEB impaction and a growing 5-mm neck remnant, which was retreated with a WEB-SL 6 × 3 mm. I–L, A 12-month DSA and 48-month MRA demonstrate a small neck remnant that remains stable on long-term follow-up (white arrowheads).

Five patients with a ruptured aneurysm requiring retreatment

Decade of Life	Aneurysm Location	Hunt and Hess	WEB	Timing and Method of Retreatment	Timing and Method of Second Retreatment	Last Follow-up
7th	Basilar tip	4–5	SLS 8	+10 Months WEB-SL 8 × 3	—	+54 Months MRA
3rd	PcomA ^a	1–2	SLS 4	+4 Months WEB-SL 3, 5 × 2 ^b	+10 Months Coiling	+52 Months MRA
6th	AcomA	3	SL 9 × 4	+5 Months WEB-SL 6 × 3 ^b	—	+60 months MRA
6th	Superior cerebellar	3	SLS 11	+20 Months pCONus and coiling	+33 months LVIS stent and coiling	+58 Months MRA
6th	PcomA ^a	1–2	SL 7 × 4	+19 Months Clipping	—	+19 Months Preclip DSA

Note:—AcomA indicates anterior communicating artery; —, N/A; PcomA, posterior communicating artery; Preclip, right before aneurysm clipping.

^a Fetal origin.

^b WEB 17 system.

Limitations

Limitations of this study include the single-center and uncontrolled design; therefore, there is a possibility of selection bias. Another limitation is the self-reporting of angiographic results and the limited number of patients.

CONCLUSIONS

WEB treatment of ruptured intracranial aneurysms is feasible, effective, and safe and has good long-term follow-up results. The stable aneurysm occlusion rate is high, and the retreatment rate with the WEB is low during the long term. The WEB provides a valuable alternative to coils and seems to be a better alternative to stent-assisted coiling.

Disclosure forms provided by the authors are available with the full text and PDF of this article at www.ajnr.org.

REFERENCES

1. Cognard C, Pierot L, Anxionnat R, et al; Clarity Study Group. **Results of embolization used as the first treatment choice in a consecutive nonselected population of ruptured aneurysms: clinical results of the Clarity GDC study.** *Neurosurgery* 2011;69:837–41; discussion 842 [CrossRef Medline](#)
2. Pierot L, Cognard C, Anxionnat R, et al; CLARITY Investigators. **Endovascular treatment of ruptured intracranial aneurysms: factors affecting midterm quality anatomic results—analysis in a prospective, multicenter series of patients (CLARITY).** *AJNR Am J Neuroradiol* 2012;33:1475–80 [CrossRef Medline](#)
3. Chalouhi N, Jabbour P, Singhal S, et al. **Stent-assisted coiling of intracranial aneurysms: predictors of complications, recanalization, and outcome in 508 cases.** *Stroke* 2013;44:1348–53 [CrossRef Medline](#)
4. Piotin M, Blanc R, Spelle L, et al. **Stent-assisted coiling of intracranial aneurysms: clinical and angiographic results in 216 consecutive aneurysms.** *Stroke* 2010;41:110–15 [CrossRef Medline](#)
5. Chung J, Lim YC, Suh SH, et al. **Stent-assisted coil embolization of ruptured wide-necked aneurysms in the acute period: Incidence of and risk factors for periprocedural complications: clinical article.** *J Neurosurg* 2014;121:4–11 [CrossRef Medline](#)
6. Bsat S, Bsat A, Tamim H, et al. **Safety of stent-assisted coiling for the treatment of wide-necked ruptured aneurysm: a systematic literature review and meta-analysis of prevalence.** *Interv Neuroradiol* 2020;26:547–56 [CrossRef Medline](#)
7. Bechan RS, Sprengers ME, Majoie CB, et al. **Stent-assisted coil embolization of intracranial aneurysms: complications in acutely ruptured versus unruptured aneurysms.** *AJNR Am J Neuroradiol* 2016;37:502–07 [CrossRef Medline](#)
8. Asnafi S, Rouchaud A, Pierot L, et al. **Efficacy and safety of the Woven EndoBridge (WEB) device for the treatment of intracranial aneurysms: a systematic review and meta-analysis.** *AJNR Am J Neuroradiol* 2016;37:2287–92 [CrossRef Medline](#)
9. Essibayi MA, Lanzino G, Brinjikji W. **Safety and efficacy of the Woven EndoBridge device for treatment of ruptured intracranial aneurysms: a systematic review and meta-analysis.** *AJNR Am J Neuroradiol* 2021;42:1627–32 [CrossRef Medline](#)
10. Monteiro A, Lazar AL, Waqas M, et al. **Treatment of ruptured intracranial aneurysms with the Woven EndoBridge device: a systematic review.** *J Neurointerv Surg* 2021;14:366–70 [CrossRef Medline](#)
11. Van Rooij SB, Van Rooij WJ, Peluso JP, et al. **WEB treatment of ruptured intracranial aneurysms: a single-center cohort of 100 patients.** *AJNR Am J Neuroradiol* 2017;38:2282–87 [CrossRef Medline](#)
12. Molyneux AJ, Kerr RS, Birks J, et al. **Risk of recurrent subarachnoid haemorrhage, death, or dependence and standardised mortality ratios after clipping or coiling of an intracranial aneurysm in the International Subarachnoid Aneurysm Trial (ISAT): long-term follow-up.** *Lancet Neurol* 2009;8:427–33 [CrossRef Medline](#)
13. Molyneux A, Kerr R, Stratton I, et al; International Subarachnoid Aneurysm Trial (ISAT) Collaborative Group. **International Subarachnoid Aneurysm Trial (ISAT) of neurosurgical clipping versus endovascular coiling in 2143 patients with ruptured intracranial aneurysms: a randomized trial.** *J Stroke Cerebrovasc Dis* 2002;11:304–14 [CrossRef Medline](#)
14. Zhang X, Zuo Q, Tang H, et al. **Stent assisted coiling versus non-stent assisted coiling for the management of ruptured intracranial aneurysms: a meta-analysis and systematic review.** *J Neurointerv Surg* 2019;11:489–96 [CrossRef Medline](#)
15. Roskopf J, Braun M, Dreyhaupt J, et al. **Shape modification is common in Woven EndoBridge-treated intracranial aneurysms: a longitudinal quantitative analysis study.** *AJNR Am J Neuroradiol* 2020;41:1652–56 [CrossRef Medline](#)
16. Janot K, Herbreteau D, Amelot A, et al. **Quantitative evaluation of WEB shape modification: a five-year follow-up study.** *J Neuroradiol* 2019;47:193–96 [CrossRef Medline](#)
17. Johnston SC, Dowd CF, Higashida RT, et al; CARAT Investigators. **Predictors of rehemorrhage after treatment of ruptured intracranial aneurysms: the Cerebral Aneurysm Rerupture After Treatment (CARAT) study.** *Stroke* 2008;39:120–25 [CrossRef Medline](#)