This information is current as of October 12, 2024.

Association of Left Vertebral Artery Hypoplasia with Posterior Circulation Stroke and the Functional Outcome of Patients with Atrial Fibrillation–Related Cardioembolic Stroke

J.-H. Bae, J.-C. Ryu, S.H. Ha, B.J. Kim, D.-W. Kang, S.U. Kwon, J.-S. Kim and J.Y. Chang

AJNR Am J Neuroradiol 2023, 44 (1) 65-69
doi: https://doi.org/10.3174/ajnr.A7738
http://www.ajnr.org/content/44/1/65

Association of Left Vertebral Artery Hypoplasia with Posterior Circulation Stroke and the Functional Outcome of Patients with Atrial Fibrillation–Related Cardioembolic Stroke

J.-H. Bae, J.-C. Ryu, S.H. Ha, B.J. Kim, D.-W. Kang, S.U. Kwon, J.-S. Kim, and J.Y. Chang

ABSTRACT

BACKGROUND AND PURPOSE: A cardiogenic embolus could reach the posterior circulation through the right vertebral artery because of a relatively larger diameter in cases of left vertebral artery hypoplasia. Hence, we investigated whether left vertebral artery hypoplasia is associated with cardiac embolisms with atrial fibrillation in the posterior circulation and its functional outcomes.

MATERIALS AND METHODS: In this monocentric retrospective study, patients with acute cardioembolic stroke with atrial fibrillation were enrolled and underwent CT or neck MRA, which visualized the aortic arch and subclavian arteries. The laterality and size of vertebral artery hypoplasia were recorded. Posterior circulation stroke, basilar artery occlusion, and the functional outcomes after 3 months were investigated.

RESULTS: This study included 407 patients; the patients with left vertebral artery hypoplasia experienced a higher rate of posterior circulation stroke (19 versus 73; 42.2% versus 20.2%; $P = .001$) and basilar artery occlusion (5 versus 10; 11.1% versus 2.8%; $P = .005$) than the patients without left vertebral artery hypoplasia. Multivariate analysis revealed that left vertebral artery hypoplasia showed an association with lower odds of achieving a good functional outcome 3 months after the stroke (OR = 0.4; 95% CI, 0.2–0.9; $P = .027$).

CONCLUSIONS: Patients with cardioembolic stroke and left vertebral artery hypoplasia had posterior circulation stroke, basilar artery occlusion, and poor functional outcomes after 3 months.

ABBREVIATIONS: PICAI = posterior inferior cerebellar artery infarction; VA = vertebral artery; VAH = vertebral artery hypoplasia

Anatomic variations in the posterior circulation are common, particularly in the vertebral arteries (VAs).[1] Congenital vertebral artery hypoplasia (VAH) is present in 1.9%–26.5% of the population. It is associated with posterior circulation ischemic stroke due to stenosis in the hypoplastic segment and the resultant ipsilateral cerebellar hypoperfusion.[2-5] It is uncertain whether VAH influences cardioembolic stroke in the posterior circulation.

Although conflicting results exist, previous studies have reported that cardiogenic cerebral embolisms have a right-sided propensity in acute stroke.[6,7] This is because the innominate artery, which supplies the right VA and right common carotid artery, has the largest caliber and travels superior and parallel to the direction of the ascending aorta.[6,7]

Patients with left VAH have a right VA with a relatively larger diameter. On the basis of this evidence, we assumed that cardiogenic emboli might reach the right VA more often than the left VA. We hypothesized that the patients with cardiogenic stroke with left VAH may be have posterior circulation stroke, basilar artery occlusion, and less functional independence after 3 months.

MATERIALS AND METHODS

We assessed all patients with stroke admitted to the Stroke Center at single tertiary referral hospital, Seoul, South Korea, between January 1, 2017, and August 31, 2020. The patients were screened for an acute symptomatic stroke due to cardiac embolism with atrial fibrillation. Patients with >50% stenosis in a symptomatic vessel were excluded. We selected patients with ischemic stroke who underwent MR imaging and MRA during admission, when the ischemic lesions were assessed by DWI. Demographics, risk

Received April 20, 2022; accepted after revision November 11.

From the Department of Neurology (J.-H.B., J.-C.R., S.H.H., B.J.K., D.-W.K., S.U.K., J.Y.C.), Asan Medical Center, University of Ulsan, College of Medicine, Seoul, Korea; and Department of Neurology (J.-S.K.), Gangneung Asan Hospital, Gangneung, Korea.

This research was supported by a grant from the Korea Health Technology R&D Project through the Korea Health Industry Development Institute, funded by the Ministry of Health and Welfare, Republic of Korea (grant No. HI18C2383).

Please address correspondence Jun Young Chang, MD, PhD, Department of Neurology, Asan Medical Center, University of Ulsan, College of Medicine, 88 Olympic-ro 43-gil, Songpa-gu, Seoul, Korea, 138-736; e-mail: noyerpapa@gmail.com

Indicates open access to non-subscribers at www.ajnr.org

Indicates article with online supplemental data.

http://dx.doi.org/10.3174/ajnr.A7738

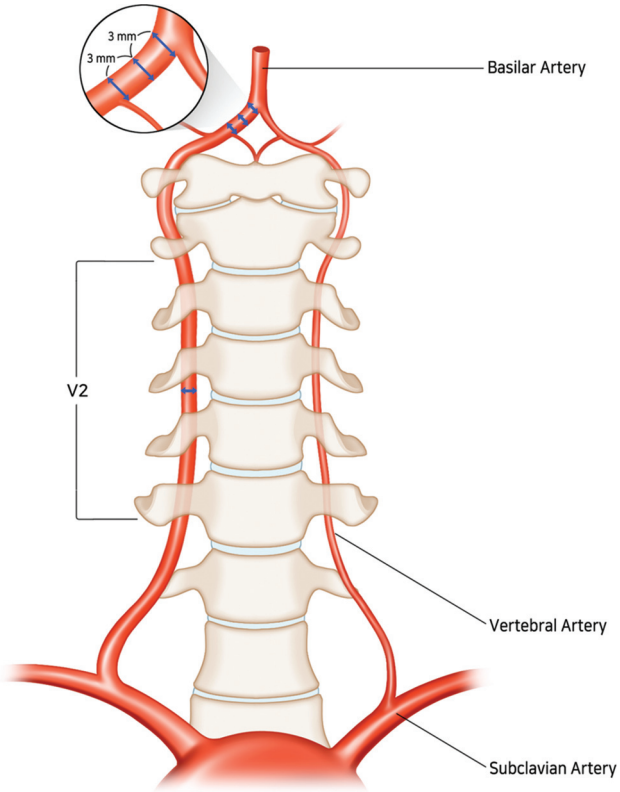

FIG 1. Measuring the diameter of the VA. The diameter of each VA was calculated as the average of the measurements made at 3 consecutive points, spaced 3 mm apart, starting from the vertebrobasilar junction.

factors, NIHSS score on admission, and 3-month mRS were collected. The ethics committee of Asan Medical Center approved this study, and the need for informed consent was waived because of the retrospective nature of the study.

Brain Imaging Analysis

All MRAs included intracranial and neck vessels. We assessed VAH in all patients. The diameter of each VA was calculated as the average of the measurements made at 3 consecutive points, spaced 3 mm apart, starting from the vertebrobasilar junction (both VAs and the basilar artery). We examined the midportion of the intervertebral segment (V2), which is less susceptible to atherosclerotic changes or artifacts in patients with distal VA stenosis (Fig 1).[3,8] VAH was defined as a VA with a diameter of ≤2 mm, and the contralateral larger VA was defined as the dominant VA. Symmetric VA was defined as both vertebral arteries having a diameter of > 2mm.[2-4] Patients were classified as having either a posterior circulation stroke or an anterior circulation stroke. To demonstrate a cardiac embolus passing through the dominant VA, we measured the frequency and laterality of VAH in the patients with cardioembolic stroke and contralateral posterior inferior cerebellar artery infarction (PICAI).

Outcome Variables

In accordance with the widely used mRS grades, we defined mRS 0–2 as good functional outcome (functional independence) and mRS 3–6 as poor functional outcome. MRS 0–3 was used to define independent walking.[9] We evaluated the relationship between mRS 0–2 at 3 months after the stroke and left VAH as the primary outcome, and mRS 0–3 (independent walking) at 3 months after the stroke and left VAH as the secondary outcome.[9]

Statistical Analysis

Differences between the groups (ie, patients with left VAH versus others, right PICAI versus left PICAI, and good functional outcome versus poor functional outcome) were analyzed using the Student t test, χ^2 test, and Mann-Whitney U test, whichever was appropriate, for continuous and categoric variables. We performed a multiple regression analysis to determine which variables were independent predictors of achieving mRS 0–2 and mRS 0–3 at 3 months after the stroke. Categoric variables were entered into a univariate logistic regression model, including demographic variables (ie, age, sex, and risk factors for stroke), anatomic variables (laterality of VAH), basilar artery occlusion, and the location of the stroke lesion (posterior or anterior circulation). Results are given as ORs as estimates of the relative risk with 95% CI. Analysis was performed using SPSS, Version 26.0 (IBM), and $P < .05$ was considered statistically significant.

RESULTS

Between January 2017 and August 2020, adult patients with acute ischemic stroke were enrolled. Brain MR imaging and 3-month mRS data were available for 2366 patients. Of these, 621 patients had cardioembolic strokes (Online Supplemental Data). Among them, 407 patients were diagnosed with atrial fibrillation before or during hospitalization. The mean age was 73.3 (SD, 10.5) years, and 196 (48.2%) were women. In total, 144 (35.4%) patients with VAH and 263 (64.6%) patients without VAH were enrolled. Left VAH was detected in 45 (11.1%) patients (Table 1).

Left VAH, Posterior Circulation Cardioembolic Stroke, and Basilar Artery Occlusion

Compared with patients without left VAH in the univariate analysis, patients with left VAH were more often women (62.2% versus 46.4%, $P = .045$), had posterior circulation strokes more frequently (42.2% versus 20.2%, $P = .001$), exhibited more basilar artery occlusion (11.1% versus 2.8%, $P = .005$), and were less likely to achieve mRS 0–3 (independent walking) at 3 months after the stroke (55.6% versus 70.7%, $P = .038$) (Table 1 and Fig 2). Patients with right VAH showed no difference in posterior circulation stroke, basilar artery occlusion, and reaching mRS 0–2 (good functional outcome) and mRS 0–3 (independent walking) 3 months after the stroke compared with the patients without right VAH in the univariate analysis (Online Supplemental Data). To demonstrate that cardiac emboli passed through the dominant right VA (contralateral to the left VAH), we performed a subgroup analysis of 49 patients with posterior circulation infarction involving the unilateral PICA territory. Compared with the left PICAI group, the right PICAI group was associated with left VAH and a larger right VA (6 versus 1; 28.6% versus 3.6%; $P = .013$). The right PICAI group showed no association with right VAH compared with the left PICAI group (Table 2).

Table 1: Characteristics of patients with cardioembolic stroke with atrial fibrillation with left VA hypoplasia and others[a]

	Total (n = 407)	Left VAH (n = 45)	Others (n = 362)	P Value
Age (yr)	73.3 (SD, 10.5)	74.9 (SD, 10.1)	73.1 (SD, 10.5)	.276
Female sex	196 (48.2)	25 (62.2)	160 (46.4)	.045
Hypertension	279 (68.6)	35 (77.8)	244 (67.4)	.157
Diabetes mellitus	113 (27.8)	15 (33.3)	98 (27.1)	.376
Hyperlipidemia	129 (31.7)	11 (24.4)	118 (32.6)	.268
Ischemic heart disease	80 (19.7)	6 (13.3)	74 (20.4)	.258
History of stroke	107 (26.3)	9 (20.0)	98 (27.1)	.309
Current smoker	110 (27.0)	11 (24.4)	99 (27.3)	.679
Initial NIHSS	6.0 (2.0–13.0)	6.0 (2.5–11.5)	6.0 (2.0–13.0)	.886
Lesion location				
Anterior circulation	293 (72.0)	23 (51.1)	270 (74.6)	.001
Posterior circulation	92 (22.6)	19 (42.2)	73 (20.2)	.001
Both	22 (5.4)	3 (6.7)	19 (5.2)	.692
BAO	15 (3.7)	5 (11.1)	10 (2.8)	.005
3-Month mRS	2.0 (0.3–4.0)	3.0 (1.0–5.0)	2.0 (0.0–4.0)	.067
3-Month mRS 0–2	234 (57.5)	20 (44.4)	214 (59.1)	.060
3-Months mRS 0–3	281 (69.0)	25 (55.6)	256 (70.7)	.038

Note:—BAO indicates basilar artery occlusion.

[a] Results are presented as number and percentage, mean, or median (25th–75th percentile).

FIG 2. Basilar artery occlusion in a patient with left VAH (*A*) showing right posterior inferior cerebellar artery infarction due to cardioembolism (*B*), whose 3-month mRS was 4. Follow-up MRA shows a recanalized basilar artery (*C*).

Left VAH and Poor Functional Outcome

Comparisons between the mRS 0–2 (good functional outcome) group and the mRS 3–6 (poor functional outcome) group are summarized in Table 3. Compared with the poor functional outcome group, patients with good functional outcome were younger (mean age, 70.8 [SD, 9.8] versus 76.7 [SD, 10.5] years, $P < .001$); were less often women (41.5% versus 57.2%, $P = .002$); had less hypertension (64.5% versus 74.0%, $P = .042$) and diabetes mellitus (22.8% versus 35.8%, $P = .002$) and a previous stroke history (19.2% versus 35.8%, $P < .001$); were current smokers (32.1% versus 20.2%, $P = .008$); had a lower initial NIHSS score (3.0 [interquartile range, 1.0–7.0] versus 13.0 [interquartile range, 6.0–17.0], $P < .001$); and had less basilar artery occlusion (1.7% versus 6.4%, $P = .014$). The 3-month mRS 0–2 (good functional outcome) showed a trend toward an inverse association with left VAH compared with patients with 3-month mRS 3–6 (poor functional outcome) in univariate analysis (8.5% versus 14.5%, $P = .060$). Compared with patients with 3-month mRS 4–6, patients with 3-month mRS 0–3 (independent walking) showed a reverse association with left VAH in the univariate analysis (8.9% versus 15.9%, $P = .038$) (Online Supplemental Data).

In the multivariable analysis (including the presence of left VAH, sex, age, hypertension, diabetes mellitus, current smoking, previous stroke history, and initial NIHSS), the presence of left VAH showed an association with lower odds of achieving mRS 0–2 (good functional outcome) 3 months after the stroke (OR = 0.4; 95% CI, 0.2–0.9; $P = .027$). The presence of left VAH showed less attainment of mRS 0–3 (independent walking) at 3 months after the stroke (OR = 0.4; 95% CI, 0.2–0.8; $P = .016$).

DISCUSSION

We found that left VAH is associated with posterior circulation stroke, basilar artery occlusion, and poor functional outcome after 3 months in patients with cardioembolic stroke with atrial fibrillation. Previous studies reported that posterior circulation strokes represented about 20% of all ischemic strokes.[10] In our study, 42.2% of the patients with left VAH had a posterior circulation stroke.

Recent studies have emphasized the clinical importance of VAH on stroke and reported that patients with VAH are at a high risk of posterior circulation stroke.[1,2] Previous studies reported that VAH is associated with ipsilateral atherosclerotic stenosis in the VA and posterior circulation stroke.[3,5] Thierfelder et al[4] reported that VAH could lead to relative hypoperfusion in the ipsilateral PICA. Bilateral VAH may have a unique pattern in the infarction territory that involves multiple vascular territories, and it is mostly bilateral.[11]

Perren et al[1] reported that more than one-half of posterior circulation strokes in patients with VAH were presumably embolic. Although there are conflicting results, previous studies have disclosed that cardiogenic embolisms have a right-sided propensity in acute stroke. Our study explained the mechanism for posterior circulation stroke in patients with left VAH, in whom the cardiac emboli pass through the dominant right VA.

Several mechanisms may explain our results. The right VA (a branch of the right subclavian artery) has the largest caliber and travels superior and parallel to the direction of the ascending

Table 2: Characteristics of patients with cardioembolic stroke with PICA territory infarction contralateral to VAH[a]

VAH	Right PICA Territory Infarction (n = 21)	Left PICA Territory Infarction (n = 28)	P Value
Left	6 (28.6)	1 (3.6)	.013
Right	5 (23.8)	9 (32.1)	.523
Symmetric	10 (47.6)	18 (64.3)	.243

[a] Results are presented as number and percentage.

Table 3: Characteristics of patients with atrial fibrillation–related cardioembolic stroke with good functional outcome (mRS 0–2) versus poor functional outcome (mRS 3–6)[a]

	3-Month mRS 0–2 (n = 234)	3-Month mRS 3–6 (n = 173)	P Value
Age (yr)	70.8 (SD, 9.8)	76.7 (SD, 10.5)	<.001
Female sex	92 (41.5)	93 (57.2)	.002
Hypertension	151 (64.5)	128 (74.0)	.042
Diabetes mellitus	51 (22.8)	62 (35.8)	.002
Hyperlipidemia	79 (33.8)	50 (28.9)	.298
Ischemic heart disease	49 (20.9)	31 (17.9)	.448
History of stroke	45 (19.2)	62 (35.8)	<.001
Current smoker	75 (32.1)	35 (20.2)	.008
Initial NIHSS	3.0 (1.0–7.0)	13.0 (6.0–17.0)	<.001
VAH			
Right	59 (25.2)	40 (23.1)	.627
Left	20 (8.5)	25 (14.5)	.060
Symmetric	155 (66.2)	108 (62.4)	.427
Lesion location			
Anterior circulation	164 (70.1)	129 (74.6)	.260
Posterior circulation	59 (25.2)	33 (19.1)	.108
Both	11 (4.7)	11 (6.4)	.465
BAO	4 (1.7)	11 (6.4)	.014

Note:—BAO indicates basilar artery occlusion.
[a] Results presented as number and percentage, mean, or median (25th–75th percentile).

aorta; therefore, we could assume that a cardiogenic embolus will reach the right VA orifice more often than the contralateral left VA orifice.[6,7] Because the diameter of the right VA is relatively larger in patients with left VAH, the cardiogenic emboli can reach the posterior circulation through the right VA more often than in the patients with symmetric VA or right VAH. This theory may be supported by our analysis that the right PICAI is associated with left VAH (6 versus 1; 28.6% versus 3.6%; $P = .013$) compared with the left PICAI group. We presumed that patients with left VAH have a dominant right VA with a larger diameter, occasionally wider than 4 mm and similar to that of the basilar artery.[1,2] A cardiogenic embolus large enough to occlude the basilar artery might have a higher chance of passing through the dominant right VA.

Posterior circulation stroke is a marker of poor functional outcome in patients with acute ischemic stroke.[12] Basilar artery occlusion is known to be associated with poor functional outcome and high mortality.[13,14] A higher percentage of posterior circulation strokes and basilar artery occlusion might explain the poor 3-month functional outcomes in the patients with left VAH.

There are limitations to our study. The possibility that a posterior circulation infarction might be due to atherosclerosis or dissection of the VA was not excluded.[10] However, patients with vertebrobasilar artery stenosis of >50% were excluded in our cohort; therefore, the possibility of stroke due to atherosclerosis or dissection is not high. Second, there are patients with variations in the anatomy of the vertebrobasilar artery, such as the absence of the PICA, PICA duplication, and fenestration, which were not evaluated in this study.[15] Third, our study cohort does not represent the general population because we conducted a retrospective analysis at a single-center with a relatively small number of patients. Therefore, prospective studies with larger numbers of patients are necessary to determine the causative relationship between left VAH and posterior circulation stroke. Fourth, with such a small sample size, it is difficult to consider clinically significant the result that patients with right PICAI showed a higher rate of left VAH than patients with left PICAI. Although statistically significant, type II error may have affected the results.

CONCLUSIONS

Left VAH is associated with posterior circulation stroke, basilar artery occlusion, and poor 3-month functional outcomes in patients with cardioembolic stroke

Disclosure forms provided by the authors are available with the full text and PDF of this article at www.ajnr.org.

REFERENCES

1. Perren F, Poglia D, Landis T, et al. **Vertebral artery hypoplasia: a predisposing factor for posterior circulation stroke?** *Neurology* 2007;68:65–67 CrossRef Medline
2. Kulyk C, Voltan C, Simonetto M, et al. **Vertebral artery hypoplasia: an innocent lamb or a disguise?** *J Neurol* 2018;265:2346–52 CrossRef Medline
3. Park JH, Kim JM, Roh JK. **Hypoplastic vertebral artery: frequency and associations with ischaemic stroke territory.** *J Neurol Neurosurg Psychiatry* 2007;78:954–58 CrossRef Medline
4. Thierfelder KM, Baumann AB, Sommer WH, et al. **Vertebral artery hypoplasia: frequency and effect on cerebellar blood flow characteristics.** *Stroke* 2014;45:1363–68 CrossRef Medline
5. Dinc Y, Ozpar R, Emir B, et al. **Vertebral artery hypoplasia as an independent risk factor of posterior circulation atherosclerosis and ischemic stroke.** *Medicine (Baltimore)* 2021;100:e27280 CrossRef Medline
6. Kim HJ, Song JM, Kwon SU, et al. **Right-left propensity and lesion patterns between cardiogenic and aortogenic cerebral embolisms.** *Stroke* 2011;42:2323–25 CrossRef Medline
7. Park KY, Kim YB, Chung PW, et al. **Right-side propensity of cardiogenic emboli in acute ischemic stroke with atrial fibrillation.** *Scand Cardiovasc J* 2014;48:335–38 CrossRef Medline
8. Hong JM, Chung CS, Bang OY, et al. **Vertebral artery dominance contributes to basilar artery curvature and peri-vertebrobasilar junctional infarcts.** *J Neurol Neurosurg Psychiatry* 2009;80:1087–89 CrossRef Medline
9. Banks JL, Marotta CA. **Outcomes validity and reliability of the modified Rankin scale: implications for stroke clinical trials.** *Stroke* 2007;38:1091–96 CrossRef Medline
10. Markus HS, van der Worp HB, Rothwell PM. **Posterior circulation ischaemic stroke and transient ischaemic attack: diagnosis,**

investigation, and secondary prevention. *Lancet Neurol* 2013;12:989–98 CrossRef Medline

11. Hsu CF, Chen KW, Su CH, et al. **Bilateral vertebral artery hypoplasia and fetal-type variants of the posterior cerebral artery in acute ischemic stroke.** *Front Neurol* 2021;12:582149 CrossRef Medline
12. Sommer P, Posekany A, Serles W, et al; Austrian Stroke Unit Registry Collaborators. **Is functional outcome different in posterior and anterior circulation stroke?** *Stroke* 2018;49:2728–32 CrossRef Medline
13. Mattle HP, Arnold M, Lindsberg PJ, et al. **Basilar artery occlusion.** *Lancet Neurol* 2011;10:1002–14 CrossRef Medline
14. Langezaal LC, van der Hoeven E, Mont'Alverne FJ; et al; BASICS Study Group. **Endovascular therapy for stroke due to basilar-artery occlusion.** *N Engl J Med* 2021;384:1910–20 CrossRef Medline
15. Pekcevik Y, Pekcevik R. **Variations of the cerebellar arteries at CT angiography.** *Surg Radiol Anat* 2014;36:455–61 CrossRef Medline