This information is current as of October 12, 2024.

Enhancing Annular Fissures and High-Intensity Zones: Pain, Internal Derangement, and Anesthetic Response at Provocation Lumbar Discography

W.S. Bartynski, V. Agarwal, H. Trang, A.I. Bandos, W.E. Rothfus, J. Tsay, W.T. Delfyett and B. Nastasi

AJNR Am J Neuroradiol 2023, 44 (1) 95-104
doi: https://doi.org/10.3174/ajnr.A7749
http://www.ajnr.org/content/44/1/95

Enhancing Annular Fissures and High-Intensity Zones: Pain, Internal Derangement, and Anesthetic Response at Provocation Lumbar Discography

W.S. Bartynski, V. Agarwal, H. Trang, A.I. Bandos, W.E. Rothfus, J. Tsay, W.T. Delfyett, and B. Nastasi

ABSTRACT

BACKGROUND AND PURPOSE: A high-intensity zone identified on preprocedural MR imaging is known to correlate with pain at provocation lumbar discography. The correlation between enhancing annular fissures and pain at provocation lumbar discography has not been comprehensively evaluated. The purpose of this study was to assess the pain response and imaging features at enhancing annular fissure nonoperated disc levels identified on preprocedural MR imaging with comparison with the high-intensity zone and nonenhancing disc levels in patients referred for provocation lumbar discography.

MATERIALS AND METHODS: One-hundred nonoperated discs in 44 patients were retrospectively evaluated for an enhancing annular fissure on sagittal postcontrast T1-weighted pre-discogram MR imaging. Enhancing annular fissure discs were graded on the sagittal T2-weighted sequence (Grade 4: like CSF to Grade 1: negative/barely visible) for high-intensity-zone conspicuity. High-intensity-zone detection was performed independently. In the primary assessment, enhancing annular fissure and high-intensity zones were associated with pain response at provocation lumbar discography. Additional analysis included intradiscal anesthetic response and postdiscogram CT appearance.

RESULTS: Thirty-nine discs demonstrated an enhancing annular fissure, with 23/39 demonstrating a high-intensity zone. The presence of a high-intensity zone predicted severe pain (concordant + nonconcordant; $P = .005$, sensitivity of 40%, specificity of 94%) and concordant pain ($P = .007$, sensitivity of 39%, specificity of 86%) at provocation lumbar discography. Enhancing annular fissures without a detected high-intensity zone were more frequently observed among severely painful (50%) and concordant (36%) discs than among discs negative for pain (9%; $P = .01$). This finding resulted in a substantially greater overall sensitivity of enhancing annular fissures for severe ($P < .001$, 64%) and concordant pain ($P = .008$, 61%), significantly improving the overall predictive ability of a high-intensity zone alone. A high-intensity zone went undetected in 9/11 Grade 1 disc levels with concordant pain present in 7/9.

CONCLUSIONS: Consideration of enhancing annular fissures on preprocedural MR imaging substantially improves the prediction of severe/concordant pain in provocation lumbar discography.

ABBREVIATIONS: DEG = Dallas discogram disc degeneration feature; EAF = enhancing annular fissure; FSU = functional spinal unit; HIZ = high-intensity zone; LBP = low back pain; PLD = provocation lumbar discography; RDef = Dallas discogram radial annular defect/tear feature; VAS = visual analog scale

A high-intensity zone (HIZ) is a well-recognized observation associated with disc degeneration, typically identified along the posterior annular margin on lumbar T2-weighted MR imaging.[1-3] HIZs can be seen in both symptomatic and asymptomatic patients.[1-7] The HIZ most frequently associated with a peripheral concentric annular fissure and/or a full-thickness radial annular tear has been shown to correlate with axial low back pain (LBP) reproduced at provocation lumbar discography (PLD) with reported sensitivities ranging from 25% to 97% and specificities ranging from 83% to 95% for concordant pain.[4-6,8-10] The primary purpose of discography is to identify concordant discs or disc levels in patients with chronic LBP for appropriate treatment targeting (ie, fusion or direct disc-focused treatments).

Enhancement into an annular fissure/tear has been seen in symptomatic lumbar discs to include globoid or linear enhancement into the posterior annular margin and/or adjacent annular substance and appears to correlate with local in-growth of granulation tissue.[11-13] Enhancement has also been recognized in peripheral annular fissures of asymptomatic patients.[2] Most studies

Received July 5, 2022; accepted after revision November 22.

From the Department of Radiology (W.S.B., V.A., H.T., W.E.R., J.T., W.T.D., B.N.), Division of Neuroradiology, University of Pittsburgh, Presbyterian University Hospital, Pittsburgh, Pennsylvania; Department of Radiology (H.T.), St. Clair Hospital, Pittsburgh, Pennsylvania; Department of Biostatistics (A.I.B.), Graduate School of Public Health, University of Pittsburgh, Pittsburgh, Pennsylvania; Department of Radiology (J.T.), Cleveland Clinic, Cleveland, Ohio; and Brighton Radiology Associates, PC (B.N.), Monaca, Pennsylvania.

Please address correspondence to Walter S. Bartynski, MD, 3920 Gift Blvd, Johns Island, SC 2945; e-mail: walter.bartynski@gmail.com

http://dx.doi.org/10.3174/ajnr.A7749

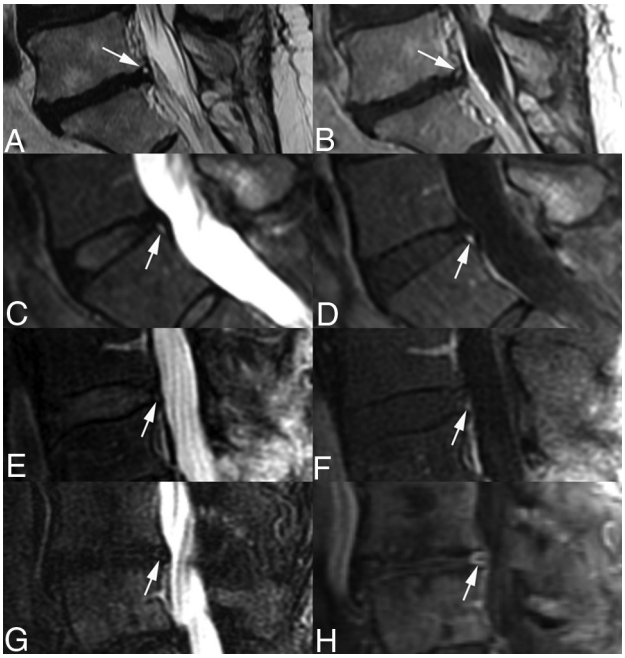

FIG 1. T2-weighted sequence grading of annular fissures detected on postcontrast T1-weighted imaging. *A*, Grade 4 annular fissure: annular fissure signal has high signal intensity (*arrow*) with signal that is greater than that of adjacent spinal fluid, consistent with an HIZ. *B*, Enhancement in the Grade 4 annular fissure (*arrow*). *C*, Grade 3 annular fissure: annular fissure signal has high signal intensity (*arrow*) with signal that is less than that of the adjacent spinal fluid, consistent with an HIZ. *D*, Enhancement in the Grade 3 annular fissure (*arrow*). *E*, Grade 2 annular fissure: annular fissure signal is focally abnormal but with mixed intermediate-to-low signal intensity (*arrow*) appearing close to the signal of the degenerative disc without a definite HIZ. *F*, Enhancement in the Grade 2 annular fissure (*arrow*). *G*, Grade 1 annular fissure: annular fissure signal is abnormal and has low signal intensity (*arrow*), appearing similar to the signal of other portions of the severely degenerative disc. *H*, Enhancement in the Grade 1 annular fissure (*arrow*).

correlating discography with peripheral annular fissures/tears have focused on the standard T2-weighted imaging findings recognized along the posterior or posterior-lateral margin of the disc.[1-6,8-10] To our knowledge, no study has comprehensively assessed the imaging/discography correlation of enhancing annular fissures (EAFs).

The purpose of this study was the following:

1) To evaluate the incidence of EAFs and HIZs found on preprocedural enhanced MR imaging at nonoperated lumbar levels in a cohort of patients referred for PLD.
2) To compare the pain response between EAF disc levels, HIZ discs levels, and nonenhancing disc levels encountered at PLD.
3) To explore features of internal derangement and the intradiscal anesthetic response in EAF discs.

The primary outcome of the study is the pain response (concordant, nonconcordant, negative), which is compared for discs presenting with EAF, HIZ, or nonenhancement. Our hypothesis was that identifying discs positive for EAF will substantially improve the prediction of painful disc levels at PLD, in particular concordant painful disc levels.

MATERIALS AND METHODS

During a 5-year period, 494 consecutive patients underwent PLD at our institution, of whom 64 were identified as having preprocedural MR imaging studies with both unenhanced and enhanced sequences, typically because of chronic LBP along with a prior spine operation. Patients were referred for provocation discography by spine-focused orthopedic surgeons or neurosurgeons and were being evaluated to identify clinically positive concordant disc levels that would be appropriate for surgery, typically fusion.

Seventeen of 64 patients had prior interbody fusion; 3 patients lacked sagittal postcontrast T1-weighted MR imaging and these 20 patients were, therefore, excluded. University of Pittsburgh institutional review board approval was obtained for this retrospective study.

Imaging Evaluations

Identifying EAFs. The MR imaging studies in the remaining 44 patients with chronic LBP (obtained 0–43 months before PLD; average, 5.1 months) were retrospectively assessed for the following: 1) the presence or absence of an EAF on the sagittal enhanced T1-weighted sequence, and/or 2) an HIZ on the sagittal T2-weighted imaging sequence, by 3 experienced neuroradiologists by consensus (consensus group 1). Readers had no knowledge of which discs were studied at discography or whether a disc was symptomatic at discography.

MR imaging accompanied 10 patients from an outside institution (Signa 1.5T, GE Healthcare; Magnetom 1.5T, Siemens; Infinion 1.5T, Phillips Healthcare) with 34 scans obtained at our institution (Signa, 1.5T; GE Healthcare). All studies had sagittal T1 spin-echo or turbo spin-echo (typically TR = 400–600, TE = minimum, matrix = 256 × 192 to 512 × 512, section = 3–5 mm); sagittal T2, typically FSE/TSE T2 with fat saturation (TR = 2300–4350 ms, TE = 80–100 ms, matrix = 256 × 192 to 512 × 512, section = 3–5 mm); and sagittal T1 postcontrast spin-echo or turbo spin-echo (typically TR = 400–600, TE = minimum, matrix = 256 × 192 to 512 × 512, section = 3–5 mm) with axial T2 and T1 available. Sagittal STIR was available in 5 patients.

An annular fissure was considered present when enhancement was seen to penetrate the posterior or posterior-lateral annular margin in a rounded-globoid and/or linear pattern, in particular the posterior annular margin, on the sagittal postcontrast T1-weighted sequence (EAF) or when a typical HIZ was seen along the annular margin on the sagittal T2-weighted sequence. In 26 patients, an EAF and/or a typical peripheral annular fissure was identified at ≥1 lumbar disc. In 18 patients, no EAF was identified on postcontrast T1-weighted imaging and no HIZ was identified on the sagittal T2 sequence.

Preprocedural MR imaging was compared with the reports and imaging features from the corresponding PLD. Previously operated disc levels (having prior discectomy) were excluded from the analysis.

Grading HIZs. Many EAFs identifiable on the sagittal postcontrast T1-weighted sequence were considered difficult to identify as HIZs on the sagittal T2-weighted sequence. Therefore, EAF discs were further consensus-graded by consensus group 1 (Grade 4 to

Grade 1) for visualization and signal characteristics on the sagittal T2 (Fig 1).

Blinded HIZ Detection. Two different neuroradiologists (consensus group 2) assessed the sagittal T2-weighted sequences independently for the presence/absence of an HIZ in all 26 patients with EAFs at all lumbar disc levels. Interpreters had no knowledge of the intent of the analysis, including disc levels of interest. Differences were resolved by consensus.

Disc Degeneration Grading on MR Imaging. Studied discs were graded for the degree of disc degeneration on preprocedural MR imaging (Pfirrmann Grades: I–V) by 2 experienced neuroradiologists by consensus.[14]

Lumbar Discography Technique

After informed consent, 2 experienced neuroradiologists performed discography in a standard fashion.[15,16] The patient's LBP history was clarified and recorded using the 0–10 Visual Analog Scale (VAS; 0 = no pain, 10 = worst pain imaginable) including the most severe LBP experienced and immediate preprocedural LBP levels. Limited IV conscious sedation (fentanyl, 0.05 mg; midazolam [Versed], 1 mg) was given just before the procedure, but the level of consciousness was never affected.

The lumbar region was cleansed and draped, and with C-arm fluoroscopy (OEC 9800; GE Healthcare), a local anesthetic was applied and the center of the disc was accessed using a double-needle technique (20-ga guiding needle, 25-ga 15-cm to 20-cm curved Chiba needle). L3–4 to L5–S1 were typically studied in all patients, and all needles were placed concordantly. The anticipated normal/control disc level, L3–4, was usually studied first with more superior levels added if L3–4 was painful on injection.

Discs were studied with a moderate-to-rapid hand injection (iohexol, Omnipaque: GE Healthcare, 240 mg of iodine/mL, 0.25–0.30 mL/s) consistent with the prior hand-injection rate estimates of Derby et al.[17] Contrast was delivered using a 3-mL syringe and a 0.6-mL Pediatric Connector (Non-DEHP IV Catheter Extension Set; Baxter Interlink System) under direct fluoroscopic visualization, with anterior-posterior and lateral spot films obtained during and/or following the injections.

In normal nonpainful discs, minimal injection resistance is usually encountered until a firm end point is reached when no additional contrast can be injected (typical injection volume, 1.5 mL; range, 1–2.5 mL).[18] In degenerative or painful disc levels, the injection volume was dependent on the following: 1) reaching a firm injection end point, 2) encountering a positive clearly established LBP response, or 3) exaggerated disc capacity, typically encountered in severely degenerative or leaking discs (typical injection volume, approximately 2 mL; range, 0.3–4.5 mL).[18]

Patients were kept unaware of whether a level was being provoked or which level was being studied. The response to the injection was observed by the operator, and with a positive pain response, the features of the pain were clarified, the VAS level of pain was established, and these items were recorded in a manner similar to the technique of Walsh et al.[15,16]

Consistent with prior lumbar discography studies,[4-6] the provoked pain response to disc injection is usually identified by the patient as being either concordant (ie, typical of their familiar pain) or nonconcordant (ie, not their familiar pain). Concordant and many nonconcordant painful discs are commonly described by the patient as "severe," reporting a VAS pain level ≥7. If a severely painful disc was encountered (usually VAS ≥ 7), preservative-free lidocaine (2% strength, 1–1.5 mL of lidocaine HCl, Xylocaine-MPF; Fresenius Kabi USA) was injected into the disc in an attempt to reduce the patient's provoked pain and allow response clarity in subsequently studied lumbar levels. At some severely painful disc levels, a typical contrast injection end point was reached, leading to volume limitation preventing the anesthetic injection.

During disc testing, the patient's immediate response to the injection, the perception of provoked pain (concordant or nonconcordant), and injection end point response (if present) were the primary focus of the discographer. Syringe-disc pressures were not recorded during injection.

Postdiscogram CT. Immediately following discography, all patients underwent postdiscogram CT (Lightspeed, GE Healthcare) performed using bone/soft-tissue algorithms with either direct axial 3-mm-section acquisition or a spiral technique and 3-mm axial and sagittal reformatting with isotropic voxels. Disc internal derangement was graded by the Dallas discogram criteria, including degeneration (DEG; defined as annular fragmentation: Dallas Grade 1, <10%; Dallas Grade 2, < 50%; Dallas Grade 3, ≥50%) and radial annular defects/tears (RDef; defined as Dallas Grade 1, a radial tear projecting up to the inner annulus; Dallas Grade 2, radial tear to the outer annulus; and Dallas Grade 3, a radial tear beyond the outer annulus).[4,5,19,20] Full-thickness Dallas Grade 3 RDef included annular gaps,[19] a radial tear projecting into the peripheral annular tear (after Aprill and Bogduk,[4] often labeled Grade 4), and a full-thickness radial tear with discographic contrast leakage (after Schellhas et al,[5] often labeled Grade 5).

Statistical Analysis

The association of EAF and HIZ with categories of pain response was assessed using the generalized linear model for categoric data (PROC GENMOD, SAS Version 9.4; SAS Institute) accounting for a possible correlation in observations from the same patients and adjusting for possible confounders. The corresponding empirical standard errors were used to estimate the 95% confidence interval for proportions of discs (including sensitivity, specificity, and predictive values for severe provoked pain overall (concordant + nonconcordant and/or concordant pain). The overall predictive ability was illustrated using the receiver operating characteristic curves. Differences in the area under the receiver operating characteristic curves were assessed using the 95% confidence intervals based on using the nonparametric cluster bootstrap (with 10,000 resamples), with patients as sampling units.

In the secondary analyses, the overall association of the 3-category anesthetic response with the presence of leakage and EAF was tested in the context similar to that of the generalized linear model, accounting for possible correlation in observations from the same patients. The significant ($P = .05$ level) overall test was followed by comparisons among individual categories. In addition,

Table 1: Annular fissures identified and pain response at provocation discography

Peripheral Annular Morphology by MR Imaging	Discography-Provoked Pain Response			
	Severe Pain			
	Concordant Pain (% of Total)	Nonconcordant Pain (% of Total)	Negative for Pain	Total
EAF	22/39 (56.4%)	10/39 (25.6%)	7/39 (18%)	39 (100%)
Focal high signal on T2WI only	0	0	1	1
No MR imaging evidence of annular fissure/tear	14/60 (23.3%)	4/60 (6.7%)	42/60 (70.0%)	60 (100%)
Total	36/100 (36%)	14/100 (14%)	50/100 (50%)	100 (100%)

Table 2: Thirty-nine discs positive for EAF—T2WI grade, HIZ detection, and unrecognized fissure/tear pain response

Annular Fissure/Tear CG-1 T2WI Grade	EAFs Identified on T1 Enhanced Sequence by CG-1	HIZs Identified on T2-Weighted Sequence by CG-2 (% EAFs)	Injection Pain Response of 16 Unrecognized Annular Fissures (HIZs) by CG-2 on T2WI		
			C	NC	N
4	8	7/8 (87.5%)		1	
3	12	10/12 (83.3%)	1		1
2	8	4/8 (50.0%)	1	2	1
1	11	2/11 (18.2%)	7	1	1
Total	39	23/39 (59.0%)	9	4	3

Note:—C indicates concordant levels; NC, nonconcordant levels; N, negative pain response; CG-1, consensus group 1; CG-2, consensus group 2.

evaluations of the radial defects and degenerative derangement were grouped into the abnormal morphology category.

RESULTS

Nineteen of 44 patients were men, and 25 were women, with an average age of 43.1 years (range, 19–64 years). Discography was performed in 100 nonoperated discs (L5–S1, 15; L4–5, 28; L3–4, 44; L2–3, 12; L1–2, 1). In 26/44 patients (59.1%), 39 EAFs were identified (single level, 14 patients; 2 levels, 11 patients; 3 levels, 1 patient). EAFs were located at the posterior annular margin in 37 discs and the posterior-lateral margin in 2 discs (L2–3, 3; L3–4, 12; L4–5, 19; L5–S1, 5) in the nonoperated discs that were studied by discography. In 2 of these patients, 3 additional nonoperated discs demonstrated an EAF but were not studied at discography; therefore, these discs were excluded.

In 1 patient positive for EAF, 1 disc demonstrated a small high signal zone on T2-weighted imaging only. Provocation response and postdiscogram CT findings were both negative, suggesting an intra-annular cyst. No HIZ or EAF was identified in 60 discs in 18 patients on the T2- or postcontrast T1-weighted sequence.

PLD Pain Observations

Provocation pain results are presented in Table 1. Severe pain overall was reported in 50/100 disc levels (50%) in 33 patients. Concordant pain was reported in 36/100 (36%) disc levels overall and in 36/50 (72%) disc levels with severe pain.

Peripheral Annular Fissure (EAF and HIZ) Identification. Comparisons of T2-weighted signal intensity grade in EAF discs (judged by consensus group 1) with traditional HIZ detection on the T2-weighted sequence (consensus group 2) are summarized in Table 2. An HIZ was identified by consensus group 2 in 23/39 discs (59%) with an EAF. The 23 discs positive for HIZ were identified only in discs with an EAF.

Grade 4 and 3 annular fissures/tears were commonly identified as an HIZ by consensus group 2 (87.5% and 83.3%, respectively). Lower signal intensity annular fissures/tears were less confidently recognized, with Grade 2 detected in 4/8 (50%) discs and Grade 1 detected in only 2/11 (18%) discs as an HIZ. In the Grade 1 group, 7/9 discs not perceived with an HIZ were at painful concordant levels (Table 2).

Presence of an EAF: Disc/Patient Characteristics and Pain Response. Table 3 summarizes the rates of EAF identification for disc levels with different pain responses by levels of potentially relevant covariates. The frequency of EAF varied across the disc levels ($P = .002$), being most frequent at the L4–5 level (68%, 19/28). EAF was also more frequent in patients 41 years of age and older (50%, 29/58) than in patients of 40 years and younger (24%, 10/42; $P = .009$), but it was only fractionally more frequent in women (44%, 26/59) than in men (32%, 13/41); $P = .25$).

As shown in Table 3, overall, EAF was substantially more prevalent at disc levels with concordant pain (61%, 22/36) and nonconcordant pain (71%, 10/14) than at disc levels negative for pain (14%, 7/50; $P < .001$). This strong association of EAF with concordant and nonconcordant pain prevailed across the disc levels, sex, and patient age groups (adjusted $P < .001$). Nineteen of 26 patients (73%) with an EAF reported concordant pain at ≥1 disc level (single level, 17; two levels, 1; three levels, 1), with 5 of 26 patients (19%) reporting nonconcordant pain at ≥1 disc level, and 2 of 26 patients (8%) reporting no pain with the discogram injections.

For predicting disc levels with provoked severe pain overall, the presence of an EAF has a sensitivity of 64% (95% CI, 49%–77%), a specificity of 86% (95% CI, 72%–94%), and a positive predictive value of 82% (95% CI, 66%–92%) for a population with 50% of disc levels showing severe pain.

Similarly, for predicting disc levels with provoked concordant pain, the presence of an EAF has a sensitivity of 61% (95% CI,

Table 3: Proportions of discs with EAF for different pain responses by disc levels, sex, and patient age

Disc/Patient Characteristics	Discography Pain Response			
	Severe Pain			
	Concordant Pain (EAF %)	Nonconcordant Pain (EAF %)	Negative for Pain (EAF %)	Overall (EAF %)
Overall	22/36 (61%)	10/14 (71%)	7/50 (14%)	39/100 (39%)
Disc level				
L1–2 to L2–3[a]	2/3 (67%)	0/1 (0%)	1/9 (11%)	3/13 (23%)
L3–4	4/11 (36%)	4/5 (80%)	4/28 (14%)	12/44 (27%)
L4–5	14/15 (93%)	3/3 (100%)	2/10 (20%)	19/28 (68%)
L5–S1	2/7 (29%)	3/5 (60%)	0/3 (0%)	5/15 (33%)
Sex				
Female	16/23 (70%)	5/7 (71%)	5/29 (17%)	26/59 (44%)
Male	6/13 (46%)	5/7 (71%)	2/21 (10%)	13/41 (32%)
Age				
Younger than 41 yr	16/24 (67%)	7/9 (78%)	6/25 (24%)	29/58 (50%)
41 yr or older	6/12 (50%)	3/5 (60%)	1/25 (4%)	10/42 (24%)

[a] There was a single disc at L1–2 that did not have an EAF or pain on provocation.

Table 4: Response to provocative discography by imaging findings of HIZ and EAF (no discs identified with HIZ but without EAF)

Imaging Features	Discography Pain Response			
	Severe Pain (n = 50)			
	Concordant (n = 36)	Nonconcordant (n = 14)	Negative for Pain (n = 50)	Total (n = 100)
EAF+ HIZ+	14/36 (39%)	6/14 (43%)	3/50 (6%)	23/100
EAF+ HIZ−	8/36 (22%)	4/14 (29%)	4/50 (8%)	16/100
EAF− HIZ−	14/36 (39%)	4/14 (29%)	43/50 (86%)	61/100
Total	36 (100%)	14 (100%)	50 (100%)	100/100

42%–77%), a specificity of 73% (95% CI, 61%–83%), and a positive predictive value of 56% (95% CI, 41%–71%), for a population with 36% of disc levels showing concordant pain.

HIZ and EAF Pain Responses. With HIZs identified only in discs positive for EAF, combined consideration of EAF and HIZ distinguishes 3 categories of discs (Table 4): "EAF-positive, HIZ-positive," "EAF-positive, HIZ-negative," and "EAF-negative, HIZ-negative," which are significantly associated with the pain response levels ($P < .001$).

HIZ Identification (EAF-Positive, HIZ-Positive Discs). An HIZ was recognized substantially more frequently at disc levels with concordant pain (39%, 14/36) and nonconcordant pain (43%, 6/14) than at disc levels negative for pain (6%, 3/50; $P = .003$; Table 4, row 1). The presence of an HIZ alone can be used for predicting concordant pain ($P = .007$), with a sensitivity of 39%, 14/36 (95% CI, 24%–56%); a specificity of 86%, 55/64 (95% CI, 75%–93%); and a positive predictive value of 61%, 14/23, (95% CI, 40%–78%) for a population with 36% of disc levels showing concordant pain (Fig 2*A*).

Similarly, for predicting severe pain overall, the presence of HIZ alone offers a sensitivity of 40%, 20/50 (95% CI, 27%–54%); a specificity of 94%, 47/50, (95% CI, 78%–99%); and a positive predictive value of 87%, 20/23 (95% CI, 59%–97%) for a population with 50% of disc levels showing severe pain (Fig 2*B*).

EAF without HIZ (EAF-Positive, HIZ-Negative Discs). Among 77 remaining discs without an HIZ (Table 4, rows 2 and 3), an EAF was also more frequent at disc levels with concordant pain (36%, 8/22) and nonconcordant pain (50%, 4/8) than at disc levels negative for pain (9%, 4/47), with a statistically significant overall difference ($P = .010$). As a result, the identification of an EAF for disc levels without HIZ leads to an increase in the sensitivity of predicting both concordant painful disc levels (from 39% to 61%, $P = .008$) and severely painful disc levels overall (from 40% to 64%, $P < .001$), with relatively smaller sacrifice in specificity (resulting in an increase in the area under the receiver operating characteristic curves of 0.06; 95% CI, 0.0–0.12 and from 0.62 to 0.68 for predicting concordant pain, Fig 2*A*) and in an increase in the area under the receiver operating characteristic curves of 0.09; 95% CI, 0.04–0.14, and from 0.67 to 0.76 for severe pain (Fig 2*B*).

EAF Disc Internal Derangement Features

The presence of an annular fissure compared with the postdiscogram features of internal disc derangement is summarized in Table 5. The internal derangement categories are approximately equally represented among 100 discs studied, with 32%, 33%, and 35% of radial defects and degenerative and normal morphology, respectively. Abnormal morphology is strongly associated with severely painful discs (with a sensitivity of 88%, 44/50, and a specificity of 58%, 29/50, $P < .0001$) and is present in 92% (33/36; 95% CI, 77%–97%) of discs with significant concordant pain. (Abnormal morphology did not demonstrate a meaningful ability to differentiate concordant from nonconcordant painful discs.) Among 65 discs with abnormal morphology, EAF maintained a strong association with pain response, being present in 68% (40/44) of discs with significant pain, including in 67% (18/33) with concordant pain, while only in 33% (7/21) of discs negative for pain ($P = .013$).

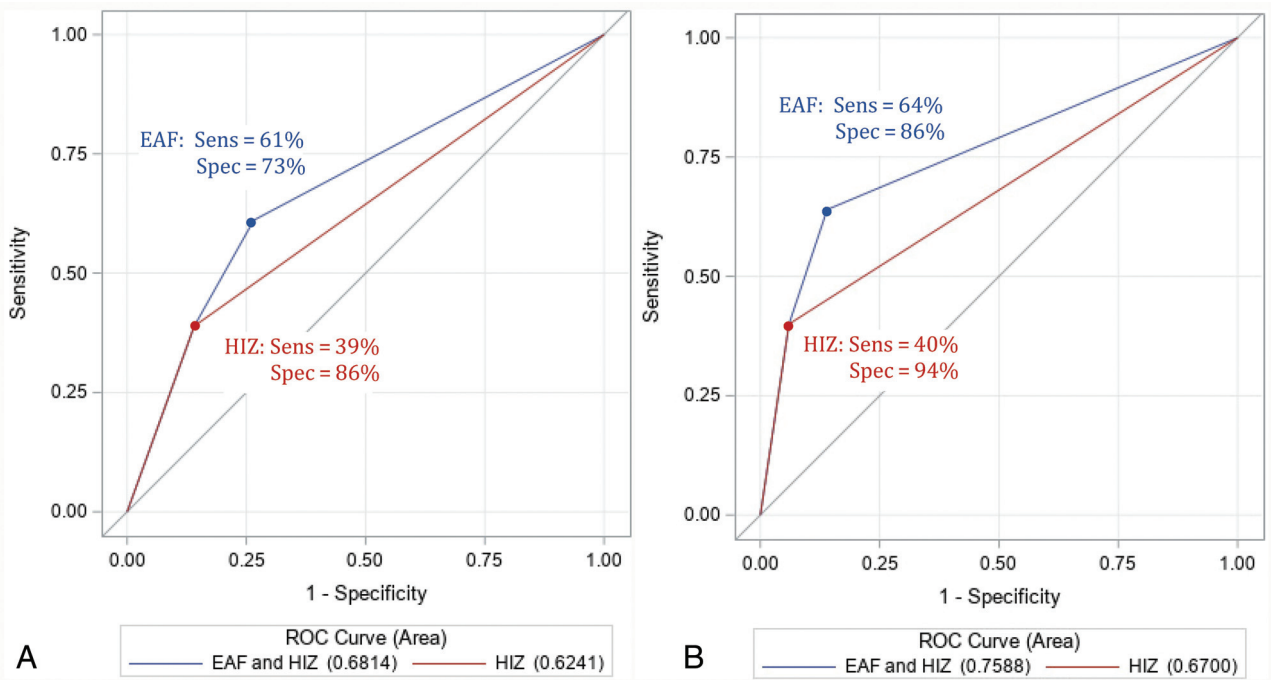

FIG 2. Receiver operating curves (ROCs) for predicting concordant pain (*A*) and significant pain (*B*) based on HIZ and EAF features. Sens indicates sensitivity; Spec, specificity.

Table 5: Features of internal derangement—summary of all discs

	Discogram Pain Response												
	Severe Pain												
	Concordant			Discordant			Negative for Pain			Total			
Disc State	RDef	DEG	NI	RDef	DEG	NI	RDef	DEG	NI	RDef	DEG	NI	All
EAF	9	13	0	6	4[a]	0	3	4	0	18	21	0	39
Focal high-signal T2 only	0	0	0	0	0	0	0	0	1	0	0	1	1
No annular fissure	6	5	3	2	1	1	7[b]	7[c,d]	28	15	13	32	60
Total	15	18	3	8	5	1	10	11	29	33	34	33	100

Note:—NI indicates normal-appearing disc on postdiscogram CT.
[a] One Dallas Grade 1 disc.
[b] One Dallas Grade 1 radial fissure.
[c] One Dallas Grade 2 disc.
[d] One Dallas Grade 1 disc; 1 Dallas Grade 2 disc.

Further breakdown of the annular fissure grade and internal derangement is summarized in Table 6. All except 1 disc with an annular fissure demonstrated Grade 3 Dallas internal derangement. Eighteen of 39 EAF discs demonstrated a RDef (Dallas grade 3), with 21 discs demonstrating DEG (Dallas grade three, 20; Dallas grade one, 1). Dallas grade 3 DEG was more commonly identified in discs judged graded 2 or 1 for HIZ on the T2-weighted sequence (Fig 3), with a full-thickness RDef more commonly identified in discs judged Grade 4 or 3 (Fig 4). In the setting of severe Dallas Grade 3 DEG, the enhancing granulation tissue is likely distributed in a complex way along the posterior annulus (Fig 3). In the setting of a Dallas Grade 3 RDef, the enhancing granulation tissue appears to be in the area of the radial annular fissure/tear (Fig 4). In the 9 Grade 1 discs not recognized as an HIZ, 7 were in discs with Dallas Grade 3 DEG on postdiscogram CT (Fig 3) with 2 in discs demonstrating a RDef.

Discs without an EAF demonstrated similar features of internal derangement with concordant and nonconcordant levels demonstrating severe internal derangement and negative for pain levels generally appearing normal.

Disc Degeneration on MR Imaging

Overall, Pfirrmann Grades (I–V) of the 100 studied discs were: Grade I, 12; Grade II, 30; Grade III, 33; Grade IV, 30; Grade V, 2, with Grades of the 39 discs positive for EAF of: Grade I, 2; Grade II, 3; Grade III, 18; Grade IV, 14; Grade V, 2 and Grades of the 23 discs positive for HIZ of: Grade I, 2; Grade II, 1; Grade III, 10; Grade IV, 9; Grade V, 1, respectively.

Pfirrmann Grades of the 61 discs negative for EAF were: Grade I, 10; Grade II, 27; Grade III, 15; Grade IV, 9; Grade V, 0.

Intradiscal Anesthetic Response

The intradiscal anesthetic response of 40 severely painful disc levels is summarized in Table 7. Consistent with previous reports, the anesthetic response is significantly associated with the presence of contrast leakage ($P = .011$).[16,19,21] The presence of leakage was

Table 6: EAF T2WI grade by CG-1 versus postdiscogram CT features of internal derangement—39 discs

	Discogram Pain Response and Internal Derangement Features							
	Severe Pain							
	Concordant Pain		Nonconcordant Pain		Negative for Pain		Total	
Annular Fissure T2WI CG-1 Grade	RDef	DEG	RDef	DEG	RDef	DEG	RDef	DEG
4	2	3	3	0	0	0	5	3
3	4	2	2	1	1	2	7	5
2	1	2	1	2	1	1	3	5
1	2	6	0	1[a]	1	1	3	8
Total	9	13	6	4[a]	3	4	18	21

Note:—DEG indicates degenerative change Dallas Grade 3 except for 1 disc; RDef, all radial defects (Dallas Grade 3); CG-1, consensus group 1.
[a] Dallas Grade 1.

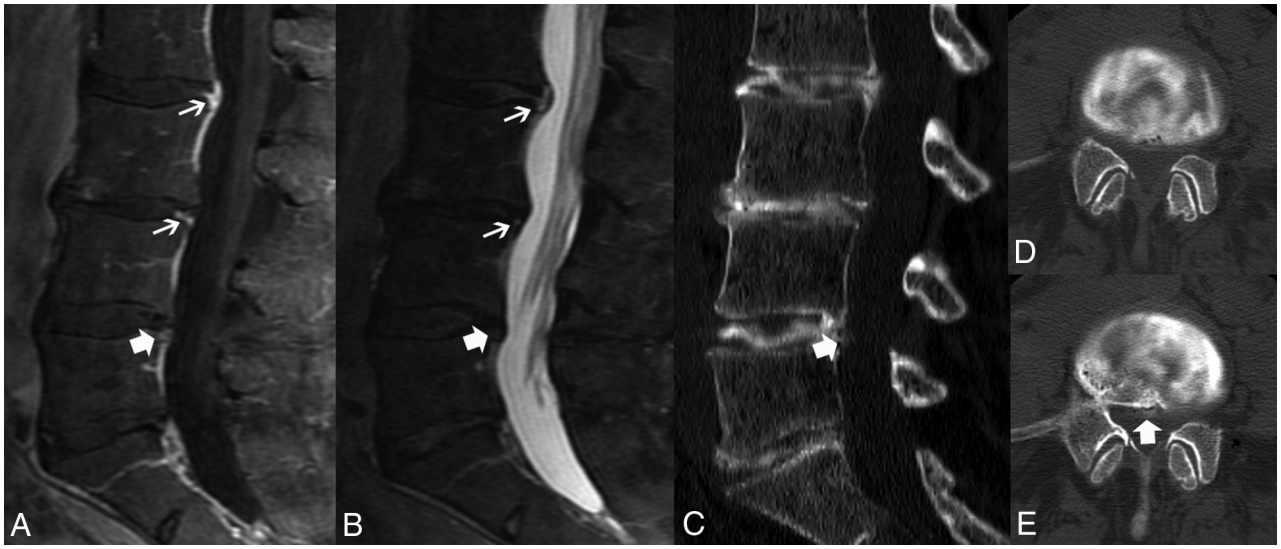

FIG 3. A 49-year-old woman with long-standing LBP and some bilateral leg radiation (most severe VAS = 10/10; immediate preprocedural VAS = 5/10) with prior discectomy at L5–S1. Concordant pain was provoked at L2–3, L3–4, and L4–5, with all 3 levels demonstrating partial provoked pain improvement with intradiscal lidocaine, and all 3 levels appearing contained on postdiscogram CT. *A*, Sagittal postcontrast T1-weighted image demonstrates posterior EAFs at L2–3, L3–4 (*thin arrows*), and L4–5 (*thick arrow*). *B*, Sagittal T2-weighted image. The L2–3 HIZ, considered Grade 4, and L3–4 HIZ, considered Grade 2 by consensus group 1, were identified as HIZs by consensus group 2 (*thin arrows*). The EAF at L4–5 considered a Grade 1 HIZ by consensus group 1 was not identified as an HIZ by consensus group 2 (*thick arrow*). *C*, Sagittal reconstructed CT image demonstrates the posterior annular margin at L4–5, consistent with the EAF (*thick arrow*). *D* and *E*, Axial postdiscogram CT images through the L4–5 disc demonstrates severe annular degeneration (Dallas Grade 3) with the posterior annular margin noted, consistent with the EAF (*thick arrow*).

most frequent among the discs with the total anesthetic improvement (82%, 14/17) and significantly less frequent for partial anesthetic improvement (29%, 2/7; $P = .038$) and no anesthetic improvement (31%, 5/16; $P = 011$). The anesthetic response was not associated with age, sex, disc level, or the presence of EAF. EAF was similarly represented in the discs with total, partial, and no improvement (65%, 11/17; 57%, 4/7; 81%, 13/16, respectively, $P = .36$).

Of the 40 severely painful discs that received intradiscal anesthetic, 31 were at concordant disc levels (total improvement, 12 [EAF: 8/12]; partial improvement, 7; no improvement, 12) and 9 were at nonconcordant disc levels (total improvement, 4 [EAF 3/4]; partial improvement, 0; no improvement, 5).

DISCUSSION

An HIZ (annular fissure/tear) identified on preprocedural MR imaging is known to correlate with provoked pain at discography.[4-6] Our data demonstrate that enhancement in an annular fissure/tear (an EAF) is more common than an HIZ alone and appears to represent a powerful indicator of a painful disc level in patients referred for PLD. The presence of an EAF appears predictive of severe pain overall as well as concordant pain provoked at discography, regardless of the disc level, sex, or age of the patients. In our series, all discs with an HIZ also demonstrated enhancement and were recognized as an EAF.

The primary purpose of discography is to identify concordant discs or disc levels in patients with chronic LBP for appropriate treatment planning. Concordant provoked pain was identified in 36 of 50 (72%) disc levels that responded with severe pain on injection. Overall, an EAF was significantly more sensitive than an HIZ in predicting disc levels with concordant pain (EAF 61% versus HIZ 39%, $P = .008$) and nonconcordant pain (EAF 64% versus HIZ 40%, $P < .001$), with relatively smaller sacrifice in specificity (due to enhancement present in negative disc levels). Concordant provoked pain was observed in 19 of 26 (73.1%) patients with an EAF (single disc level, 17; two disc levels, 1; three disc levels, 1).

Annular fissure enhancement likely correlates with in-growth of vascularized granulation tissue at an abnormal annular margin, probably reflecting complete or ongoing annular repair. In-growth of pain fibers has been documented into the deep annular and nuclear regions of severely degenerative discs and into the area of a RDef in animal models.[22,23] Granulation tissue represented by the enhancing annular fissure/tear region can, therefore, carry nociceptive fibers, and this enhancing region could represent an important focal source of pain in many of these discs. Ross et al[13] noted improved visualization of peripheral annular fissures after contrast enhancement. Stadnik et al,[2] evaluating asymptomatic patients (absent or without LBP for >6 months), observed that most annular fissures were more confidently identified after contrast enhancement with only 1 recognized on T2-weighted imaging only, paralleling our results.

Joint consideration of the presence of HIZ and/or EAF substantially improves the stand-alone ability of HIZ to predict concordant or severely painful disc levels (Fig 2). In particular, among discs without an HIZ, an EAF was substantially more frequently present at disc levels with concordant and nonconcordant pain than at disc levels negative for pain (36% and 50% versus 9%), leading to the significant increases in sensitivity, with only a small sacrifice in specificity. Thus, in addition to a significant stand-alone performance, EAF substantially improved the ability of HIZ to predict the pain response at PLD.

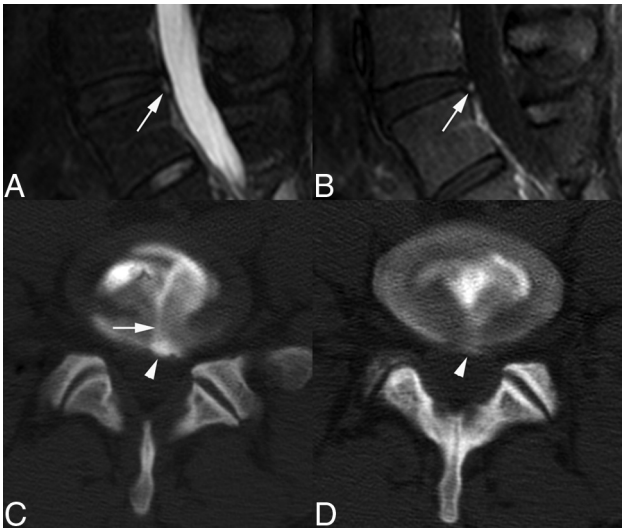

FIG 4. A 29-year-old woman with complex LBP and leg pain (most severe VAS = 10/10; preprocedural VAS = 5/10) with prior L5–S1 discectomy. Concordant pain was provoked at L4–5 (VAS = 10/10). *A*, Sagittal T2-weighted sequence demonstrates a small annular fissure along the posterior annular margin (*arrow*), judged Grade 4 by consensus. *B*, Sagittal postcontrast T1-weighted sequence demonstrates enhancement in the annular fissure (*arrow*). *C*, Axial postdiscogram CT image demonstrates a full-thickness radial annular fissure (*arrow*) projecting into a small peripheral concentric annular fissure (*arrowhead*). *D*, Axial postdiscogram CT image demonstrates the posterior annular margin at the level of the peripheral concentric annular fissure (*arrowhead*), which corresponds to the HIZ identified on the T2-weighted sequence and EAF region demonstrated on the postcontrast T1-weighted sequence.

In our series, an HIZ was not identified on the T2-weighted sequence in 16 of 39 (41%) discs positive for EAF (Table 2). Progressive loss of annular fissure/tear signal has been noted when followed with serial imaging.[24] Presumably, the fluid-filled fissure/tear changes or the granulation tissue in the fissure/tear region matures and reduces in signal intensity and therefore conspicuity.

These poorly identified annular fissures and tears were highly important in our series. Nine of the 11 discs judged as Grade 1 HIZ were not recognized on the T2 sequence by consensus group 2, and 7 of these 9 disc levels were associated with concordant provoked pain (Table 2). Recognizing enhancement within these less conspicuous fissures/tears could result in important concordant levels being included at discography. Using the identification of an EAF in addition to an HIZ represents a powerful combination in predicting discs with concordant pain.

The intradiscal anesthetic response is considered the best correlate to true disc-origin provoked pain.[25,26] This included evaluation of disc block, in which an anesthetic alone is injected into a putatively painful disc to assess baseline pain elimination. Consistent with prior reports, our data demonstrate that severely painful disc levels with complete pain relief typically had contrast leakage, while severely painful disc levels without pain improvement were usually contained (Table 6, $P < .01$).[16,19,21] Complete provoked pain improvement suggests that the disc is the primary source of the pain.[16,25,26] Partial pain reduction after intradiscal anesthetic suggests that the disc is a contributor but there is >1 pain source within the painful functional spinal unit (FSU). No pain improvement after intradiscal anesthetic suggests that other components of the FSU might be the primary contributors. An anesthetic response was seen at both concordant disc levels (total improvement, 12/31 discs; partial improvement, 7/31 discs) as well as nonconcordant disc levels (total improvement, 4/9 discs), strongly suggesting the true disc origin of all or a portion of the provoked pain.

Better specificity of true disc-origin LBP is becoming critical, in particular with evolving minimally invasive disc treatments such as biacuplasty, basivertebral nerve ablation, and intradiscal biologics. EAF identification might also improve correlation with more routine minimally invasive treatments such as epidural steroid administration.

Despite the presence of an EAF, presumably granulation tissue related to disc injury repair or local inflammation,[11,12,27-29]

Table 7: Intradiscal lidocaine response—40 concordant and nonconcordant severely painful discs where anesthetic was injected

	Intradiscal Lidocaine-Provoked Pain Response			
Disc State	Total Improvement (n = 17)	Partial Improvement (n = 7)	No Improvement (n = 16)	Total (n = 40)
Leaking	14 (82%)	2 (29%)	5 (31%)	21 (53%)
Contained	3 (18%)	5 (71%)	11 (69%)	19 (48%)
Total	17 (100%)	7 (100%)	16 (100%)	40 (100%)

contrast leak is seen in many of these discs at discography. Annular repair of these severely internally deranged discs may be incomplete, with altered biomechanical function, variable disc strength, motion-related intermittent fiber dehiscence, and/or inflammatory disc by-product leakage leading to nociceptor irritation.[27] Contrast leakage is observed in both EAF and nonenhancing discs with similar intradiscal anesthetic responses. Why some discs develop enhancing granulation while others do not is unclear, though local inflammation might play a role.

An EAF was seen at 7 nonpainful disc levels, all demonstrating features of severe internal derangement, including 3 with RDefs and 4 with severe DEG. It is possible that these discs have successfully healed with in-growth of granulation tissue accounting for the enhancement features. Absence of pain on provocation in these discs might be related to the granulation tissue either lacking innervation or preventing irritant leakage.

An EAF was also identified at 10 nonconcordant severely painful discs, 9 of which demonstrated severe internal derangement on postdiscogram CT. These abnormal discs may also have healed with in-growth of granulation tissue. The nonconcordant pain might be coming from nociceptors in the disc-associated granulation tissue or pain provoked from other parts of the FSU, which were stimulated by disc injection but were not normally painful. With the high prevalence of disc degeneration in asymptomatic patients,[3,30] it is not surprising that normally asymptomatic internally deranged discs are encountered in symptomatic patients at discography.

It is important to identify nonconcordant and nonpainful disc levels with an EAF because these would not be targets for disc-focused interventional treatments. Mechanisms have been proposed for the development of chronic LBP, including injury-activation of latent pain fibers,[31] irritant alteration of spontaneous pain fiber firing,[32] irritant-related neural phenotypic shift,[33] and central sensitization.[34,35] A noninvasive imaging method separating chronically triggered nociceptors (ie, concordant pain) from quiescent pain fibers would be advantageous, in particular with reference to a visible putative target such as granulation tissue in discs positive for EAF.

Consistent with prior reports, our data support an HIZ remaining a strong predictor of concordant provoked pain ($P =$ .007; sensitivity, 39%; specificity, 86%) on preprocedural MR imaging in patients with chronic LBP.[4-6,8-10] An HIZ was also strongly predictive of disc levels with severe pain overall ($P =$ .005; sensitivity, 40%) with high specificity (94%). All discs with an HIZ also demonstrated an EAF. An HIZ, therefore, appears highly specific for the concordant and nonconcordant pain provoked at discography.

A recent study evaluating FSU motion with disc injection demonstrates endplate elevation frequently with rocking, accentuating separation in the posterior annular region along with substantial facet motion.[18] Disc injection biomechanically challenges the entire FSU in addition to inducing disc/endplate pressurization. In concordant disc levels, annular stretch in the region of the EAF (granulation tissue), disc irritant leakage, or even the posterior elements could be responsible for the provoked pain. In nonconcordant disc levels, similar areas of degeneration, disc leakage, or granulation tissue might be present but quiescent until challenged either with disc injection or physical activity (mechanical irritation, injury-activation). An EAF (suggesting granulation tissue) was present in 3 of 4 nonconcordant significantly painful discs that demonstrated total pain improvement with intradiscal anesthetic. Further assessment might be important to better understand the exact sources of pain in the disc.

Limitations

Our study has several limitations. Discography remains a controversial procedure but is the only study with which we can challenge or physically examine the disc to assess pain provocation/concordance. While the observations encountered at PLD are routinely encountered at discography (concordant pain, nonconcordant pain, absent provoked pain), the criterion standard for disc origin or discogenic LBP is as yet not clearly defined. Comprehensive correlation between discography observations (including anesthetic response) and treatment results will likely improve our understanding of PLD as well as our understanding of true disc-origin LBP. Despite a large discography population, our sample size of patients with enhanced preprocedural imaging is small, because most patients have routine unenhanced imaging before the test. A larger patient population could reinforce the findings of this study. Discography is not yet a standardized procedure, with variable techniques practiced by different interventionalists. It is unknown whether our findings apply to all technique approaches, including slow injection with pressure monitoring as opposed to our more rapid hand-injection technique. While these observations appear to apply to a patient population with chronic severe LBP in which an operation is being considered, it is as yet unclear whether these observations would apply to the patient with short-duration LBP or less severe symptoms. More comprehensive MR imaging techniques could also be used to evaluate the presence of enhancing/nonenhancing annular fissures, supplementing these results.

CONCLUSIONS

An HIZ noted on preprocedural MR imaging remains an important predictor of a disc level with severe and/or concordant provoked pain in patients with chronic LBP referred for PLD.

EAFs were more frequently identified than HIZs on preprocedural MR imaging in our patients with chronic LBP referred for PLD. Independently, EAFs were strongly predictive of disc levels with severe and/or concordant provoked pain, demonstrating greater sensitivity than an HIZ and retaining high overall accuracy. EAFs identified at disc levels without a recognizable HIZ are also strongly associated with severe and/or concordant provoked pain, thereby substantially improving the stand-alone ability of the HIZ to predict severe and/or concordant pain. Annular fissures and tears appear more confidently identified after contrast administration, likely due to in-growth of granulation tissue and scar maturation.

Better identification of annular fissures could aid in planning levels studied at discography and further aid in preoperative planning when minimally invasive techniques like biacuplasty, basivertebral nerve ablation, and intradiscal biologics or surgery are considered for axial LBP.

Disclosure forms provided by the authors are available with the full text and PDF of this article at www.ajnr.org.

REFERENCES

1. Weishaupt D, Zanetti M, Hodler J, et al. **MR imaging of the lumbar spine: prevalence of intervertebral disk extrusion and sequestration, nerve root compression, end plate abnormalities, and osteoarthritis of the facet joints in asymptomatic volunteers.** *Radiology* 1998; 209:661–66 CrossRef Medline
2. Stadnik TW, Lee RR, Coen HL, et al. **Annular tears and disk herniation: prevalence and contrast enhancement on MR images in the absence of low back pain or sciatica.** *Radiology* 1998;206:49–55 CrossRef Medline
3. Jarvik JJ, Hollingworth W, Heagerty P, et al. **The Longitudinal Assessment of Imaging and Disability of the Back (LAIDBack) study: baseline data.** *Spine (Phila Pa 1976)* 2001;26:1158–66 CrossRef Medline
4. Aprill C, Bogduk N. **High-intensity zone: a diagnostic sign of painful lumbar disc on magnetic resonance imaging.** *Br J Radiol* 1992;65:361–69 CrossRef Medline
5. Schellhas KP, Pollei SR, Gundry CR, et al. **Lumbar disc high-intensity zone: correlation of magnetic resonance imaging and discography.** *Spine (Phila Pa 1976)* 1996;21:79–86 CrossRef Medline
6. Saifuddin A, Braithwaite I, White J, et al. **The value of lumbar spine magnetic resonance imaging in the demonstration of annular tears.** *Spine (Phila Pa 1976)* 1998;23:453–57 CrossRef Medline
7. Carragee EJ, Paragioudakis SJ, Khurana S. **2000 Volvo Award winner in clinical studies: lumbar high-intensity zone and discography in subjects without low back problems.** *Spine (Phila Pa 1976)* 2000;25:2987–92 CrossRef Medline
8. Chen JY, Ding Y, Lv RY, et al. **Correlation between MR imaging and discography with provocative concordant pain in patients with low back pain.** *Clin J Pain* 2011;27:125–30 CrossRef Medline
9. Fang C, Zhang W, Chen L, et al. **The correlation between the high-intensity zone on a T2-weighted MRI and positive outcomes of discography: a meta-analysis.** *J Orthop Surg Res* 2017;12:26 CrossRef Medline
10. Chelala L, Trent G, Waldrop G, et al. **Positive predictive values of lumbar spine magnetic resonance imaging findings for provocative discography.** *J Comput Assist Tomogr* 2019;43:568–71 CrossRef Medline
11. Peng B, Hou S, Wu W, et al. **The pathogenesis and clinical significance of a high-intensity zone (HIZ) of lumbar intervertebral disc on MR imaging in the patient with discogenic low back pain.** *Eur Spine J* 2006;15:583–87 CrossRef Medline
12. Saifuddin A, Mitchell R, Taylor BA. **Extradural inflammation associated with annular tears: demonstration with gadolinium-enhanced lumbar spine MRI.** *Eur Spine J* 1999;8:34–39 CrossRef Medline
13. Ross JS, Modic MT, Masaryk TJ. **Tears of the anulus fibrosus: assessment with Gd-DTPA-enhanced MR imaging.** *AJR Am J Roentgenol* 1990;154:159–62 CrossRef Medline
14. Pfirrmann CW, Metzdorf A, Zanetti M, et al. **Magnetic resonance classification of lumbar intervertebral disc degeneration.** *Spine (Phila Pa 1976)* 2001;26:1873–78 CrossRef Medline
15. Walsh TR, Weinstein JN, Spratt KF, et al. **Lumbar discography in normal subjects: a controlled, prospective study.** *J Bone Joint Surg Am* 1990;72:1081–88 CrossRef Medline
16. Bartynski WS, Rothfus WE. **Pain improvement after intradiskal lidocaine administration in provocation lumbar diskography: association with diskographic contrast leakage.** *AJNR Am J Neuroradiol* 2007;28:1259–65 CrossRef Medline
17. Derby R, Lee SH, Lee JE, et al. **Comparison of pressure-controlled provocation discography using automated versus manual syringe pump manometry in patients with chronic low back pain.** *Pain Med* 2011;12:18–26 CrossRef Medline
18. Bartynski WS, Agarwal V, Khan AS, et al. **Motion characteristics of the functional spinal unit during lumbar disc injection (discography) including comparison between normal and degenerative levels.** *Pain Med* 2021;22:1735–42 CrossRef Medline
19. Bartynski WS, Rothfus WE, Kurs-Lasky M. **Postdiskogram CT features of lidocaine-sensitive and lidocaine-insensitive severely painful disks at provocation lumbar diskography.** *AJNR Am J Neuroradiol* 2008;29:1455–60 CrossRef Medline
20. Sachs BL, Vanharanta H, Spivey MA, et al. **Dallas discogram description: a new classification of CT/discography in low-back disorders.** *Spine (Phila Pa 1976)* 1987;12:287–94 CrossRef Medline
21. Bartynski WS, Rothfus WE. **Peripheral disc margin shape and internal disc derangement: imaging correlation in significantly painful discs identified at provocation lumbar discography.** *Interv Neuroradiol* 2012;18:227–41 CrossRef Medline
22. Coppes MH, Marani E, Thomeer RT, et al. **Innervation of "painful" lumbar discs.** *Spine (Phila Pa 1976)* 1997;22:2342–49; discussion 2349–50 CrossRef Medline
23. Fagan AB, Sarvestani G, Moore RJ, et al. **Innervation of anulus tears: an experimental animal study.** *Spine (Phila Pa 1976)* 2010;35:1200–05 CrossRef Medline
24. Munter FM, Wasserman BA, Wu HM, et al. **Serial MR imaging of annular tears in lumbar intervertebral disks.** *AJNR Am J Neuroradiol* 2002;23:1105–09 Medline
25. Derby R, Lee JE, Lee SH. **Analgesic discography: effect of adding a local anesthetic to routine lumbar provocation discography.** *Pain Med* 2010;11:1335–42 CrossRef Medline
26. Derby R, Aprill CN, Lee JE, et al. **Comparison of four different analgesic discogram protocols comparing the incidence of reported pain relief following local anesthetic injection into concordantly painful lumbar intervertebral discs.** *Pain Med* 2012;13:1547–53 CrossRef Medline
27. Hirsch C, Schajowicz F. **Studies on structural changes in the lumbar annulus fibrosus.** *Acta Orthop Scand* 1952;22:184–231 CrossRef Medline
28. McCarron RF, Wimpee MW, Hudkins PG, et al. **The inflammatory effect of nucleus pulposus: a possible element in the pathogenesis of low-back pain.** *Spine (Phila Pa 1976)* 1987;12:760–64 CrossRef Medline
29. Ross JS, Modic MT, Masaryk TJ, et al. **Assessment of extradural degenerative disease with Gd-DTPA-enhanced MR imaging: correlation with surgical and pathologic findings.** *AJR Am J Roentgenol* 1990;154:151–57 CrossRef Medline
30. Boos N, Semmer N, Elfering A, et al. **Natural history of individuals with asymptomatic disc abnormalities in magnetic resonance imaging: predictors of low back pain-related medical consultation and work incapacity.** *Spine (Phila Pa 1976)* 2000;25:1484–92 CrossRef Medline
31. Avramov AI, Cavanaugh JM, Ozaktay CA, et al. **The effects of controlled mechanical loading on group-II, III, and IV afferent units from the lumbar facet joint and surrounding tissue: an in vitro study.** *J Bone Joint Surg Am* 1992;74:1464–71 Medline
32. Yamashita T, Cavanaugh JM, Ozaktay AC, et al. **Effect of substance P on mechanosensitive units of tissues around and in the lumbar facet joint.** *J Orthop Res* 1993;11:205–14 CrossRef Medline
33. Ohtori S, Takahashi K, Chiba T, et al. **Phenotypic inflammation switch in rats shown by calcitonin gene-related peptide immunoreactive dorsal root ganglion neurons innervating the lumbar facet joints.** *Spine (Phila Pa 1976)* 2001;26:1009–13 CrossRef Medline
34. Siddall PJ, Cousins MJ. **Introduction to pain mechanisms: implications for neural blockade.** In: Cousins MJ, Horlocker TT, Bridenbaugh PO. *Neural Blockade In Clinical Anesthesia and Pain Medicine*. Fourth Edition. Lippincott Williams & Wilkins; 2009:661–692. https://aneskey.com/introduction-to-pain-mechanisms-implications-for-neural-blockade/. Accessed December 11, 2022
35. Woolf CJ. **Central sensitization: implications for the diagnosis and treatment of pain.** *Pain* 2011;152:S2–15 CrossRef Medline