

Generic Contrast Agents

Our portfolio is growing to serve you better. Now you have a *choice*.



[VIEW CATALOG](#)

AJNR

Aneurysm Treatment with Woven EndoBridge-17: Angiographic and Clinical Results at 12 Months from a Retrospective, 2-Center Series

P. Pagano, J. Cortese, S. Soize, J. Caroff, P.F. Manceau, J. Moret, L. Spelle and L. Pierot

This information is current as
of May 4, 2025.

AJNR Am J Neuroradiol 2023, 44 (4) 467-473

doi: <https://doi.org/10.3174/ajnr.A7830>

<http://www.ajnr.org/content/44/4/467>

Aneurysm Treatment with Woven EndoBridge-17: Angiographic and Clinical Results at 12 Months from a Retrospective, 2-Center Series

 P. Pagano,  J. Cortese,  S. Soize,  J. Caroff,  P.F. Manceau,  J. Moret,  L. Spelle, and  L. Pierot



ABSTRACT

BACKGROUND AND PURPOSE: This retrospective, 2-center study investigated the feasibility, safety, and efficacy at 12-month follow-up of the treatment of ruptured, unruptured, and recurrent intracranial aneurysms using the latest generation of the Woven EndoBridge (WEB) device, the WEB-17 system.

MATERIALS AND METHODS: Aneurysms treated with WEB-17 were extracted from the databases of 2 neurovascular centers. Patients, aneurysm characteristics, complications, and clinical and anatomic results were analyzed.

RESULTS: From February 2017 to May 2021, two hundred twelve patients with 233 aneurysms (181/233, 77.7%, unruptured-recurrent, and 52/233, 22.3%, ruptured) were included. High treatment feasibility (95.3%) was reported and was similar in ruptured aneurysms (94.2%) and unruptured-recurrent aneurysms (95.6%) ($P = .71$) and in typical (95.4%) and atypical (94.7%) locations ($P = .70$), but it was lower in aneurysms with an angle between the parent artery and main aneurysm axis of $\geq 45^\circ$ (90.2%) compared with those with an angle of $< 45^\circ$ (97.1%) ($P = .03$). Global mortality and morbidity were 1.9% and 3.8% at 1 month, respectively, and 4.4% and 1.9% at 12 months, respectively. One-month morbidity ($P = .02$) and mortality ($P = .003$) were higher in the ruptured group (10.0% and 8.0%, respectively) compared with unruptured-recurrent group (1.9% and 0.0%, respectively). Overall adequate occlusion (complete occlusion and neck remnant) was 86.3%. The percentage of adequate occlusion was higher ($P = .05$) in the unruptured-recurrent group (88.5%) compared with the ruptured group (77.5%).

CONCLUSIONS: The WEB-17 system showed high feasibility for ruptured and unruptured aneurysms, typical and atypical locations, and some aneurysms with an angle of $\geq 45^\circ$. As the most recent generation device, the WEB-17 also demonstrates high safety and good efficacy.

ABBREVIATIONS: AcoA = anterior choroidal artery; AcomA = anterior communicating artery; EVT = endovascular treatment; FD = flow diverter; IA = intracranial aneurysm; WEB = Woven EndoBridge; WEB-DL = Woven EndoBridge Dual-Layer; WEB-SL/SLS = Woven EndoBridge Single-Layer and Single-Layer Sphere; WFNS = World Federation of Neurosurgical Societies

During the past 10 years, the intrasaccular Woven EndoBridge (WEB; MicroVention) device has completely changed endovascular treatment (EVT) of wide-neck intracranial aneurysms (IAs). After its introduction in Europe for clinical use,¹ the WEB


device evolved from the initial dual-layer (DL) version (WEB-DL) to the 2 single-layer (SL) versions (WEB-SL and WEB-SLS [single layer spherical]) and finally the enhanced visualization version that introduced drawn filled tubing technology to improve device fluoroscopy visibility.² In parallel, WEB-specific microcatheters (VIA microcatheters; Sequent Medical) were designed to facilitate WEB deployment (VIA -33, VIA -27, and VIA -21). The most recent advance of the WEB device is the 17 system that permits delivery of small WEB devices (width = ≤ 7 mm) through a 0.017-inch microcatheter. Additional WEB sizes have also been introduced, including a small device (width = 3 mm), half sizes (widths = 3.5 and 4.5 mm), and shallow devices with a 2-mm height.

The WEB was initially developed to treat wide-neck bifurcation aneurysms, specifically located at the MCA bifurcation, basilar artery tip, ICA terminus, and anterior communicating artery

Received November 10, 2022; accepted after revision February 23, 2023.

From the Department of Neuroradiology (P.P., S.S., P.F.M., L.P.), Hôpital Maison Blanche, Centre Hospitalier Universitaire, Reims, France; Faculty of Medicine (P.P., S.S., L.P.), Champagne-Ardenne University, Reims, Grand-Est, France; NEURI Brain Vascular Center (J. Cortese, J. Caroff, J.M., L.S.), Bicêtre Hospital Interventional Neuroradiology, Le Kremlin-Bicêtre, France; and Faculty of Medicine (J. Cortese, L.S.), Paris-Saclay University, L'Institut National de la Santé et de la Recherche Médicale U1195, Le Kremlin-Bicêtre, France.

Please address correspondence to Paolo Pagano, MD, Department of Neuroradiology, Hôpital Maison-Blanche, 45 rue Cognacq-Jay, 51092 Reims cedex, France; e-mail: paolopagano6@gmail.com

 Indicates open access to non-subscribers at www.ajnr.org

 Indicates article with online supplemental data.

<http://dx.doi.org/10.3174/ajnr.A7830>

(AcomA).²⁻¹⁰ Because the device is strictly endosaccular, there is no need for dual-antiplatelet treatment after WEB treatment, making it possible to treat unruptured and recurrent aneurysms as well as ruptured aneurysms.¹¹⁻²⁰

The Clinical Assessment of the WEB Device in the Ruptured Aneurysms (CLARYS) study recently confirmed the effectiveness of the WEB device in preventing aneurysm re-rupture in ruptured aneurysms.¹⁸ In parallel to the technical evolution of the WEB device, its indications progressively enlarged to distal and sidewall aneurysms.¹¹⁻¹³

Several multicenter prospective series, including WEB Clinical Assessment of Intracranial Aneurysm Therapy (WEBCAST),³ WEBCAST 2,⁵ French Observatory,⁶ WEB Intracranial Aneurysm Therapy (WEB-IT),¹⁰ and CLARYS,²¹ have demonstrated favorable safety and efficacy of EVT with the WEB device; however, these studies were conducted before the introduction of the 17 system.

Given the limited data available regarding the safety and efficacy of the WEB-17 device,^{14,22-27} this retrospective 2-center study aimed to evaluate the feasibility, safety, and efficacy at mid-term follow-up (12 months) after the treatment of ruptured, unruptured, and recurrent IAs using WEB-17 system.

MATERIALS AND METHODS

Study Design

This retrospective, observational study included patients from 2 French neurovascular centers (Centre Hospitalier Universitaire, Reims and NEURI brain Vascular Center, Le Kremlin-Bicêtre). Both centers maintain an institutional prospective database that includes all patients treated with EVT for IA. From these databases, all patients treated with the WEB-17 until May 2021 were enrolled in the study.

The Comité d'Éthique pour la Recherche en Imagerie Médicale of Collège des Enseignants de Radiologie de France approved this retrospective study and waived written informed consent due to the retrospective study design (Institutional Review Board No. CRM-2207-293).

WEB Device

The WEB device consists of self-expanding, retrievable, electrothermally detachable, intrasaccular implants developed for the treatment of wide-neck bifurcation aneurysms.^{1,10,22-25,27} The WEB-17 is available in 2 configurations: WEB-SL (size range, 3 × 2 to 7 × 4 mm) and a more spherical WEB-SLS (size range, 4–7 mm).²⁷ The WEB-17 system debuted in Europe in December 2016²² and is available in a small size (3 × 2 mm), in half sizes for the smallest size (with widths of 3.5 and 4.5 mm), and for shallow devices (with a 2-mm height for devices with a width between 3 and 5 mm). It is compatible with a straight or preshaped 0.017-inch microcatheter (VIA-17).²⁵

Procedure

In the 2 centers, the decision for EVT was reached by consensus with neurosurgeons and neuroradiologists. Pre-, intra-, and postoperative antiplatelet therapy was similar in the 2 centers. For unruptured and recurrent aneurysms, dual-antiplatelet treatment with 75 or 160 mg of aspirin and 180 mg of ticagrelor per day

was given 1 or 2 days preprocedure; if no stent was placed, ticagrelor was discontinued after the intervention and aspirin was maintained for 1 month. For ruptured aneurysms, aspirin, 250 mg IV, was administered during the procedure followed by oral aspirin for 1 month.

All procedures were performed on a biplane angiographic system (AlluraClarity; Philips Healthcare) with the patient under general anesthesia and systemic heparinization with triaxial access. The distal tip of VIA-17 microcatheter was always shaped with steam. The WEB size was selected according to measurements performed on 3D DSA: The WEB is typically oversized by 1 mm in width and undersized in height by 1 mm.

Follow-up

Follow-up was similar in both centers with 3- to 6-month and 12- to 18-month clinical and anatomic follow-up.

Data Collection

The following data were collected for each patient:

- Demographics: age and sex
- Aneurysm: location, status (ruptured, unruptured, and recurrent), and size (mean width, maximal width, maximal height, and maximal neck size); dome-to-neck ratio; angle between parent artery and main aneurysm axis
- Procedure: date, type (SL/SLS), and dimension of WEB used; additional device used; intra- and postprocedural complications;
- Retreatment of target aneurysm before the 12-month follow-up
- Angiographic and clinical follow-up at 12 months.

Data Analysis

Data analysis was performed by an interventional neuroradiologist (P.P.) independently of the procedures and clinical evaluations.

According to the initial WEB treatment indications, aneurysm location was classified into 2 groups:

- Typical location: AcomA, MCA bifurcation, ICA terminus, and basilar tip
- Atypical location: other ICA locations (ophthalmic, posterior communicating artery, anterior choroidal artery [AchoA]), A1-A2 segment, anterior-inferior cerebellar artery, posterior-inferior cerebellar artery, and superior cerebellar artery.

Aneurysms were dichotomized as wide-neck (neck of ≥ 4 mm or dome-to-neck ratio of <2) and narrow-neck. Aneurysms were also classified in 2 groups according to the angle (α) between the parent artery and the neck-to-fundus axis ($\alpha < 45^\circ$ and $\alpha \geq 45^\circ$). The α was measured with 3D-DSA images.

For patients with ruptured aneurysms, the World Federation of Neurosurgical Societies (WFNS) grade before aneurysm treatment was collected. For all patients, pre- and postoperative clinical status was evaluated using the mRS. In patients with SAH, the mRS was evaluated on the basis of patient, family, or caregiver reports.

All complications were reviewed and classified into 4 categories: intraprocedural thromboembolic, intraprocedural hemorrhagic, site of puncture, and postoperative (postprocedure and before 1 month). Complications were classified into 4 groups: no

symptoms, transitory deficit (when the duration of symptoms was <7 days), permanent deficit (when the duration of symptoms was ≥7 days), and death.

Morbidity was defined as mRS > 2 when the preoperative mRS was ≤2 and as an increase of 1 point when the preoperative mRS was >2. Morbidity and mortality were classified as procedure-related (related to all steps and all devices used during the procedure, including the WEB), SAH-related, and related to another disease.

Feasibility was evaluated in the global population and in relation to aneurysm status, to α ($\alpha < 45^\circ$ and $\alpha \geq 45^\circ$), and to location (typical and atypical). Aneurysm occlusion was evaluated with 12-month DSA using a 3-point scale: complete aneurysm occlusion, neck remnant, and aneurysm remnant. Clinical and angiographic results were evaluated in the global population and in 2 subgroups: unruptured-recurrent and ruptured aneurysms.

Statistical Analysis

Distribution normality was assessed using the Shapiro-Wilk test. Continuous variables were described as mean (SD) or median and interquartile range and were compared using the Student *t* test or Mann-Whitney *U* test. Categorical variables were presented as counts and compared using the χ^2 or Fisher exact test. ORs and their 95% CIs were calculated. A *P* value < .05 was considered statistically significant. Analyses were performed using MedCalc for Windows (Release 18.2; MedCalc Software).

RESULTS

Patients and Aneurysms

From February 2017 to May 2021, two hundred sixty patients with 281 aneurysms were treated with the WEB. During 224 procedures, 212/260 (81.5%) patients with 233/281 (82.9%) aneurysms were treated with the WEB-17, of whom 133/212 (62.7%) were women (Online Supplemental Data). The mean age was 55.2 (SD, 11.4) years. In 50/212 (23.6%) patients, 52/233 (22.3%) aneurysms were ruptured (WFNS score I for 25 patients, II for 12 patients, III for 4 patients, IV for 5 patients, and V for 4 patients). Three of 233 aneurysms (1.3%) were recurrent. Due to the small number, recurrent aneurysms were analyzed with the unruptured group.

Treatment Feasibility

The WEB was successfully implanted in 222/233 (95.3%) aneurysms, including 173/181 (95.6%) unruptured-recurrent and 49/52 (94.2%) ruptured (*P* = .71) aneurysms. Aneurysms were treated with the WEB-SL (188/222, 84.7%) or WEB-SLS (34/222, 15.3%). Feasibility was higher in the $\alpha < 45^\circ$ group (167/172, 97.1%) compared with the $\alpha \geq 45^\circ$ group (55/61, 90.2%) (*P* = .03) but was similar for aneurysms in typical locations (186/195, 95.4%) and atypical locations (36/38, 94.7%) (*P* = .70). Adjunctive devices (including balloons) were used in 42/222 (18.9%) aneurysms (Table).

A remodeling balloon, with or without an implantable device (flow diverter [FD], stent, or coils) was inflated in 25/220 (11.4%) WEB aneurysm treatments: 6/220 (2.7%) in aneurysms with $\alpha \geq 45^\circ$ and 3/220 (1.3%) in atypical locations.

A stent or FD, with or without a balloon, was used in 19/222 (8.5%) procedures, all of them for unruptured-recurrent

aneurysms (19/173, 10.9%). In 4/222 (1.8%) procedures, the WEB aneurysm treatment was performed with coils (2/173, 1.2%, unruptured-ruptured, and 2/49, 4.1%, ruptured), and in 1 procedure (1/222, 0.5%) using the WEB, coils and balloon were used to treat a ruptured aneurysm (1/49, 2.0%).

Treatment failed in 11/233 (4.7%) aneurysms (8/181 unruptured-recurrent, 4.4%; 3/52 ruptured, 5.8%): in 2 cases, the smallest WEB (WEB-SL, 3 × 2 mm) was too large; in 1 recurrent aneurysm initially treated with coiling, the WEB-SL was unstable in the aneurysm sac; in 8 procedures, 2 different WEB devices were deployed but did not adequately close the neck.

Complications were encountered in 2 of these 11 failed WEB treatments: In 1 patient treated with balloon-assisted coiling (BAC) for an unruptured AcomA aneurysm, perforation occurred during aneurysm coiling, leading to a small SAH without clinical worsening (mRS 0 at discharge); in the second situation 7 days posttreatment of an MCA bifurcation aneurysm with an FD, the patient experienced intrastent thrombosis with clinical worsening (the mRS at discharge and 12 months was 4).

Complications and Morbidity-Mortality at 1 Month

Complications are detailed in the Online Supplemental Data. Among 224 procedures, 15 (6.7%) thromboembolic intraprocedural events occurred. In 10 procedures, distal emboli were treated with intra-arterial administration of antiplatelet treatment (abciximab or tirofiban) in 8 procedures and no additional treatment in 2 procedures. mRS at discharge was 0 in 6 patients, 1 in 3 patients, and 2 in 1 patient. Four patients treated for ruptured AcomA aneurysms had thrombosis of the pericallosal artery treated by intra-arterial administration of aspirin and/or tirofiban. In 2 patients, the clot was successfully dissolved, but the patients died due to SAH (WFNS = V and WFNS = IV). In 2 other patients, the clot was not dissolved and clinical evolution was deleterious (death at 45 days and mRS 4 at discharge and 12 months, respectively). Finally, 1 patient treated for an unruptured MCA aneurysm with the WEB and a stent had intrastent thrombosis successfully treated with intra-arterial tirofiban (mRS 1 at discharge).

A hemorrhagic intraprocedural complication occurred in 3/224 (1.3%) procedures. One patient treated with the WEB and a balloon for an unruptured A2 aneurysm experienced aneurysm rupture during balloon inflation (producing a large SAH leading to death 50 days later). In 1 patient treated for an unruptured AcomA aneurysm, WEB treatment failed and a minor hemorrhagic complication occurred during aneurysm coiling (see above). In a patient with an unruptured MCA aneurysm, a sac perforation occurred during catheterization with a microwire and was managed by WEB deployment. Postoperative CT showed limited SAH with slight clinical worsening (mRS 1 at discharge and 0 at 12 months).

In 2/224 (0.8%) procedures, there were complications at the puncture site, treated with surgery or endovascularly. In both cases, no clinical consequences at discharge were reported.

Postprocedural complications were reported in 16/224 (7.1%) procedures. No delayed hemorrhagic complication (including bleeding/rebleeding of the aneurysm) was observed. Twelve patients experienced slight motor deficits a few days postprocedure with DWI-detected lesions in only 4 patients.

Treatment modalities^a

	Total (n = 222)	Unruptured and Recurrent Aneurysms (n = 173)	Ruptured Aneurysms (n = 49)	P Value
WEB alone	180 (81.1)	136 (78.6)	44 (89.8)	.08
WEB + another device (No.) (%)	42 (18.9)	37 (21.4)	5 (10.2)	
WEB-coils	4 (1.8)	2 (1.2)	2 (4.1)	
WEB-stent	11 (4.9)	11 (6.4)	0 (0)	
WEB-balloon	18 (8.1)	16 (9.2)	2 (4.1)	
WEB-FD	2 (0.9)	2 (1.2)	0 (0)	
WEB-stent-balloon	5 (2.2)	5 (2.9)	0 (0)	
WEB-coils-balloon	1 (0.5)	0 (0)	1 (2.0)	
WEB-FD-balloon	1 (0.5)	1 (0.5)	0 (0)	
WEB type (No.) (%)				.26
WEB-SL	188 (84.7)	144 (83.2)	44 (89.8)	
WEB-SLS	34 (15.3)	29 (16.8)	5 (10.2)	

^a Categorical variables are described as a number (percentage).

All 12 patients were treated medically (oral or IV antiplatelet medication) and had good clinical outcomes (mRS at discharge 0 in 10 patients and 1 in 2 patients). A patient treated for an ICA-AchoA unruptured aneurysm with the WEB only had an ischemic stroke 5 days postprocedure related to a WEB protrusion. One stent was placed in front of the neck during a second procedure, but intrastent thrombosis and a pericallosal embolic complication occurred and were unresolved at the procedure end despite the administration of an intra-arterial antiplatelet drug. The mRS at discharge and at 12 months was 4. Two patients experienced non-neurologic complications: pneumonia and acute lower limb ischemia in 1 patient (mRS 4 at discharge, stable compared with preoperative status) and pneumonia in 1 patient (mRS at discharge was 2, and it was 0 at 12 months).

In 1 case of WEB failure, one patient was treated with an FD but experienced an intrastent thrombosis 7 days after the treatment (see above).

Finally, 36/212 (16.9%) patients had intraprocedural or postprocedural complications: no symptoms in 10/212 (4.7%), transitory symptoms in 16/212 (7.5%), permanent deficit in 6/212 (2.8%), and death in 4/212 (1.8%). Two of these 4 patients died after 1 month and were not included in mortality at 1 month but were included in the mortality at 12-month evaluation (both considered procedure-related deaths). The other 2 patients had a thromboembolic intraprocedural complication and died 2 days posttreatment due to the severity of SAH (WFNS = V and WFNS = IV); these deaths were considered SAH-related and were included in the mortality at 1-month evaluation.

The overall morbidity and mortality at 1 month were 8/212 (3.8%) and 4/212 (1.9%), respectively. Morbidity was higher in patients with ruptured aneurysms than in those with unruptured-recurrent aneurysms (5/50, 10.0%, versus 3/162, 1.9%, respectively) ($P = .02$). Morbidity was procedure-related in 5/212 (2.4%; 2 of them WEB-related, 2/212, 1.0%) and SAH-related in 3/212 (1.4%). Mortality was higher in patients with ruptured aneurysms than in those with unruptured or recurrent aneurysms (4/50, 8.0%, versus 0/162, 0.0%, respectively) ($P = .003$). Mortality was related to SAH in all patients.

Angiographic and Clinical Results at 12 Months

The Figure illustrates the participant flow chart for safety and efficacy analysis. Among the baseline population of 212 patients and 233 aneurysms, 205 patients (96.7%) and 197 aneurysms (84.5%) had 12-month follow-up (mean for 12-month DSA, 12.6 [SD, 4.9] months).

Safety at 12 Months. The overall morbidity was 4/205 (1.9%), and no statistical difference was reported between the unruptured-recurrent group (2/156, 1.2%) and the ruptured group (2/49, 4.0%) ($P = .24$). Morbidity was procedure-related in 3/205 (1.4%; 1 was WEB-related, 1/205, 0.5%) and SAH-related in 1/205 (0.5%).

The overall mortality rate was 9/205 (4.4%) and was significantly higher in the ruptured group (7/49, 14.3%) compared with unruptured-recurrent group (2/156, 1.2%) ($P = .0008$). Mortality was procedure-related in 2/205 (1.0%; 1 was WEB-related, 1/205, 0.5%), SAH-related in 6/205 (2.9%), and due to unrelated disease in 1/205 (0.5%).

Efficacy. Complete occlusion was reported in 133/197 (67.5%) aneurysms; neck remnant, in 37/197 (18.8%); and aneurysm remnant, in 27/197 (13.7%). In the unruptured-recurrent group, 108/157 (68.8%), 31/157 (19.7%), and 18/157 (11.5%) aneurysms had complete occlusion, neck remnant, and aneurysm remnant, respectively, and in the ruptured group, they were 25/40 (62.5%), 6/40 (15.0%), and 9/40 (22.5%), respectively.

Adequate occlusion (complete occlusion and neck remnant) in the overall population was 170/197 (86.3%). The percentage of adequate occlusion was higher ($P = .05$) in the unruptured-recurrent group (139/157, 88.5%) versus the ruptured group (31/40, 77.5%).

There were 4/197 aneurysms (2.0%) retreated before 12 months: 2/157 (1.3%) in the unruptured-recurrent group and 2/40 (5.0%) in the ruptured group ($P = .18$). Two aneurysms were treated with an FD; 1, with coiling; and 1, with stent-assisted coiling. At the time of retreatment, occlusion status was aneurysm remnant in the 4 aneurysms. Retreatment took place 5.2, 6.0, 8.5, and 9.6 months after the initial WEB procedure.

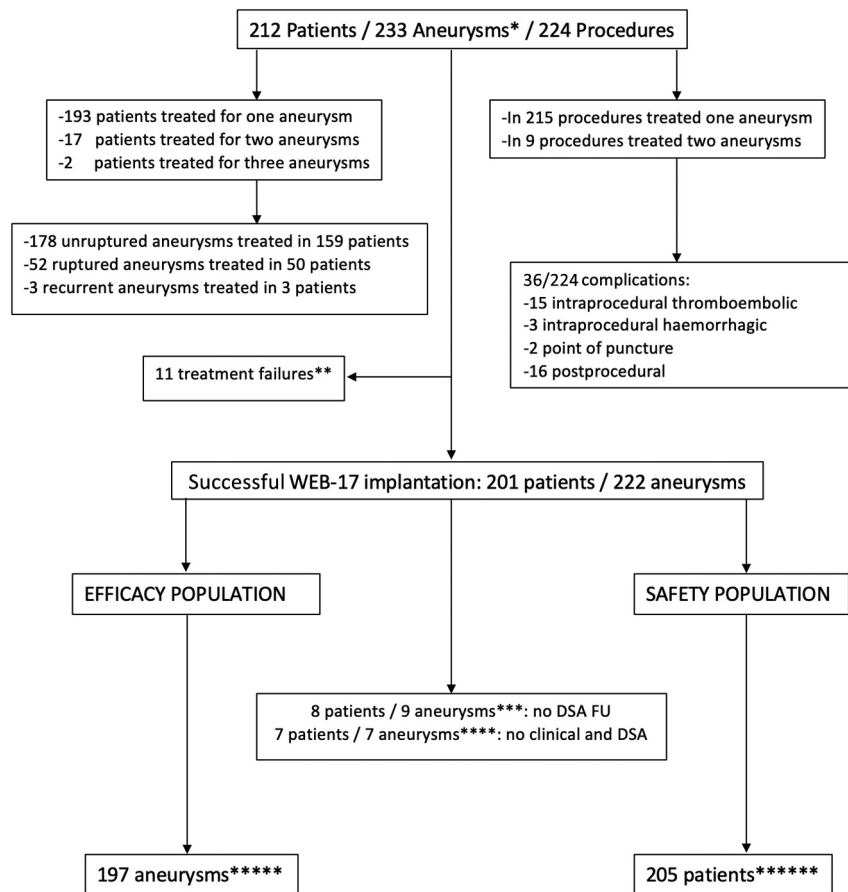


FIGURE Study flow chart. *All aneurysms treated with WEB-17 system. **See Treatment Feasibility in the text ***Seven patients refused DSA, and 1 patient had a comorbidity that prevented DSA; all 8 patients had clinical FU. ****Seven patients were lost to FU. *****Nine patients with 9 aneurysms died. Four were described in the mortality at 1-month evaluation (SAH-related); 4/9 patients died >1 month posttreatment (2 related to complications and 2 related to SAH severity); 1/9 patients died due to unrelated disease (hepatic carcinoma). *****Safety was assessed for 11 treatment failures. FU indicates follow-up.

DISCUSSION

This analysis of aneurysm treatment with the WEB-17 system shows its high feasibility (95.3%), with a complication rate of 16.9% (36/212 patients), most of them associated with no or transient clinical worsening. Global mortality and morbidity rates were 1.9% (4/212 patients) and 3.8% (8/212 patients) at 1 month, respectively, and 4.4% (9/205 patients) and 1.9% (4/205 patients) at 12 months, respectively. All deaths at 1 month were related to SAH, and most deaths (7/9, 77.8%) at 12 months were related to SAH or unrelated disease. Finally, the anatomic results at 12 months confirm the high efficacy of WEB treatment with complete aneurysm occlusion in 67.5% (133/197 aneurysms), neck remnant in 18.8% (37/197), and aneurysm remnant in 13.7% (27/197).

Mortality at 1 month was 1.9% (all SAH-related) compared with 0.0% in the 3 European Good Clinical Practice studies (WEBCAST, WEBCAST-2, and the French Observatory) or WEB-IT,^{3,5-7,10} in which the percentage of ruptured aneurysms was much lower (8.3% and 6.0%, respectively) compared with this series (22.3%). Similarly, at 12 months, most deaths (7/9, 77.8%) were related to SAH or unrelated disease. Morbidity at 1 and 12 months was also partially related to SAH: in 3/8 patients (37.5%) at 1 month and 1/4 patients (25.0%) at 12 months. Aneurysm

treatment with the WEB was associated with a high feasibility (95.3%) with similar results in ruptured aneurysms (94.2%), unruptured-recurrent aneurysms (95.6%) ($P = .71$), and in typical (95.4%) and atypical (94.7%) locations ($P = .70$). In contrast, feasibility was lower in aneurysms with an angle of $\geq 45^\circ$ (90.2%) compared with those with an angle of $< 45^\circ$ (97.1%) ($P = .03$). These data must be carefully interpreted because they relate to indications for aneurysm treatment with the WEB in the 2 centers of these studies (see Limitations). Our findings show that the WEB-17 system permits treatment of atypical and typical locations in the same percentage of cases, whereas some aneurysms with an angle of $\geq 45^\circ$ remain difficult or impossible to treat.

Among the 11 WEB-treated failures reported in this series, in 8 procedures, 2 different WEB devices were deployed but did not adequately close the neck; especially in 2 procedures, the WEB SL 6×3 mm and WEB SL 5×2 were too large or too small, while the unavailable WEB SL 6×2 mm would have been useful. These 2 situations showed that at the moment, in some aneurysms with limited height, treatment with the WEB device is not a good option. Anyway, as WEB indication for aneurysm treatment progressively increasing, our results could suggest the existence of limitation of WEB sizing, especially for height dimension and that shallow WEB device is a really necessity in the current clinical scenario.

In this series, adjunctive implants (stent, FD, or coils), with or without balloon inflation, were used in 19/222 (8.6%) aneurysm treatments. This rate is in line with the WEBCAST (8.3%) and the French Observatory (11.3%) studies but higher compared with WEBCAST 2 (1.9%).

The rate of procedural and postprocedural complications was 16.9%; however, a permanent deficit was observed in only 6/212 (2.8%) patients, and 2 of these 6 patients had non-neurologic complications.

The percentage of thromboembolic complications was lower (7.1%) compared with what has been reported in the European Good Clinical Practice series (14.4%) or WEB-IT (10.0%). Several factors may explain this difference: 1) The European and US series were conducted at the beginning of clinical experience with the WEB; 2) the patients included in this series were treated with the most recent WEB generation, while the patients in the European Good Clinical Practice studies were treated with the first WEB generation (WEB-DL) and second generation (WEB-SL and SLS); 3) antiplatelet protocols have evolved, and not all patients were premedicated with dual-antiplatelet treatment in the European and US series; 4) the microcatheter used in this series has the smallest size (VIA-17) compared with microcatheters used in the European and US series (including VIA-33, VIA-27, and VIA-21); and 5) most aneurysms included in this series were small.

Other recent retrospectives series showing the results of aneurysm treatment with the WEB-17 device reported a rate of thromboembolic complications similar to ours: in van Rooij et al,²² 5.0%; in Pagano et al,²⁵ 5.5%; in Maurer et al,²³ 4.2%; in König et al,²⁶ 5.7%; in Mihalea et al,²⁴ 4.0%; in Goertz et al,²⁷ 5.3%; and in Zimmer et al,¹⁴ 6.4%.

In contrast to thromboembolic complications, the rate of procedural hemorrhagic complications was similar in this series (1.4%), the European series (1.2%), and WEB-IT (1.3%). Since beginning of clinical practice with WEB, it has been clearly shown that the rate of intraoperative rupture is very low. In the present series, only 1 patient died (50 days after the procedure) due to an intraprocedural rupture, related to balloon use and not to the WEB device.

The rate of delayed complications was not low (7.5%). None were hemorrhagic, and a few were infectious (2/16 patients). Most delayed complications were likely ischemic or hemodynamic, were treated with antiplatelet medication, and had good clinical outcome.

Anatomic results in this series were slightly better compared with previous series. The rate of complete aneurysm occlusion at 12 months was 67.5% compared with 52.9% in the European studies and 53.8% in WEB-IT. However, the rate of adequate occlusion was only slightly superior in the present series (86.3%) compared with European studies (79.1%) and WEB-IT (84.6%). These results are probably explained by the factors noted above regarding thromboembolic complications.

In this series, feasibility was similar in ruptured aneurysms (94.2%) and unruptured-recurrent aneurysms (95.6%) ($P = .71$). The complication rate was also similar in both groups (20.0% in ruptured and 16.0% in unruptured-recurrent aneurysm) ($P = .52$). Of note, the rate of intraprocedural thromboembolic complications was significantly higher in ruptured (18.0%) than in

unruptured aneurysms (3.7%) ($P = .001$). Moreover, due to SAHs in all cases, mortality at 1 month was significantly higher in ruptured aneurysms (8.0%) compared with unruptured-recurrent (0.0%) ($P = .003$) aneurysms. Morbidity was also higher in the ruptured group (10.0%) compared with the unruptured-recurrent group (1.9%) ($P = .02$). Finally, anatomic results were not significantly different, but adequate occlusion was more frequent in unruptured-recurrent aneurysms (88.5%) compared with ruptured aneurysms (77.5%) ($P = .05$).

In the CLARYS study,²¹ 12-month anatomic results were slightly different compared with the present series, with a lower rate of complete aneurysm occlusion (41.3%) and higher rates of neck (45.7%) and aneurysm (13.0%) remnants. However, the rate of adequate occlusion was higher (87.0%). Because all aneurysms were treated with the WEB-21 system in the CLARYS study, it is likely that the characteristics of the WEB-17 system (smaller system profile, half sizes, shallow devices) were responsible for the higher rate of complete aneurysm occlusion.

The rate of aneurysm retreatment at 12 months was globally low (4/197, 2.0%). The rate of retreatment was statistically not different between the unruptured-recurrent (2/157, 1.3%) and the ruptured (2/40, 5.0%) ($P = .18$) groups.

Limitations

This study has several limitations. First, our results are based on a retrospective analysis. This limitation is partially mitigated by all patients treated with WEB-17 being prospectively included in the database from 2 neurovascular centers. Second, the feasibility of WEB-17 aneurysm treatment was evaluated on the basis of the initial indication for WEB aneurysm treatment by the teams. Some aneurysms were likely not treated with the WEB on the basis of the team's decisions due to anticipated treatment complexity. These decisions could potentially have biased some results regarding feasibility.

CONCLUSIONS

The most recent generation of the WEB device (WEB-17 system) is associated with high feasibility of the treatment (95.3%), high safety (with 1-month morbidity and mortality 3.8% and 1.9%, respectively), and good efficacy (12-month adequate occlusion in 86.3%). Moreover, our findings indicate similar feasibility in unruptured-recurrent (95.6%) and ruptured (94.2%) aneurysms and in typical (95.4%) and atypical locations (94.7%); however, feasibility is slightly lower in aneurysms with an angle of $\geq 45^\circ$ (90.2%) compared with aneurysms with an angle of $< 45^\circ$ (97.1%). Ruptured aneurysms are associated with higher morbidity and mortality rates (4.0% and 14.3%, respectively), mostly due to the consequences of SAH. Finally, 12-month adequate occlusion was more frequent in the unruptured-recurrent group (88.5%) compared with the ruptured group (77.5%).

Disclosure forms provided by the authors are available with the full text and PDF of this article at www.ajnr.org

REFERENCES

1. Goyal N, Hoit D, Dinitto J, et al. **How to WEB: a practical review of methodology for the use of the Woven EndoBridge.** *J Neurointerv Surg* 2020;12:512–20 [CrossRef Medline](#)

2. Pierot L, Szikora I, Barreau X, et al. Aneurysm treatment with the Woven EndoBridge (WEB) device in the combined population of two prospective, multicenter series: 5-year follow-up. *J Neurointerv Surg* 2022; July 8 [Epub ahead of print] [CrossRef Medline](#)
3. Pierot L, Costalat V, Moret J, et al. Safety and efficacy of aneurysm treatment with WEB: results of the WEBCAST study. *J Neurosurg* 2016;124:1250–56 [CrossRef Medline](#)
4. Papagiannaki C, Spelle L, Januel AC, et al. WEB intrasaccular flow disruptor-Prospective, multicenter experience in 83 patients with 85 aneurysms. *AJNR Am J Neuroradiol* 2014;35:2106–11 [CrossRef Medline](#)
5. Pierot L, Gubucz I, Buhk JH, et al. Safety and efficacy of aneurysm treatment with the WEB: results of the WEBCAST 2 study. *AJNR Am J Neuroradiol* 2017;38:1151–55 [CrossRef Medline](#)
6. Pierot XL, Moret J, Turjman F, et al. WEB French observatory. *AJNR Am J Neuroradiol* 2016;37:655–59 [CrossRef Medline](#)
7. Pierot L, Moret J, Barreau X, et al. Safety and efficacy of aneurysm treatment with WEB in the cumulative population of three prospective, multicenter series. *J Neurointerv Surg* 2018;10:556–62 [CrossRef Medline](#)
8. Pierot L, Szikora I, Barreau X, et al. Aneurysm treatment with WEB in the cumulative population of two prospective, multicenter series: 3-year follow-up. *J Neurointerv Surg* 2021;13:363–68 [CrossRef Medline](#)
9. Fiorella D, Molyneux A, Coon A, et al. Demographic, procedural and 30-day safety results from the WEB Intra-saccular Therapy Study (WEB-IT). *J Neurointerv Surg* 2017;9:1191–96 [CrossRef Medline](#)
10. Arthur AS, Molyneux A, Coon AL, et al. The safety and effectiveness of the Woven EndoBridge (WEB) system for the treatment of wide-necked bifurcation aneurysms: final 12-month results of the pivotal WEB Intrasaccular Therapy (WEB-IT) study. *J Neurointerv Surg* 2019;11:924–30 [CrossRef Medline](#)
11. Pierot L, Biondi A, Narata AP, et al. Should indications for WEB aneurysm treatment be enlarged? Report of a series of 20 patients with aneurysms in “atypical” locations for WEB treatment. *J Neuroradiol* 2017;44:203–09 [CrossRef Medline](#)
12. Aguiar G, Caroff J, Mihalea C, et al. WEB device for treatment of posterior communicating artery aneurysms. *J Neurointerv Surg* 2022;14:362–65 [CrossRef Medline](#)
13. Adeeb N, Dibas M, Diestro JDB, et al. Multicenter study for the treatment of sidewall versus bifurcation intracranial aneurysms with use of Woven EndoBridge (WEB). *Radiology* 2022;304:372–82 [CrossRef Medline](#)
14. Zimmer S, Maus V, Maurer C, et al. Widening the indications for intrasaccular flow disruption: WEB 17 in the treatment of aneurysm locations different from those in the Good Clinical Practice Trials. *AJNR Am J Neuroradiol* 2021;42:524–29 [CrossRef Medline](#)
15. Gawlitza M, Soize S, Januel AC, et al. Treatment of recurrent aneurysms using the Woven EndoBridge (WEB): anatomical and clinical results. *J Neurointerv Surg* 2018;10:629–33 [CrossRef Medline](#)
16. Liebig T, Kabbasch C, Strasilla C, et al. Intrasaccular flow disruption in acutely ruptured aneurysms: a multicenter retrospective review of the use of the WEB. *AJNR Am J Neuroradiol* 2015;36:1721–27 [CrossRef Medline](#)
17. Popielski J, Berlis A, Weber W, et al. Two-center experience in the endovascular treatment of ruptured and unruptured intracranial aneurysms using the WEB device: a retrospective analysis. *AJNR Am J Neuroradiol* 2018;39:111–17 [CrossRef Medline](#)
18. Spelle L, Herbreteau D, Caroff J, et al. CLinical Assessment of WEB device in Ruptured aneurYSms (CLARYS): results of 1-month and 1-year assessment of rebleeding protection and clinical safety in a multicenter study. *J Neurointerv Surg* 2022;14:80714 [CrossRef Medline](#)
19. Al Saiegh F, Hasan D, Mouchtouris N, et al. Treatment of acutely ruptured cerebral aneurysms with the Woven EndoBridge device: experience post-FDA approval. *Neurosurg* 2020;87:E16–22 [CrossRef Medline](#)
20. Youssef PP, Dornbos D, Peterson J, et al. Woven EndoBridge (WEB) device in the treatment of ruptured aneurysms. *J Neurointerv Surg* 2021;13:443–46 [CrossRef Medline](#)
21. Spelle L, Herbreteau D, Caroff J, et al. CLinical Assessment of WEB device in Ruptured aneurYSms (CLARYS): 12-month angiographic results of a multicenter study. *J Neurointerv Surg* 2022 Jul 26 [CrossRef Medline](#)
22. Van Rooij SBT, Peluso JP, Sluzewski M, et al. The new low-profile WEB 17 system for treatment of intracranial aneurysms: first clinical experiences. *AJNR Am J Neuroradiol* 2018;39:859–63 [CrossRef Medline](#)
23. Maurer C, König I, Berlis A, et al. Two-center experience in the endovascular treatment of intracranial aneurysms using the Woven EndoBridge-17 device including midterm follow-up results: a retrospective analysis. *AJNR Am J Neuroradiol* 2019;40:1517–22 [CrossRef Medline](#)
24. Mihalea C, Caroff J, Pagiola I, et al. Safety and efficiency of the fifth generation Woven EndoBridge device: technical note. *J Neurointerv Surg* 2019;11:511–15 [CrossRef Medline](#)
25. Pagano P, Paiusan L, Soize S, et al. Intracranial aneurysm treatment with intrasaccular flow disruption: comparison of WEB-21 and WEB-17 systems. *J Neurointerv Surg* 2022;14:904–09 [CrossRef Medline](#)
26. König I, Maurer C, Berlis A, et al. Treatment of ruptured and unruptured intracranial aneurysms with WEB 17 versus WEB 21 systems: comparison of indications and early angiographic outcomes. *Clin Neuroradiol* 2021;31:691–97 [CrossRef Medline](#)
27. Goertz L, Liebig T, Siebert E, et al. Low-profile intra-aneurysmal flow disruptor WEB 17 versus WEB predecessor systems for treatment of small intracranial aneurysms: comparative analysis of procedural safety and feasibility. *AJNR Am J Neuroradiol* 2019;40:1766–72 [CrossRef Medline](#)