This information is current as of October 11, 2024.

Celebrating 35 Years of the AJNR: May 1988 edition

AJNR Am J Neuroradiol 2023, 44 (5) 623
doi: https://doi.org/10.3174/ajnr.P6848
http://www.ajnr.org/content/44/5/623.citation

Celebrating 35 Years of the AJNR

May 1988 edition

MR Evaluation of Large Intracranial Aneurysms Using Cine Low Flip Angle Gradient-Refocused Imaging

Jay S. Tsuruda[1,2]
Van V. Halbach
Randall T. Higashida
Alexander S. Mark
Grant B. Hieshima
David Norman

MR imaging has proved to be useful in evaluating large intracranial aneurysms. The parent artery and patent lumen can be identified as flow voids and differentiated from thrombus. However, in the presence of slow flow, even-echo rephasing, and motion artifact, increased intraluminal signal may be present, which may be difficult to distinguish from thrombus. Aneurysms are also dynamic lesions and exert pulsatile mass effect on adjacent structures. Further definition of vascular anatomy and physiology may aid in therapeutic planning and assessment. Cine MR is a new technique using a movie loop of sequential GRASS (gradient-recalled acquisition in the steady state) images obtained during various points in the cardiac cycle. The combination of GRASS images and cardiac gating thus allows cinegraphic display of vascular structures. A comparison of this method with routine T1- and T2-weighted MR imaging and angiography was made in a group of 13 patients with intracranial aneurysms greater than 1.5 cm in diameter. Eight of these patients underwent transvascular detachable balloon occlusion. With cine MR, flowing blood has high intensity due to flow-related enhancement. Turbulent and high-velocity flow can be recognized on the basis of signal loss, which occurs during systole. Thrombus demonstrated variable signal intensity, which remained unchanged during the cardiac cycle. Compared with routine MR sequences, there was less image degradation from phase-encoding artifacts and improved visualization of the neck of the aneurysm. Pulsatile mass effect was uniquely assessed. After transvascular embolization, cine MR demonstrated improved conspicuity of acute thrombus and higher contrast between flowing blood and the occlusion balloon when compared with routine MR. Confirmation of flow within the parent vessel, residual aneurysm lumen, and distal arterial branches is possible. If the parent vessel was occluded, cine MR yielded greater information than angiography.

Cine MR provides additional anatomic and physiologic data in the evaluation and assessment of therapy of intracranial aneurysms. Information can be obtained that is not available with either routine MR or angiography. The inherent limitations of this new technique include partial-volume artifacts, less than optimal flow-related enhancement or spatial resolution, and poor data acquisition due to cardiac arrhythmias.

This article appears in the May/June 1988 issue of *AJNR* and the July 1988 issue of *AJR*.

Received September 11, 1987; accepted after revision December 28, 1987.

Presented at the annual meeting of the American Society of Neuroradiology, New York, May 1987.

[1] All authors: Department of Radiology, Diagnostic and Interventional Neuroradiology Section, University of California, San Francisco, 505 Parnassus Ave., San Francisco, CA 94143-0628.

[2] Present address: MR Imaging Laboratory, Huntington Medical Research Institutes, 10 Pico St., Pasadena, CA 91105. Address reprint requests to J. S. Tsuruda.

***AJNR* 9:415–424, May/June 1988**
0195–6108/88/0903–0415
© American Society of Neuroradiology

The evaluation of intracranial aneurysms by MR has been described. MR has several known advantages over both angiography and contrast-enhanced CT. These advantages include identification of signal void within the patent lumen [1–5], laminated thrombus [4], adjacent parenchymal edema and hemorrhage [2, 4], and parent vessel [4], as well as the definition of an extraaxial location with mass effect [5]. For these reasons MR may be more specific in characterizing these lesions [4, 5]. The patent lumen of the aneurysm can be identified on routine MR sequences by high-velocity signal loss (resulting from time-of-flight effects) or by turbulence. However, in the presence of slow flow and/or even-echo rephasing [2, 5], distinguishing flowing blood from thrombus may be difficult. On the other hand, calcium in the aneurysm wall may be confused with flow void. If the residual vascular channel is eccentrically located with associated thrombus, a giant aneurysm may be mistaken for an arteriovenous malformation [3]. Giant aneurysms have a variable incidence of associated subarachnoid hemorrhage and are usually

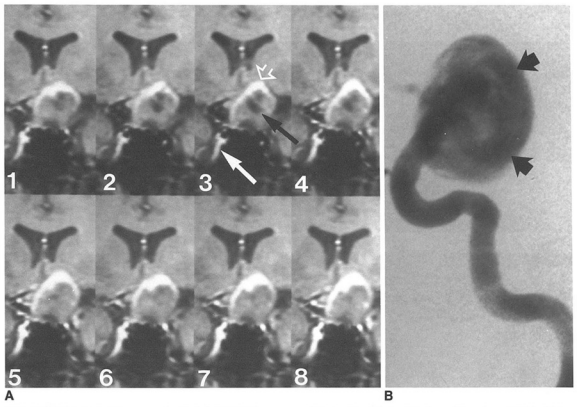

Posterior Pituitary Ectopia: An MR Feature of Pituitary Dwarfism

William M. Kelly[1,2]
Walter Kucharczyk[3]
John Kucharczyk[4]
Bent Kjos
Wallace W. Peck
David Norman
T. H. Newton

Using high-field-strength, 1.5-T, high-resolution MR, we identified the following complex of neurohypophyseal abnormalities in each of five pituitary dwarfs: (1) severe hypoplasia or total absence of the infundibulum; (2) absence of the posterior pituitary bright spot in its normal location; and (3) a 3–8-mm tissue nodule at the median eminence exhibiting lipidlike signal on T1-weighted images. On the basis of its signal features and the clinical absence of diabetes insipidus in these patients, the median eminence nodule appears to represent an ectopic and functional posterior pituitary gland.

We propose that this anatomic derangement is the end result of a localized defect of developmental origin, possibly ischemic in nature, and involving principally the infundibular stem. Thus, human growth hormone deficiency could result from perinatal disruption of the peri-infundibular hypophyseal portal system, which in turn impairs anterior pituitary function through deprivation of direct delivery of crucial hypothalamic-releasing factors. Finally, we suggest that the trophic influence of continued axonal neurosecretion at the median eminence engages proliferation of rest cell pituicytes; a process that induces formation of an ectopic and functional posterior pituitary gland, complete with its characteristic bright spot.

Although the underlying cause of congenital pituitary dwarfism remains unproved, the current consensus of opinion is that a primary hypothalamic lesion probably accounts for this neuroendocrine disorder. An increased incidence of breech delivery and birth asphyxia among newborns who later develop pituitary dwarfism has prompted researchers to invoke an ischemic mechanism of injury that impairs hypothalamic function in the perinatal period [1, 2]. However, pathologic proof of hypoxic damage to the hypothalamus is lacking, and cross-sectional imaging techniques have thus far failed to identify an abnormality of hypothalamic tissue. Furthermore, pituitary dwarfs have not been reported to exhibit an increased incidence of motor deficits or basal ganglia disturbances, which might be expected from injury to bordering nervous tissue that shares a common vascular territory with the hypothalamus.

High-resolution CT is a well-established and widely accepted method of evaluating the parasellar region. However, more recent experience indicates that state-of-the-art MR is currently the imaging technique of choice for investigating patients with suspected pituitary-related endocrine disease [3–5]. Relative to MR, CT provides comparatively poor soft-tissue contrast resolution, and diagnostic results are often hindered by beam-hardening artifacts projected through the sellar contents. Despite these technical limitations, a recent report illustrates convincing CT evidence of both pituitary gland and stalk hypoplasia in pituitary dwarfs [2].

The improved spatial detail provided by high-resolution MR enables more thorough delineation and tissue characterization of bordering structures in and about the sella turcica. These diagnostic advantages provide more consistent and reliable documentation of the recently described pattern of hypoplasia encountered in pituitary dwarfs and disclose additional findings that might help to elucidate the underlying cause of this disorder. The inherently superior contrast provided by MR

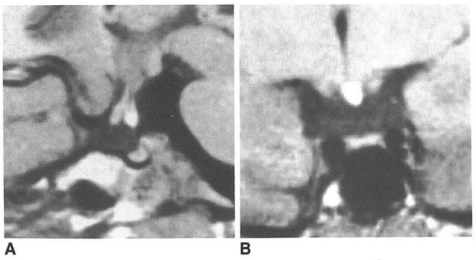

Received August 10, 1987; accepted after revision November 8, 1987.

Presented at the 25th annual meeting of the American Society of Neuroradiology, New York, May 1987.

[1] All authors: Department of Radiology, University of California, San Francisco, 505 Parnassus, San Francisco, CA 94143. Address reprint requests to W. M. Kelly, L371.

[2] Department of Radiology, David Grant USAF Hospital, Travis Air Force Base, CA 94535.

[3] Present address: Department of Radiology, Toronto General Hospital, Toronto, Canada.

[4] Present address: Department of Physiology, University of Ottawa Health Sciences Centre, Ottawa, Canada.

***AJNR* 9:453–460, May/June 1988**
0195–6108/88/0903–0453
© American Society of Neuroradiology