

Are your **MRI contrast agents** cost-effective?

Learn more about generic **Gadolinium-Based Contrast Agents**.



**FRESENIUS  
KABI**

caring for life

**AJNR**

**Improved Myelination following Camp Leg Power, a Selective Motor Control Intervention for Children with Spastic Bilateral Cerebral Palsy: A Diffusion Tensor MRI Study**

This information is current as of May 9, 2024.

A. Vuong, S.H. Joshi, L.A. Staudt, J.H. Matsumoto and E.G. Fowler

*AJNR Am J Neuroradiol* 2023, 44 (6) 700-706

doi: <https://doi.org/10.3174/ajnr.A7860>

<http://www.ajnr.org/content/44/6/700>

# Improved Myelination following Camp Leg Power, a Selective Motor Control Intervention for Children with Spastic Bilateral Cerebral Palsy: A Diffusion Tensor MRI Study

 A. Vuong,  S.H. Joshi,  L.A. Staudt,  J.H. Matsumoto, and  E.G. Fowler



## ABSTRACT

**BACKGROUND AND PURPOSE:** Children with spastic cerebral palsy have motor deficits associated with periventricular leukomalacia indicating WM damage to the corticospinal tracts. We investigated whether practice of skilled lower extremity selective motor control movements would elicit neuroplasticity.

**MATERIALS AND METHODS:** Twelve children with spastic bilateral cerebral palsy and periventricular leukomalacia born preterm (mean age, 11.5 years; age range, 7.3–16.6 years) participated in a lower extremity selective motor control intervention, Camp Leg Power. Activities promoted isolated joint movement including isokinetic knee exercises, ankle-controlled gaming, gait training, and sensorimotor activities (3 hours/day, 15 sessions, 1 month). DWI scans were collected pre- and postintervention. Tract-Based Spatial Statistics was used to analyze changes in fractional anisotropy, radial diffusivity, axial diffusivity, and mean diffusivity.

**RESULTS:** Significantly reduced radial diffusivity ( $P < .05$ ) was found within corticospinal tract ROIs, including 28.4% of the left and 3.6% of the right posterior limb of the internal capsule and 14.1% of the left superior corona radiata. Reduced mean diffusivity was found within the same ROIs (13.3%, 11.6%, and 6.6%, respectively). Additionally, decreased radial diffusivity was observed in the left primary motor cortex. Additional WM tracts had decreased radial diffusivity and mean diffusivity, including the anterior limb of the internal capsule, external capsule, anterior corona radiata, and corpus callosum body and genu.

**CONCLUSIONS:** Myelination of the corticospinal tracts improved following Camp Leg Power. Neighboring WM changes suggest recruitment of additional tracts involved in regulating neuroplasticity of the motor regions. Intensive practice of skilled lower extremity selective motor control movements promotes neuroplasticity in children with spastic bilateral cerebral palsy.

**ABBREVIATIONS:** ACR = anterior corona radiata; AD = axial diffusivity; ALIC = anterior limb of the internal capsule; CC = corpus callosum; CerPed = cerebral peduncle; CP = cerebral palsy; CST = corticospinal tract; EC = external capsule; FA = fractional anisotropy; GMFCS = Gross Motor Function Classification System; GMFM = Gross Motor Function Measure; MD = mean diffusivity; PLIC = posterior limb of the internal capsule; PVL = periventricular leukomalacia; RD = radial diffusivity; SCALE = Selective Control Assessment of the Lower Extremity; SCR = superior corona radiata; SMC = selective motor control; TBSS = Tract-Based Spatial Statistics

Children born prematurely are vulnerable to WM motor tract injury, with the resulting severity of motor impairment dependent on the extent of neuronal damage. The corticospinal

tracts (CSTs) responsible for selective motor control (SMC) are particularly vulnerable to damage due to their anatomic location. Periventricular leukomalacia (PVL), indicating CST damage, is a common MR imaging finding in children with spastic bilateral cerebral palsy (CP).<sup>1</sup> Impaired SMC presents as a lack of isolated joint movement and may include flexor/extensor synergy patterns and mirror movements with reduced force, speed, and timing of movement.<sup>2,3</sup> SMC can be measured clinically using the Selective Control Assessment of the Lower Extremity (SCALE).<sup>2</sup> SCALE scores correlate with intralimb coordination<sup>4</sup> and knee


Received November 4, 2022; accepted after revision April 4, 2023.


From the Departments of Bioengineering (A.V., S.H.J.), Orthopaedic Surgery (A.V., L.A.S., E.G.F.), Neurology (S.H.J.), Ahmanson Lovelace Brain Mapping Center, and Pediatrics (J.H.M.), University of California Los Angeles, Los Angeles, California; and Center for Cerebral Palsy (A.V., L.A.S., E.G.F.), University of California Los Angeles/Orthopaedic Institute for Children, Los Angeles, California.

MR imaging data acquisition and gait assessments were funded by donations and grants from the University of California Los Angeles Children's Discovery and Innovation Institute; Shapiro Family Foundation; United Cerebral Palsy of Los Angeles, Santa Barbara, and Ventura Counties; Waters Foundation; Lena Longo Foundation; and University of California Los Angeles Brain Mapping Center. Additional support was received from the National Center for Advancing Translational Science of the National Institutes of Health under the University of California Los Angeles Clinical and Translational Science Institute grant No. UL1TR001881.

No funders were involved in the preparation of this article. The authors have stated that they had no interests that might be perceived as posing a conflict or bias.

Please address correspondence to Andy Vuong, PhD, Center for Cerebral Palsy at UCLA/OIC, 1000 Veteran Ave, 22-27 Rehabilitation Center, Los Angeles, CA 90095-1795; e-mail: andyvuong@ucla.edu

 Indicates open access to non-subscribers at [www.ajnr.org](http://www.ajnr.org)

 Indicates article with online supplemental data.

<http://dx.doi.org/10.3174/ajnr.A7860>

extension acceleration during gait<sup>5</sup> and have a larger causal effect on gross motor function than strength, spasticity, contractures, and bony deformities.<sup>6</sup> SMC is considered a prognostic factor for surgical outcomes.<sup>7,8</sup>

DTI has been used to assess WM damage in children with spastic CP.<sup>9-12</sup> Relative to normative data, reduced fractional anisotropy (FA) has been interpreted as a marker of disruption of local tissue structural anisotropy; higher radial diffusivity (RD), as decreased myelination; lower axial diffusivity (AD), as axonal injury; and higher mean diffusivity (MD), as greater overall diffusion.<sup>13-18</sup> Lower FA,<sup>9-12</sup> higher RD and MD,<sup>10,12</sup> and bidirectional results for AD<sup>10,12</sup> have been reported for children with spastic bilateral CP compared with children with typical development. In children with spastic bilateral CP, significant correlations between DTI measures and the Gross Motor Function Classification System (GMFCS) levels,<sup>10,11</sup> Gross Motor Function Measure (GMFM),<sup>12</sup> and SCALE scores<sup>12</sup> have been found. SCALE scores were found to correlate positively with FA and negatively with RD in more motor regions of the brain compared with GMFM.<sup>12</sup>

Neuroplasticity as evidenced by changes in the microstructural properties of WM motor tracts in spastic CP is not well-understood. DTI studies examining the response to exercise interventions are limited, and improvements have yet to be clearly demonstrated. Most have focused on upper extremity therapy in children with unilateral CP with contrasting results.<sup>19-21</sup> No significant changes were found in any DTI measure in cohorts of children and young adults with unilateral CP following constraint-induced therapy<sup>19</sup> and constraint-induced therapy preceded by transcranial direct current stimulation.<sup>21</sup> In contrast, Kim et al<sup>20</sup> found increased FA following a task-specific upper extremity exercise intervention in infants with CP, suggesting that microstructural changes may be more likely in younger participants with greater plasticity.

DTI changes of WM motor regions in children with spastic CP in response to a lower extremity exercise intervention have received little attention. Researchers in India examined FA using tractography following 6 months of daily physical therapy (1.5 hours/day for 24 weeks) that was preceded by botulinum toxin injections and casting for children born full-term with bilateral spastic CP (GMFCS levels I-IV).<sup>22</sup> Physical therapy included strengthening, gait training, and stretching. They found significant increases in FA of motor and sensory bundles and GMFM, regardless of botulinum toxin assignment, supporting the efficacy of intensive lower extremity physical therapy. Improved FA, which has not been reported in other studies of lower extremity motor intervention in this population, may be related to the high physical therapy dosage. This dosage is not feasible in most settings and may place a considerable burden on a child and his or her family. Jain et al<sup>23</sup> reported that neither FA nor the apparent diffusion coefficient increased following botulinum toxin injections and 6 months of physical therapy in a cohort of children with spastic bilateral CP. ROIs, however, were defined differently (on the basis of WM perfusion). Most studies of lower extremity interventions in spastic CP to date have not included RD or MD.

While previous CP studies used DTI to observe specific isolated WM motor tracts, full tract reconstruction can be difficult

in cohorts with impaired WM leading to exclusion of participants.<sup>20,24,25</sup> Additionally, focusing on a priori WM tracts may limit the scope of analysis and underestimate the global extent of WM neuroplasticity. Tract-Based Spatial Statistics (TBSS), a whole-brain voxel-based approach, can be used to observe an intervention effect on all WM tracts, including motor regions of the brain,<sup>26</sup> circumventing these issues.

The effect of an intensive lower extremity SMC intervention on WM motor tract microstructure has not been studied in children with spastic bilateral CP born prematurely with PVL. We hypothesized the following: 1) DTI measures would improve following intensive task-specific SMC intervention, and 2) participants with greater baseline SCALE scores would have greater improvement.

## MATERIALS AND METHODS

### Participants

This study was conducted in an outpatient clinical research setting (Center for CP at the University of California Los Angeles/Orthopaedic Institute for Children and Ahmanson-Lovelace Brain Mapping Center). The institutional review board of the University of California Los Angeles provided ethics approval. Informed assent and consent for research were obtained from the children and their parents or guardians.

Inclusion criteria for all participants were the following: 1) between 5 and 18 years of age, 2) history of prematurity, 3) diagnosis of spastic bilateral CP and PVL as evidenced by a brain scan, 4) the ability to understand and follow verbal directions, 5) the ability to lie still, and 6) the ability to walk with or without assistive devices.

Exclusion criteria were the following: 1) metal implants not verified as MR imaging-safe, 2) programmable implants including ventriculoperitoneal shunts and intrathecal baclofen pumps, 3) dental braces, 4) seizures not controlled by medication, 5) orthopedic surgery or neurosurgery within 1 year of starting the study, and 6) botulinum toxin or casting within 3 months of starting the study.

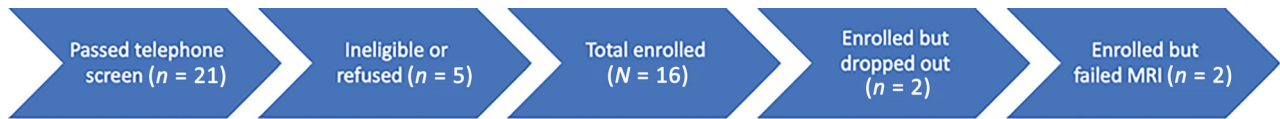The participants in the current study were included in a previous publication examining the correlation between baseline DTI outcomes and SCALE in CP and DTI differences relative to a group of children with typical development.<sup>12</sup>

### Clinical Assessments

Children with CP were evaluated by experienced physical therapists using standardized protocols. SCALE was used to assess SMC.<sup>2</sup> Specific isolated movement patterns at the hip, knee, ankle, and subtalar and toe joints were evaluated bilaterally. SCALE scores for each limb ranged from 0 (absent SMC) to 10 (normal SMC). Left and right limb scores were summed for a total possible SCALE score of 20 points.

### Lower Extremity SMC Intervention

Camp Leg Power, the lower extremity SMC intervention, included practice of skilled, isolated joint movements, isokinetic knee exercises at variable speeds, ankle-controlled video gaming, gait and functional training, and sensory enrichment using a summer camp format. Under the supervision of experienced physical



**FIG 1.** Flowchart detailing the recruitment and screening process leading to the total number of participants included in the study.

therapists, each participant had 15 camp sessions for 3 hours/day during a 1-month period. Skilled, isolated movements of the hip, knee, ankle, and subtalar and toe joints were practiced. By means of a Biodex System 4 Pro Dynamometer (Biodex Medical Systems), isokinetic knee extension and flexion exercises were performed bilaterally for a minimum of 10 sessions. Each participant was trained at speeds up to 300°/s, depending on his or her initial ability to produce torque and was progressed to higher speeds on the basis of ability during each session. Participants operated video games using ankle dorsiflexion and plantar flexion movements on a robotic device<sup>27</sup> for at least 5 minutes per limb for a minimum of 10 sessions. Additionally, gait and functional training in activities that emphasized intra- and interlimb control were practiced. These included kicking, navigating obstacles, stair climbing, and treadmill/overground walking encouraging maximal step length. Barefoot sensory enrichment activities were performed including walking on different surfaces.

### MR Imaging Protocols

Before MR imaging sessions, children viewed a slide presentation describing procedures and practiced lying still while listening to recordings of scanner sounds. All T1WI and DWI scans were acquired using a 32-channel coil on a 3T Magnetom Prisma MR imaging scanner (Siemens) without sedation. T1-weighted MPRAGE images were obtained using TR = 2500 ms; TE = 1.8, 3.6, 5.39, and 7.18 ms; FOV = 256 × 256 mm<sup>2</sup>; and isotropic voxel resolution = 0.8 × 0.8 × 0.8 mm<sup>3</sup>. DWI scans were obtained using a single-shot, spin-echo, echo-planar acquisition with 6 reference images ( $b = 0$  s/mm<sup>2</sup>), 52 gradient directions ( $b = 1500$  s/mm<sup>2</sup>), TR = 3231 ms, TE = 89.6 ms, FOV = 210 × 210 mm<sup>2</sup>, echo spacing = 0.69 ms, and isotropic voxel resolution = 1.5 × 1.5 × 1.5 mm<sup>3</sup>. All DWI scans were corrected for EPI susceptibility and eddy current distortions using FSL's topup tool (<https://fsl.fmrib.ox.ac.uk/fsl/fslwiki/topup/ExampleTopupFollowedByApplytopup>) and eddy tool (<https://fsl.fmrib.ox.ac.uk/fsl/fslwiki/eddy>), respectively, and FA, RD, AD, and MD maps were generated using DTIFit ([http://fsl.fmrib.ox.ac.uk/fsl/fsl-4.1.9/fdt/fdt\\_dtifit.html](http://fsl.fmrib.ox.ac.uk/fsl/fsl-4.1.9/fdt/fdt_dtifit.html)).<sup>28</sup> All DTI maps underwent a nonlinear registration to the standard space. Subsequently, the mean FA image was projected in the standard space FMRIB58\_FA ([https://fsl.fmrib.ox.ac.uk/fsl/fslwiki/FMRIB58\\_FA](https://fsl.fmrib.ox.ac.uk/fsl/fslwiki/FMRIB58_FA)) and thresholded at FA = 0.2 to create a skeletonized version.<sup>26</sup> The nonlinear transformations were applied to the FA, RD, AD, and MD maps and projected on the mean FA skeleton in preparation for statistical analysis.<sup>29</sup>

### Statistical Analysis

TBSS, a whole-brain voxel-based approach, was used to assess pre- and postdifferences in FA, RD, AD, and MD.<sup>26</sup> The mean WM skeleton used was derived from and overlaid on the FMRIB58 standard-space FA template. Statistical analyses were

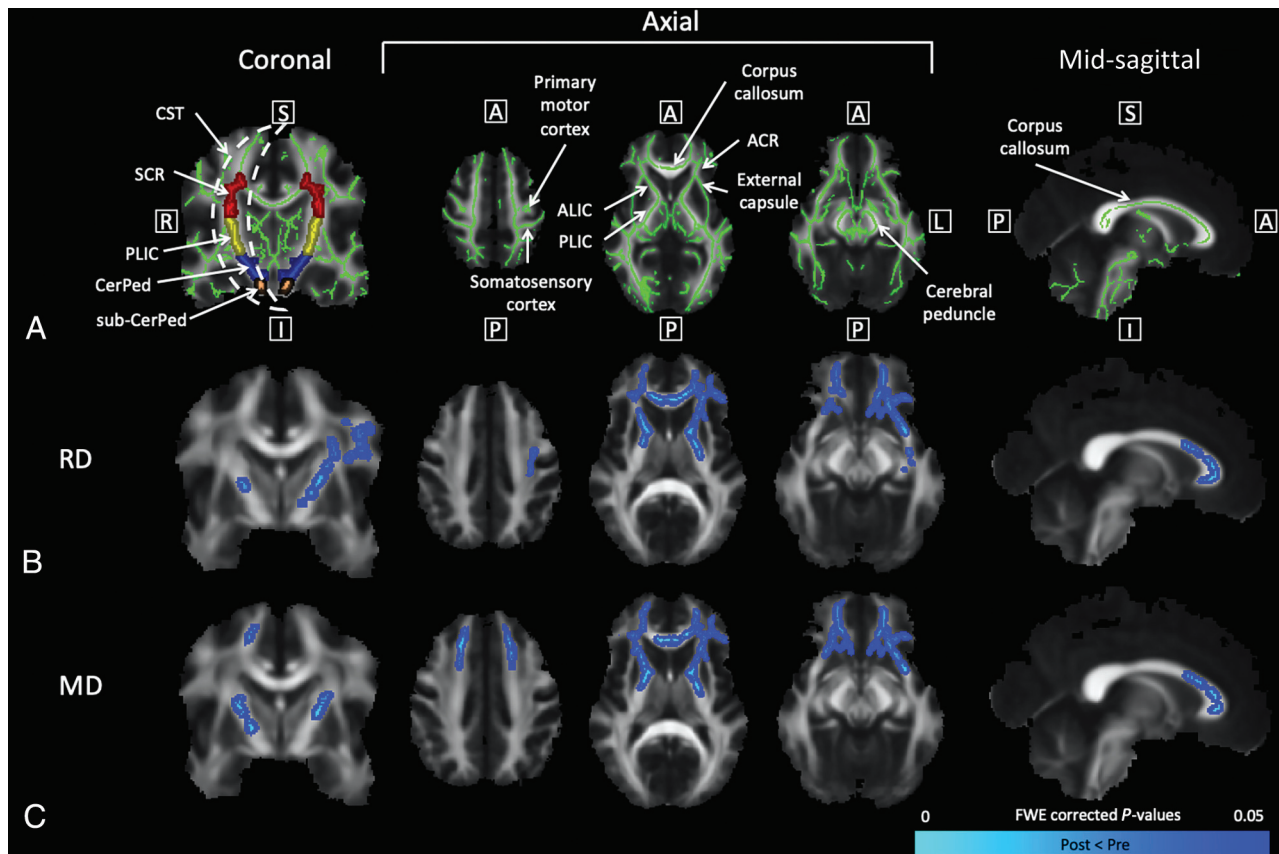
performed using paired *t* tests (5000 permutations). In addition, correlation analyses between pre- and post-DTI differences within each voxel and total SCALE score were performed. All results were corrected for multiple comparisons using the threshold-free cluster enhancement procedure implemented in Randomise (<https://fsl.fmrib.ox.ac.uk/fsl/fslwiki/Randomise/UserGuide>).<sup>30</sup> Voxels with significant findings ( $P < .05$ ) were displayed on the mean WM skeleton.

ROI analyses were performed to quantify voxels with significant postintervention differences ( $P < .05$ ). Using the Johns Hopkins University ICBM-DTI-81 WM atlas labels (<http://neuro.debian.net/pkgs/fsl-jhu-dti-whitematter-atlas.html>),<sup>31</sup> we transferred ROIs to all images produced in the TBSS pipeline after nonlinear warping to the standard Montreal Neurological Institute 152 space and skeletonization. Significant pre- and postdifferences ( $P < .05$ ) within ROIs were quantified by performing voxel counts in FSL (<http://www.fmrib.ox.ac.uk/fsl>). ROIs located along the descending pathways of the CSTs were parcellated bilaterally to analyze WM motor regions: 1) area inferior to the cerebral peduncle (sub-CerPed), 2) cerebral peduncle (CerPed), 3) posterior limb of the internal capsule (PLIC), and 4) superior corona radiata (SCR). Secondary ROIs were the anterior limb of the internal capsule (ALIC), external capsule (EC), anterior corona radiata (ACR), and the corpus callosum (CC) genu and body. The percentages of significant voxels ( $P < .05$ ) in relation to the total number of voxels within ROIs were calculated.

### RESULTS

Twelve children with spastic bilateral CP (2 females, 10 males; mean age, 11.5 [SD, 2.8] years; age range, 7.3–16.6 years) participated. They were born preterm with a mean gestational age of 28.9 weeks, ranging from 24 to 33 weeks. Using baseline T2WI scans, a neurologist or neuroradiologist examined CST brain regions between the cortex and medulla. All demonstrated findings consistent with clinical findings of spastic bilateral CP, namely PVL and/or ventricular enlargement, particularly in the posterior horns of the lateral ventricles. GMFCS levels were the following: I ( $n = 3$ ), II ( $n = 1$ ), III ( $n = 7$ ), and IV ( $n = 1$ ). Total SCALE scores ranged from 1 to 18. Five participants were right-handed, and 7 participants were left-handed. Figure 1 details the recruitment and screening process leading to the total number of participants included in the study.

The mean WM skeleton used is shown in Fig 2A. Significant postintervention decreases in RD ( $P < .05$ ) were found throughout major WM tracts, including the CSTs, ALIC, EC, ACR, and CC (Fig 2B). Within the CSTs, RD decreased in the bilateral PLIC and left SCR as seen on the coronal and axial views. In the



**FIG 2.** TBSS results show significant reductions in RD and MD ( $P < .05$ ) after lower extremity SMC intervention. Coronal slices were selected at the level of the CSTs. From left to right, axial slices were selected at the level of the primary motor cortex, PLIC, and CerPed, respectively. Mid-sagittal slices were selected at the level of the CC. A, The WM skeleton is shown in green with additional arrows labeling the somatosensory cortex, ALIC, ACR, and EC. In the coronal view, ROIs for the SCR (red), PLIC (yellow), CerPed (blue), and sub-CerPed (orange) are shown. Significant pre- and postdifferences for the CP group ( $P < .05$ ) are shown for RD (B) and MD (C). The colormap (blue-light blue) denotes a significant decrease in the DTI measure ( $P < .05$ ). A indicates anterior; FWE, family-wise error; I, inferior; L, left; P, posterior; R, right; S, superior.

superior axial section, decreased RD can be viewed in the left motor and somatosensory cortices. Significant decreases in MD ( $P < .05$ ) were found in similar regions of the brain (Fig 2C): the CSTs (bilateral PLIC and left SCR), ALIC, EC, ACR, and CC. In addition, decreased MD was apparent in both frontal lobes. No significant increases in RD or MD ( $P < .05$ ) were found, and no significant changes in FA or AD ( $P < .05$ ) were found in either direction. Significant correlations ( $P < .05$ ) were not found between changes in DTI measures and total SCALE scores.

The number of voxels with significant decreases in RD and MD ( $P < .05$ ) within motor and nonmotor WM ROIs is shown in the Table. RD and MD decreased within ROIs for the bilateral ALIC, bilateral PLIC, bilateral EC, bilateral ACR, left SCR, and CC genu and body. In all bilateral ROIs presented, a greater percentage change was seen in the left hemisphere of the brain compared with the right for both RD and MD, with the exception of MD in the bilateral ALIC. Additional ROIs containing voxels with significant decreases in RD ( $P < .05$ ) are shown in the Online Supplemental Data.

## DISCUSSION

This study showed significantly decreased RD and MD ( $P < .05$ ) in the WM motor regions after an intensive lower extremity SMC

intervention in children with spastic bilateral CP. No significant postintervention increases in RD or MD ( $P < .05$ ) were found. Few studies of children with spastic CP have analyzed postintervention DTI changes beyond FA. Following the intervention, RD and MD decreased in key CST regions, including the bilateral PLIC, left SCR, and left primary motor cortex. While decreased RD of the WM tracts is indicative of improved myelination,<sup>16,18</sup> the meaning of decreased MD is less clear.<sup>17,32</sup> We suggest, however, that the decreased MD is driven by intervention-guided neuroplastic changes related to altered uniformity in microstructural tissue complexity.<sup>17,32-34</sup> In children with typical development, myelination is rapidly developed during infancy<sup>35</sup> and is dynamically regulated throughout adolescence,<sup>36</sup> but deficits have been widely reported for children with spastic CP and PVL.<sup>12,37-39</sup> It has been theorized that task-based interventions focused on practicing new complex motor skills, as performed in this study, promote myelination.<sup>40-43</sup> Others have reported improved CST myelination (using DTI tract-based quantitative susceptibility mapping) in children with spastic CP following cord blood stem cell therapy and usual rehabilitation therapy,<sup>44-46</sup> precluding direct comparisons.

Our current findings of improved myelination of the CC genu and body are consistent with potential neuroplastic

**Voxel counts of WM ROIs<sup>a</sup>**

ROI	Voxel Count	Voxels with Significant Pre- and Post-Decreases	
		RD (%)	MD (%)
R ALIC	792	278 (35.1)	400 (50.5)
L ALIC	819	341 (41.6)	205 (25.0)
R PLIC	845	30 (3.6)	98 (11.6)
L PLIC	858	244 (28.4)	114 (13.3)
R EC	1331	19 (1.4)	41 (3.1)
L EC	1431	320 (22.4)	164 (11.5)
R ACR	1619	365 (22.5)	569 (35.1)
L ACR	1613	897 (55.6)	802 (49.7)
L SCR	1279	180 (14.1)	84 (6.6)
Body of CC	1758	914 (52.0)	710 (40.4)
Body of CC	3138	201 (6.4)	256 (8.2)

**Note:**— R indicates right; L, left.

<sup>a</sup>Significance set at ( $P < .05$ ).

changes in response to SMC-focused therapy activities. In a study of rats trained in a spatial learning and memory task, WM changes in the CC as evidenced by DTI changes in FA and apparent diffusion coefficient were accompanied by increased myelin basic protein expression.<sup>47</sup> These findings support the association between acquisition of new complex motor skills and increased CC myelination. The CC is an important WM structure that is believed to play a role in bilateral coordination,<sup>48</sup> especially inhibition of physiologic mirroring that normally diminishes with age during early childhood.<sup>49</sup> Loss of transcallosal inhibition is one proposed cause of acquired obligatory mirror movements in patients with upper motor neuron lesions.<sup>50-52</sup> These abnormal mirror movements in CP contribute to SMC deficits and lower SCALE scores.<sup>2</sup> Lower FA in transcallosal fibers in the CC body has been associated with upper extremity mirroring in children with spastic CP and PVL.<sup>53</sup> We previously demonstrated a correlation between SCALE scores and DTI indices in the CC in a cross-sectional analysis of this cohort.<sup>12</sup>

Significant postintervention decreases in RD and MD ( $P < .05$ ) in other WM regions, including the ALIC, ACR, EC, sensorimotor cortex, and frontal lobes suggest recruitment of neighboring WM tracts directly adjacent or within close proximity to the CSTs. Prior studies of adults recovering from stroke have demonstrated significant changes in functional connectivity among the primary motor cortices,<sup>54,55</sup> as well as postintervention (repetitive transcranial magnetic stimulation and occupational therapy) changes in similar WM regions.<sup>56</sup> Although motor improvement in children with spastic CP is made more complex by ongoing processes in the developing brain, similar patterns and principles of neuroplasticity likely apply. These neighboring WM regions with reduced RD and MD are areas of the brain that contain rich interconnections among the cortex, thalamus, and association regions.<sup>57-61</sup> Therefore, it is plausible that coactivation and improved myelination of these additional WM tracts are necessary in regulating neuroplasticity of the brain motor regions.

Lower extremity interventions aimed specifically at developing and improving SMC in CP are limited and have primarily focused on the ankle joint.<sup>27,62</sup> DTI changes following more generalized lower extremity rehabilitation have focused on FA. Two

studies with botulinum toxin and 6 months of general lower extremity exercise in children with CP reported increased FA in the PLIC of the CSTs<sup>63</sup> and in motor fiber bundles,<sup>22</sup> regions where we found decreased RD and MD. Additionally, increased FA was found in 2 motor tracts (CSTs and PLIC) and 5 association tracts (CC, inferior and superior longitudinal fasciculus, uncinata, and cingulum) following intensive voice treatment (14 weeks) in children with CP and secondary dysarthria.<sup>64</sup> While the DTI measures analyzed did not include RD, these studies support the ideas in the present study that recruitment and activation of the CSTs play a critical role in responsiveness to intensive lower extremity intervention and practicing new complex motor skills. It is possible that improved myelination preceded or accompanied improvements in FA in these previous studies, but RD was not assessed. A longer intervention duration and a younger CP cohort may be required to promote improvements in FA.

Significant postintervention decreases in RD and MD ( $P < .05$ ) were not associated with SCALE scores in this analysis, despite the significant correlation between RD and SCALE at baseline.<sup>12</sup> Isolated, skilled movements require good CST function; therefore, we hypothesized that children with higher SCALE scores would have greater capacity to learn and perform skilled movements, resulting in greater myelination. One explanation may be that children with lower SCALE scores are more likely to move in synergistic patterns, have lower levels of physical activity, and experience ankle and foot constraints due to greater dependence on orthotics. Therefore, the Camp Leg Power intervention was more novel for these participants, and greater motor learning may have occurred than was expected.

This study was limited by a relatively small sample size due to MR imaging exclusion criteria. Children with spastic CP commonly have shunts, baclofen pumps, and orthopedic surgery requiring metal implants.<sup>65</sup> In addition, involuntary movements are common and sometimes exaggerated by noise, further limiting a good MR imaging acquisition. The inclusion of a control group of children with spastic bilateral CP who did not undergo the Camp Leg Power intervention would strengthen these findings. Trivedi et al<sup>63</sup> included a control group of children with typical development and did not find significant within-group differences in FA or MD over a much longer time period. A randomized, controlled trial with a larger cohort would confirm our results. An additional limitation was that ROI analyses of the CSTs at the level of the primary motor cortex were not performed because this region is not included in the Johns Hopkins University WM atlas labels. Younger children with greater potential for plasticity<sup>66</sup> may be more likely to show improvement but are more difficult to scan without sedation. Efforts are currently underway to adapt SCALE and develop a lower extremity SMC intervention for infants and toddlers.

## CONCLUSIONS

Intensive practice of skilled lower extremity SMC movements by children with spastic bilateral CP and PVL born prematurely was associated with increased myelination of WM motor tracts, including the CSTs and CC. Improved myelination of neighboring WM tracts suggests additional neuroplasticity associated with

skilled lower extremity SMC learning. A longer intervention duration at earlier ages may optimize WM neuroplasticity.

## ACKNOWLEDGMENTS

We would like to thank the children and their families for participating in this study.

Disclosure forms provided by the authors are available with the full text and PDF of this article at [www.ajnr.org](http://www.ajnr.org).

## REFERENCES

1. Bax M, Tydeman C, Flodmark O. **Clinical and MRI correlates of cerebral palsy: the European Cerebral Palsy Study.** *J Am Med Assoc* 2006;296:1602–08 [CrossRef Medline](#)
2. Fowler EG, Staudt LA, Greenberg MB, et al. **Selective Control Assessment of the Lower Extremity (SCALE): development, validation, and interrater reliability of a clinical tool for patients with cerebral palsy.** *Dev Med Child Neurol* 2009;51:607–14 [CrossRef Medline](#)
3. Kennedy PR. **Corticospinal, rubrospinal and rubro-olivary projections: a unifying hypothesis.** *Trends Neurosci* 1990;13:474–79 [CrossRef Medline](#)
4. Fowler EG, Goldberg EJ. **The effect of lower extremity selective voluntary motor control on interjoint coordination during gait in children with spastic diplegic cerebral palsy.** *Gait Posture* 2009;29:102–07 [CrossRef Medline](#)
5. Goldberg EJ, Requejo PS, Fowler EG. **Joint moment contributions to swing knee extension acceleration during gait in individuals with spastic diplegic cerebral palsy.** *Gait Posture* 2011;33:66–70 [CrossRef Medline](#)
6. MacWilliams BA, Prasad S, Shuckra AL, et al. **Causal factors affecting gross motor function in children diagnosed with cerebral palsy.** *PLoS One* 2022;17:e0270121 [CrossRef Medline](#)
7. Goldberg EJ, Fowler EG, Oppenheim WL. **Case reports: the influence of selective voluntary motor control on gait after hamstring lengthening surgery.** *Clin Orthop Relat Res* 2012;470:1320–26 [CrossRef Medline](#)
8. Staudt LA, Peacock WJ. **Selective posterior rhizotomy for treatment of spastic cerebral palsy.** *Pediatric Physical Therapy* 1989;1:3–9 [CrossRef](#)
9. Ceschin R, Lee VK, Schmithorst V, et al. **Regional vulnerability of longitudinal cortical association connectivity: associated with structural network topology alterations in preterm children with cerebral palsy.** *Neuroimage Clin* 2015;9:322–37 [CrossRef Medline](#)
10. Arrigoni F, Peruzzo D, Gagliardi C, et al. **Whole-brain DTI assessment of white matter damage in children with bilateral cerebral palsy: evidence of involvement beyond the primary target of the anoxic insult.** *AJNR Am J Neuroradiol* 2016;37:1347–53 [CrossRef Medline](#)
11. Lee JD, Park HJ, Park ES, et al. **Motor pathway injury in patients with periventricular leukomalacia and spastic diplegia.** *Brain* 2011;134:1199–210 [CrossRef Medline](#)
12. Vuong A, Fowler EG, Matsumoto J, et al. **Selective motor control is a clinical correlate of brain motor tract impairment in children with spastic bilateral cerebral palsy.** *AJNR Am J Neuroradiol* 2021;42:2054–61 [CrossRef Medline](#)
13. Basser PJ, Jones DK. **Diffusion-tensor MRI: theory, experimental design and data analysis: a technical review.** *NMR Biomed* 2002;15:456–67 [CrossRef Medline](#)
14. Assaf Y, Pasternak O. **Diffusion tensor imaging (DTI)-based white matter mapping in brain research: a review.** *J Mol Neurosci* 2008;34:51–61 [CrossRef Medline](#)
15. Winkiewski PJ, Sabisz A, Naumczyk P, et al. **Understanding the physiopathology behind axial and radial diffusivity changes: what do we know?** *Front Neurol* 2018;9:92 [CrossRef Medline](#)
16. Song SK, Sun SW, Ramsbottom MJ, et al. **Dysmyelination revealed through MRI as increased radial (but unchanged axial) diffusion of water.** *Neuroimage* 2002;17:1429–36 [CrossRef Medline](#)
17. Vos SB, Jones DK, Jeurissen B, et al. **The influence of complex white matter architecture on the mean diffusivity in diffusion tensor MRI of the human brain.** *Neuroimage* 2012;59:2208–16 [CrossRef Medline](#)
18. Lazari A, Lipp I. **Can MRI measure myelin? Systematic review, qualitative assessment, and meta-analysis of studies validating microstructural imaging with myelin histology.** *Neuroimage* 2021;230:117744 [CrossRef Medline](#)
19. Rickards T, Sterling C, Taub E, et al. **Diffusion tensor imaging study of the response to constraint-induced movement therapy of children with hemiparetic cerebral palsy and adults with chronic stroke.** *Arch Phys Med Rehabil* 2014;95:506–14.e1 [CrossRef Medline](#)
20. Kim JH, Kwon YM, Son SM. **Motor function outcomes of pediatric patients with hemiplegic cerebral palsy after rehabilitation treatment: a diffusion tensor imaging study.** *Neural Regen Res* 2015;10:624–30 [CrossRef Medline](#)
21. Nemanich ST, Mueller BA, Gillick BT. **Neurite orientation dispersion and density imaging quantifies corticospinal tract microstructural organization in children with unilateral cerebral palsy.** *Hum Brain Mapp* 2019;40:4888–900 [CrossRef Medline](#)
22. Chaturvedi SK, Rai Y, Chourasia A, et al. **Comparative assessment of therapeutic response to physiotherapy with or without botulinum toxin injection using diffusion tensor tractography and clinical scores in term diplegic cerebral palsy children.** *Brain Dev* 2013;35:647–53 [CrossRef Medline](#)
23. Jain KK, Paliwal VK, Yadav A, et al. **Cerebral blood flow and DTI metrics changes in children with cerebral palsy following therapy.** *J Pediatr Neuroradiol* 2015;03:63–73 [CrossRef](#)
24. Hodge J, Goodyear B, Carlson H, et al. **Segmental diffusion properties of the corticospinal tract and motor outcome in hemiparetic children with perinatal stroke.** *J Child Neurol* 2017;32:550–59 [CrossRef Medline](#)
25. Kwon JY, Chang W, Chang HJ, et al. **Changes in diffusion tensor tractographic findings associated with constraint-induced movement therapy in young children with cerebral palsy.** *Clin Neurophysiol* 2014;125:2397–403 [CrossRef Medline](#)
26. Smith SM, Jenkinson M, Johansen-Berg H, et al. **Tract-Based Spatial Statistics: voxelwise analysis of multi-subject diffusion data.** *Neuroimage* 2006;31:1487–505 [CrossRef Medline](#)
27. Wu YN, Hwang M, Ren Y, et al. **Combined passive stretching and active movement rehabilitation of lower-limb impairments in children with cerebral palsy using a portable robot.** *Neurorehabil Neural Repair* 2011;25:378–85 [CrossRef Medline](#)
28. Basser PJ, Mattiello J, LeBihan D. **Estimation of the effective self-diffusion tensor from the NMR spin echo.** *J Magn Reson B* 1994;103:247–54 [CrossRef Medline](#)
29. Andersson JL, Sotiropoulos SN. **An integrated approach to correction for off-resonance effects and subject movement in diffusion MR imaging.** *Neuroimage* 2016;125:1063–78 [CrossRef Medline](#)
30. Smith SM, Nichols TE. **Threshold-free cluster enhancement: addressing problems of smoothing, threshold dependence and localisation in cluster inference.** *Neuroimage* 2009;44:83–98 [CrossRef Medline](#)
31. Mori S, Oishi K, Jiang H, et al. **Stereotaxic white matter atlas based on diffusion tensor imaging in an ICBM template.** *Neuroimage* 2008;40:570–82 [CrossRef Medline](#)
32. Thomas B, Eyssen M, Peeters R, et al. **Quantitative diffusion tensor imaging in cerebral palsy due to periventricular white matter injury.** *Brain* 2005;128:2562–77 [CrossRef Medline](#)
33. Scheck SM, Pannek K, Raffelt DA, et al. **Structural connectivity of the anterior cingulate in children with unilateral cerebral palsy due to white matter lesions.** *Neuroimage Clin* 2015;9:498–505 [CrossRef Medline](#)
34. Scheck SM, Boyd RN, Rose SE. **New insights into the pathology of white matter tracts in cerebral palsy from diffusion magnetic resonance imaging: a systematic review.** *Dev Med Child Neurol* 2012;54:684–96 [CrossRef Medline](#)

35. Poduslo SE, Jang Y. **Myelin development in infant brain.** *Neurochem Res* 1984;9:1615–26 [CrossRef Medline](#)
36. Corrigan NM, Yarnykh VL, Hippe DS, et al. **Myelin development in cerebral gray and white matter during adolescence and late childhood.** *Neuroimage* 2021;227:117678 [CrossRef Medline](#)
37. Billiards SS, Haynes RL, Folkerth RD, et al. **Myelin abnormalities without oligodendrocyte loss in periventricular leukomalacia.** *Brain Pathol* 2008;18:153–63 [CrossRef Medline](#)
38. Kinney HC. **Human myelination and perinatal white matter disorders.** *J Neurol Sci* 2005;228:190–92 [CrossRef Medline](#)
39. Volpe JJ. **Brain injury in premature infants: a complex amalgam of destructive and developmental disturbances.** *Lancet Neurol* 2009;8:110–24 [CrossRef Medline](#)
40. Bloom MS, Orthmann-Murphy J, Grinspan JB. **Motor learning and physical exercise in adaptive myelination and remyelination.** *ASN Neuro* 2022;14:175909142210975 [CrossRef Medline](#)
41. Baraban M, Mensch S, Lyons DA. **Adaptive myelination from fish to man.** *Brain Res* 2016;1641:149–61 [CrossRef Medline](#)
42. de Faria O Jr, Gonsalvez DG, Nicholson M, et al. **Activity-dependent central nervous system myelination throughout life.** *J Neurochem* 2019;148:447–61 [CrossRef Medline](#)
43. Lakhani B, Borich MR, Jackson JN, et al. **Motor skill acquisition promotes human brain myelin plasticity.** *Neural Plast* 2016;2016:7526135 [CrossRef Medline](#)
44. Englander ZA, Sun J, Case L, et al. **Brain structural connectivity increases concurrent with functional improvement: evidence from diffusion tensor MRI in children with cerebral palsy during therapy.** *Neuroimage Clin* 2015;7:315–24 [CrossRef Medline](#)
45. Sun JM, Song AW, Case LE, et al. **Effect of autologous cord blood infusion on motor function and brain connectivity in young children with cerebral palsy: a randomized, placebo-controlled trial.** *Stem Cells Transl Med* 2017;6:2071–78 [CrossRef Medline](#)
46. Zhang L, Ellor S, Sun JM, et al. **DTI tract-based quantitative susceptibility mapping: an initial feasibility study to investigate the potential role of myelination in brain connectivity change in cerebral palsy patients during autologous cord blood cell therapy using a rotationally-invariant quantitative measure.** *J Magn Reson Imaging* 2021;53:251–58 [CrossRef Medline](#)
47. Blumenfeld-Katzir T, Pasternak O, Dagan M, et al. **Diffusion MRI of structural brain plasticity induced by a learning and memory task.** *PLoS One* 2011;6:e20678 [CrossRef Medline](#)
48. Wahl M, Lauterbach-Soon B, Hattingen E, et al. **Human motor corpus callosum: topography, somatotopy, and link between microstructure and function.** *J Neurosci* 2007;27:12132–38 [CrossRef Medline](#)
49. Mayston MJ, Harrison LM, Stephens JA. **A neurophysiological study of mirror movements in adults and children.** *Ann Neurol* 1999;45:583–94 [CrossRef Medline](#)
50. Beaulé V, Tremblay S, Théoret H. **Interhemispheric control of unilateral movement.** *Neural Plast* 2012;2012:627816 [CrossRef Medline](#)
51. Riddell M, Kuo HC, Zewdie E, et al. **Mirror movements in children with unilateral cerebral palsy due to perinatal stroke: clinical correlates of plasticity reorganization.** *Dev Med Child Neurol* 2019;61:943–49 [CrossRef Medline](#)
52. Nass R. **Mirror movement asymmetries in congenital hemiparesis: the inhibition hypothesis revisited.** *Neurology* 1985;35:1059–62 [CrossRef Medline](#)
53. Koerte I, Pelavin P, Kirmess B, et al. **Anisotropy of transcallosal motor fibres indicates functional impairment in children with periventricular leukomalacia.** *Dev Med Child Neurol* 2011;53:179–86 [CrossRef Medline](#)
54. Li Y, Wang D, Zhang H, et al. **Changes of brain connectivity in the primary motor cortex after subcortical stroke: a multimodal magnetic resonance imaging study.** *Medicine (Baltimore)* 2016;95:e2579 [CrossRef Medline](#)
55. Liu J, Qin W, Zhang J, et al. **Enhanced interhemispheric functional connectivity compensates for anatomical connection damages in subcortical stroke.** *Stroke* 2015;46:1045–51 [CrossRef Medline](#)
56. Ueda R, Yamada N, Abo M, et al. **White matter changes follow low-frequency repetitive transcranial magnetic stimulation plus intensive occupational therapy for motor paralysis after stroke: a DTI study using TBSS.** *Acta Neurol Belg* 2021;121:387–96 [CrossRef Medline](#)
57. Safadi Z, Grisot G, Jbabdi S, et al. **Functional segmentation of the anterior limb of the internal capsule: linking white matter abnormalities to specific connections.** *J Neurosci* 2018;38:2106–17 [CrossRef Medline](#)
58. Karababa F, Bayazit H, Kılıçaslan N, et al. **Microstructural changes of anterior corona radiata in bipolar depression.** *Psychiatry Investig* 2015;12:367–71 [CrossRef Medline](#)
59. Nolze-Charron G, Dufort-Rouleau R, Houde JC, et al. **Tractography of the external capsule and cognition: a diffusion MRI study of cholinergic fibers.** *Exp Gerontol* 2020;130:110792 [CrossRef Medline](#)
60. Chayer C, Freedman M. **Frontal lobe functions.** *Curr Neurol Neurosci Rep* 2001;1:547–52 [CrossRef Medline](#)
61. Zhao M, Marino M, Samogin J, et al. **Hand, foot and lip representations in primary sensorimotor cortex: a high-density electroencephalography study.** *Sci Rep* 2019;9:19464 [CrossRef Medline](#)
62. Wu YN, Ren Y, Hwang M, et al. **Efficacy of robotic rehabilitation of ankle impairments in children with cerebral palsy.** *Annu Int Conf IEEE Eng Med Biol Soc* 2010;2010:4481–84 [CrossRef Medline](#)
63. Trivedi R, Gupta RK, Shah V, et al. **Treatment-induced plasticity in cerebral palsy: a diffusion tensor imaging study.** *Pediatr Neurol* 2008;39:341–49 [CrossRef Medline](#)
64. Reed A, Cummine J, Bakhtiari R, et al. **Changes in white matter integrity following intensive voice treatment (LSVT LOUD®) in children with cerebral palsy and motor speech disorders.** *Dev Neurosci* 2017;39:460–71 [CrossRef Medline](#)
65. Thompson RM, Fowler EG, Culo B, et al. **MRI safety and imaging artifacts evaluated for a cannulated screw used for guided growth surgery.** *Magn Reson Imaging* 2020;66:219–25 [CrossRef Medline](#)
66. Mundkur N. **Neuroplasticity in children.** *Indian J Pediatr* 2005;72:855–57 [CrossRef Medline](#)