

Generic Contrast Agents

Our portfolio is growing to serve you better. Now you have a *choice*.



[VIEW CATALOG](#)

AJNR

Image Quality Evaluation for Brain Soft Tissue in Neuroendovascular Treatment by Dose-Reduction Mode of Dual-Axis "Butterfly" Scan

Hisayuki Hosoo, Yoshiro Ito, Koji Hirata, Mikito Hayakawa, Aiki Marushima, Tomohiko Masumoto, Hiroshi Yamagami and Yuji Matsumaru







This information is current as of April 24, 2025.

AJNR Am J Neuroradiol 2025, 46 (2) 285-292

doi: <https://doi.org/10.3174/ajnr.A8472>

<http://www.ajnr.org/content/46/2/285>

Image Quality Evaluation for Brain Soft Tissue in Neuroendovascular Treatment by Dose-Reduction Mode of Dual-Axis “Butterfly” Scan

 Hisayuki Hosoo,  Yoshiro Ito, Koji Hirata,  Mikito Hayakawa, Aiki Marushima,  Tomohiko Masumoto,  Hiroshi Yamagami, and  Yuji Matsumaru



ABSTRACT

BACKGROUND AND PURPOSE: Flat panel conebeam CT (CBCT) is essential for detecting hemorrhagic complications during neuroendovascular treatments. Despite its superior image quality and trajectory over conventional CBCT (circular scan), the dual-axis butterfly scan has a slightly higher radiation dose relative to conventional CBCT. This study evaluates the image quality in dose-reduction mode to uncover the appropriate radiation dose for the butterfly scan.

MATERIALS AND METHODS: We prospectively included patients who were scheduled for neuroendovascular treatment and underwent conventional CBCT and the dose-reduction mode of the butterfly scan. Two reduced radiation dose modes were used for the butterfly scan: medium-dose butterfly scan (70% of the original dose, 45 mGy) or low-dose butterfly scan (50% of the original dose, 30 mGy). The enrolled patients were assigned alternately to undergo either the medium- or low-dose butterfly scan. We evaluated and compared artifacts, contrast, and discrimination of the corticomedullary junction between conventional CBCT and one of the dose-reduction modes of the butterfly scan, with a 5-point scale scoring system.

RESULTS: Twenty patients were enrolled in each of the medium- and low-dose groups, totaling 40 patients. Compared with conventional CBCT, the medium-dose butterfly group exhibited reduced artifacts, enhanced contrast, and corticomedullary junction discrimination (except in the occipital lobe). While the low-dose butterfly group exhibited markedly reduced artifacts and improved contrast (except in the occipital lobe), a significant improvement in corticomedullary junction discrimination was not observed.

CONCLUSIONS: Even with dose reduction, the specialized trajectory of the butterfly scan enables artifact reduction, contrast improvement, and enhanced corticomedullary junction discrimination. However, the impact of the reduced dose was more noticeable, particularly in the occipital region where susceptibility to bone interference resulted in decreased contrast and compromised corticomedullary junction discrimination.

ABBREVIATIONS: angio-suite = angiography suite; CBCT = conebeam CT; CTDI = CT dose index

The early detection of hemorrhagic complications in neuroendovascular therapy is crucial for subsequent appropriate interventions.¹ To check and detect these complications through CT imaging, recent angiography suite (angio-suite) devices use C-arm conebeam CT (CBCT) technology. This technology enables the 3D reconstruction of CT-like images from C-arm rotational imaging.² This feature enables the acquisition of CT-like images


without the need to move the patient during the procedure, enabling the swift identification of hemorrhagic complications.

In conventional CBCT, the rotation of the C-arm is controlled by a single-axis motor, capturing x-ray images with pulse irradiation along the rotational trajectory, specifically focusing on the vertical cross-section of a patient. The 3D reconstruction is then performed. However, due to the limitation of a 240° rotation range, artifacts caused by high x-ray absorption in bony structures degrade image quality, making it inferior to standard CT. The C-arm rotation is controlled by a single-axis motor to collect x-ray images using a rotational trajectory confined to the vertical plane. The rotation spans 240° from right anterior oblique (RAO) 120° to left anterior oblique (LAO) 120° without irradiation from the occipital side, making it prone to artifacts attributable to the bone structure. This effect is particularly pronounced in the posterior cranial fossa surrounded by bones, thereby impeding the detection of small amounts of bleeding.

Received April 25, 2024; accepted after revision August 13.

From the Department of Stroke and Cerebrovascular Diseases (H.H., Y.I., K.H., M.H., A.M., H.Y., Y.M.), Division of Stroke Prevention and Treatment (H.H., H.Y.), Department of Neurosurgery (H.H., Y.I., A.M., Y.M.), Institute of Medicine, Department of Neurology (M.H.), Institute of Medicine, University of Tsukuba, Ibaraki, Japan; and Department of Diagnostic Radiology (T.M.), Toranomon Hospital, Tokyo, Japan.

Please address correspondence to Hisayuki Hosoo, MD, Division of Stroke Prevention and Treatment, Department of Neurosurgery, Institute of Medicine, University of Tsukuba, 1-1-1, Tennodai, Tsukuba City, Ibaraki, Japan; e-mail: hisayuki.hosoo@gmail.com; @neuro_CR

 Indicates open access to non-subscribers at www.ajnr.org

<http://dx.doi.org/10.3174/ajnr.A8472>

SUMMARY

PREVIOUS LITERATURE: A newly developed CBCT protocol with a novel trajectory (dual-axis butterfly scan) controls C-arm rotation using a dual-axis motor. Our previous comparative analysis of image quality between conventional and dual-axis butterfly CBCT revealed reduced artifacts, enhanced contrast between the brain parenchyma and CSF, and improved corticomedullary junction discrimination for the latter procedure. However, a previously used dual-axis butterfly scan required a slightly higher radiation dose (65 mGy) than conventional CBCT (45 mGy).

KEY FINDINGS: Compared with conventional CBCT, medium-dose butterfly CBCT (45 mGy) reduced artifacts and improved contrast and corticomedullary junction evaluation, as observed for the normal dose. Low-dose butterfly CBCT (30 mGy) also achieved reduced artifacts and improved contrast, but similar or worse corticomedullary junction discrimination was observed.

KNOWLEDGE ADVANCEMENT: CBCT with angiographic devices can be used to quickly detect hemorrhage and diagnose acute infarction. Butterfly scans, especially at high (65 mGy) and medium (45 mGy) doses, provide reduced artifacts and better contrast. The low-dose mode (30 mGy) is preferred for pediatric cases to limit radiation exposure.

A newly developed CBCT with a novel trajectory (dual-axis butterfly scan) controls C-arm rotation with a dual-axis motor.³ This introduced a new rotation trajectory, capturing cross-sectional information not only in the vertical plane but also from oblique angles, resembling a pendulum motion. The dual-axis butterfly scan follows a dual-axis trajectory and features a propeller-like rotation for cardiac imaging that spans LAO 65° to RAO 176°, coupled with a pendulum-like tilting motion ranging from 15° cranially to 15° caudally (Fig 1). X-ray images from pulse irradiation in each direction are collected, allowing 3D image reconstruction. The multidirectional image information enables the correction of artifacts caused by high x-ray absorption, promising enhanced image quality through artifact reduction. Our previous comparative analysis of image quality between conventional CBCT and dual-axis butterfly CBCT revealed reduced artifacts, particularly in the posterior cranial fossa, enhanced contrast between the brain parenchyma and CSF, and

improved corticomedullary junction discrimination, leading to enhanced image quality.⁴

However, the dual-axis butterfly scan used in the previous study had a slightly higher radiation dose compared with conventional CBCT (conventional CBCT irradiation exposure: 45 mGy; dual-axis butterfly scan; 65 mGy). In this study, addressing the concern of radiation exposure, 2 dose-reduction modes were developed for the new dual-axis butterfly CBCT system. In comparison with the normal dual-axis butterfly CBCT dose of 65 mGy set as 100%, these modes include a medium-dose mode with a 70% reduction in dose and a low-dose mode with a 50% reduction. These dose-reduction modes are anticipated to be applicable especially for patients requiring lower invasiveness, such as pregnant women and children.⁵ Adjusting the trajectory did not affect the dose, and it is possible to create different dose levels for the same acquisition type. The dose (CT dose index [CTDI]) is a design choice of the x-ray protocols, and it depends on the frame

rate, scan length, tube current, exposure time, voltage, and prefilter setting. The voltage and prefilter setting were not changed in any of the protocols. The frame rate was increased from 30 to 60 frames per second to lower the scan time. Finally, the CTDI was measured on a CTDI phantom; then, the tube current (milliamperere) and exposure time (millisecond) were increased or decreased until the measured CTDI matched the requirements (30, 45, and 65 mGy for low, medium, and normal doses, respectively).

This study aimed to compare and assess the image quality of medium- and low-dose dual-axis butterfly scans against conventional CBCT and to examine the appropriate clinical use for each dose.

MATERIALS AND METHODS

Study Participants

Between July 2022 and January 2023, we enrolled patients who had undergone

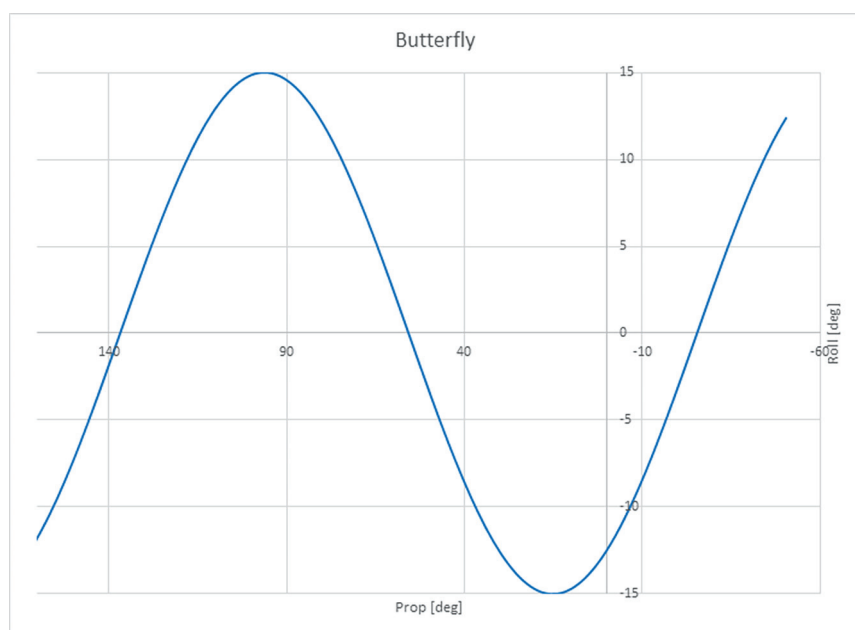


FIG 1. Schematic of the trajectory of the butterfly scan. Prop indicates propeller; deg, degree.

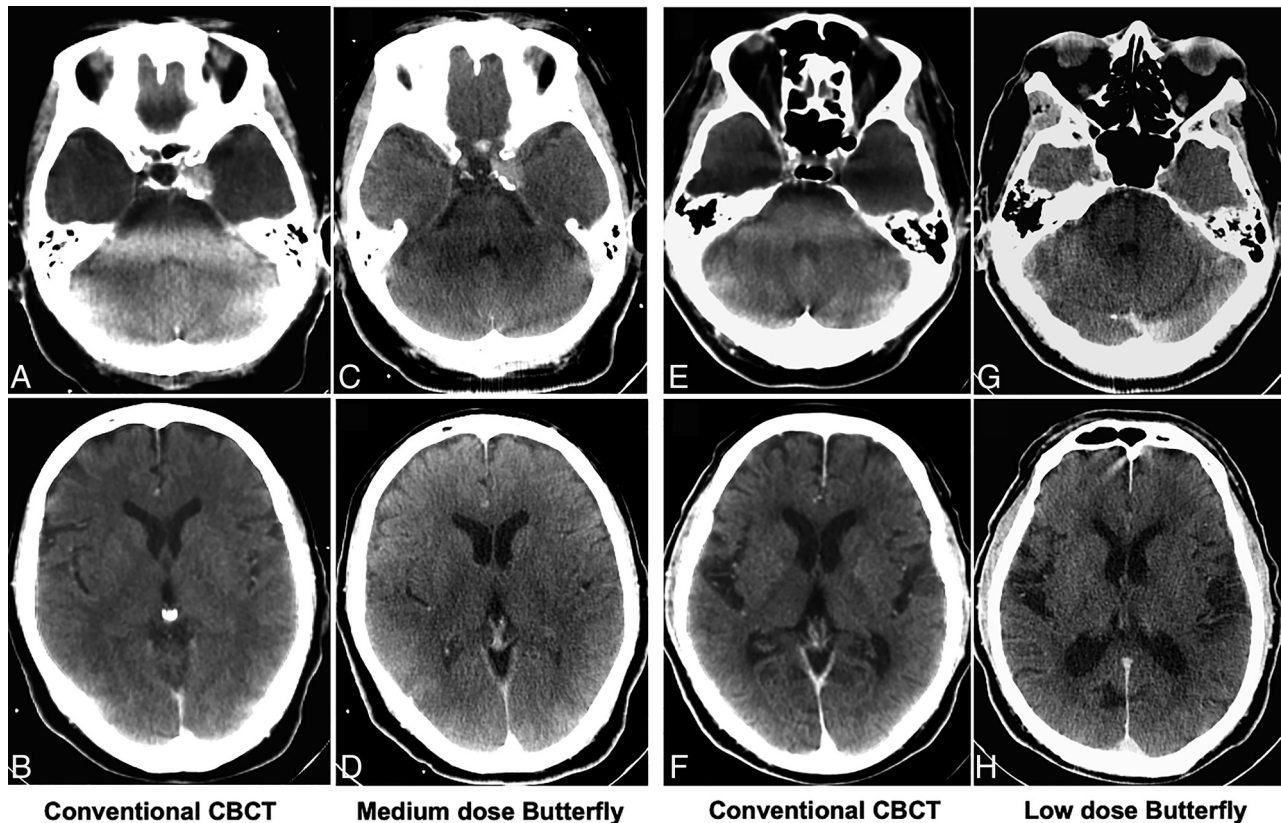


FIG 2. Illustrative case of each medium-dose group and low-dose group. *A–D*, Imaging from the same patient in the medium-dose group, with *A* and *B* being a conventional CBCT and *C* and *D* being a medium-dose butterfly scan. *E–H*, Imaging from the same patient in the low-dose group. *E* and *F*, Conventional CBCT. *G* and *H*, Low-dose butterfly scan.

scheduled neuroendovascular treatment and CBCT as a postoperative assessment. Informed consent was obtained from all patients or their surrogates. Participants agreed to undergo both conventional CBCT and a reduced-dose-mode butterfly scan. Exclusion criteria were patients experiencing challenges with head immobilization during imaging, individuals with acute ischemic stroke, and women who were pregnant or capable of becoming pregnant. Approval for this study protocol was granted by our institutional review board and registered on the Japan Registry of Clinical Trials (jRCTs032220133).

Angio-Suite Equipment and Imaging Protocol

A biplane angiography system (AzurionB20/15; Philips Healthcare) was used for C-arm-based conebeam CT. The frontal C-arm features a cesium iodide-amorphous silicon flat panel detector, measuring 30 × 40 cm and comprising 2586 × 1904 pixels. The detector was 4 × 4, binned and resized to 512², providing a pixel size of 0.741 mm. The x-ray tube voltage was adjusted to 120 kV with a focal spot of 0.7 mm. Additionally, a copper filter, sized at 0.4 mm, was used.

This study compared 2 acquisition protocols following neuroendovascular treatment. The first protocol used the commercially available XperCT HD protocol (conventional CBCT; Philips Healthcare), featuring a circular trajectory lasting 20.8 seconds with 30 frames per second (620 images for 3D reconstruction) (45 mGy). The second protocol involved an investigational device for optimized conebeam CT with a dual-axis butterfly trajectory

lasting 8 seconds, with an acquisition of 60 frames per second (480 images for 3D reconstruction). The radiation dose was 65 mGy in the high-quality mode of a butterfly scan, which was investigated in a previous study.⁴ As mentioned earlier, the current study used 2 modes with reduced radiation doses: a medium dose (70% of the original dose, ~45 mGy, termed medium-dose butterfly scan) and a low dose (50% of the original dose, ~30 mGy, termed low-dose butterfly scan). The enrolled patients were assigned alternately to receive either dose.

After the treatment, CBCT imaging was performed using conventional CBCT and one of the reduced-radiation butterfly scans, which was assigned before treatment. The obtained images were processed using a workstation (Interventional Workstation; Philips Healthcare), applying metal artifact reduction, and were evaluated in axial sections (Fig 2). The image slice thickness was set to 5 mm for investigation. The size of the reconstructable field of view was slightly smaller at the neck, which is typically not relevant.

Regarding the 3D reconstruction algorithm, the algorithm used in this study followed a previously reported method.⁶ Briefly, 3D reconstruction for both protocols was achieved using the Schomberg method,⁷ with an additional 2-pass bone beam-hardening correction applied, as is common in CT reconstruction.^{8,9} The new protocols use both optimized acquisition settings and reconstruction improvements to analyze and reconstruct imaging data collected from an oblique direction, whereas the conventional protocols do not use the reconstruction improvements. Butterfly CBCT thus uses a more advanced algorithm with

reduced artifacts. At a CTDI of 45 mGy, both the butterfly scan (medium dose) and conventional CBCT have an effective dose of 1.6 mSv.³

The evaluation method and criteria were conducted as previously reported for the butterfly scan.⁴ In both the medium- and low-dose butterfly groups, the image quality of the conventional CBCT was compared with that of the respective butterfly scans.

Image Artifact Evaluation

The primary outcome involved assessing artifacts in both the supra- and infratentorium areas. Images obtained from 2 different imaging methods from the same patient were individually evaluated for image quality by 3 evaluators: a certified neurosurgeon (H.H.), stroke neurologist (M.H.), and neuroradiologist (T.M.). Each evaluator provided a subjective assessment. We used a 5-point subjective rating scale (1, little or no artifacts; 2, some artifacts seen but not interfering with the diagnosis; 3, artifacts seen in a wide range but not interfering with the diagnosis; 4, diagnosable areas remained but interfered with the diagnosis; and 5, no diagnosable areas). The average score of the 3 investigators was calculated. During the evaluation, the identity of each image was blinded to avoid bias.

Brain Contrast Evaluation

We also conducted similar evaluations for the contrast between brain parenchyma structures and CSF spaces. For each of the medulla oblongata, pons, midbrain, basal ganglia, frontal lobe, temporal lobe, and occipital lobe, 3 evaluators independently rated the contrast on a 5-point scale (1, sufficient contrast for diagnosis; 2, insufficient contrast in some areas; 3, insufficient contrast in large areas but not impairing diagnosis; 4, areas of contrast remaining but impairing diagnosis; and 5, poor contrast throughout, not diagnostic at all). The average score of the 3 investigators was calculated.

Corticomedullary Junction Evaluation

Corticomedullary junction discrimination was evaluated. The evaluation method was the same as the aforementioned brain contrast evaluation. We assessed the following areas: basal ganglia,

frontal lobe (precentral), temporal lobe (temporal tip), and occipital lobe (superior medial to the calcarine sulcus).

Statistical Analysis

For each evaluation criterion, the average scores from the 3 evaluators for each subject were statistically compared between the 2 imaging methods. We used the Wilcoxon signed-rank test for comparison of paired variates. The data were shown as median (25th to 75th percentile). A *P* value of < .05 was defined as significant. The Cronbach α was calculated for each imaging method and each item to assess interrater agreement. SPSS Version 29 (IBM) was used for statistical analysis.

RESULTS

During the study period, 20 patients (40 paired images) were registered in the medium-dose butterfly group; and 20 patients (40 paired images), in the low-dose butterfly group. The Table summarizes the patient characteristics and the details of the neurointervention treatments in each group. The Cronbach α for each imaging method and evaluation item was as follows: artifacts, 0.889 for conventional CBCT and 0.921 for the butterfly scan; contrast, 0.895 for conventional CBCT and 0.859 for the butterfly scan; and corticomedullary junction, 0.814 for conventional CBCT and 0.769 for the butterfly scan.

Results of the Medium-Dose Butterfly Group

Figure 2A–D shows 1 case of representative images of both conventional CBCT and the medium-dose butterfly scan in the medium-dose group (Fig 2A, –B, conventional CBCT; Fig 2C, –D, medium-dose butterfly scan).

In artifact evaluation, medium-dose butterfly scans showed a significant reduction in artifacts in both supra- and infratentorium areas compared with conventional CBCT. The scores for each area were as follows: conventional CBCT versus medium-dose butterfly scan; supratentorium, 2.67 versus 1.50, *P* < .001; infratentorium, 3.67 versus 2.33, *P* < .001 (Fig 3A).

In contrast evaluation, the medium-dose butterfly scan showed significantly better contrast than the conventional CBCT in all the areas examined. The scores for each area were as follows:

conventional CBCT versus medium-dose butterfly scan: medulla oblongata, 4.00 versus 2.33, *P* < .001; pons, 4.00 versus 2.00, *P* < .001; midbrain, 2.83 versus 1.67, *P* < .001; basal ganglia, 1.33 versus 1.00, *P* < .001; frontal lobe, 1.67 versus 1.00, *P* < .001; temporal lobe, 2.33 versus 1.67, *P* < .001; occipital lobe, 2.33 versus 1.67, *P* = .001 (Fig 4A).

In corticomedullary junction discrimination, medium-dose butterfly scans exhibited superiority in the basal ganglia, frontal lobe, and temporal lobe, though no significant difference in the occipital lobe was observed. The scores for each area were as follows: conventional CBCT versus medium-dose butterfly scan: basal ganglia,

Summary of patient characteristics and details of treatment in the medium- and low-dose butterfly groups

	Medium Dose (n = 20)	Low Dose (n = 20)
Age (mean) (yr)	60.4 (SD, 15.5)	62.0 (SD, 15.7)
Sex (No.) (%)		
Male	12 (60.0)	12 (60.0)
Female	8 (40.0)	8 (40.0)
Treatment details (No.) (%)		
Embolization or FD for aneurysm	11 (55.0)	9 (45.0)
Tumor embolization	2 (10.0)	2 (10.0)
Embolization for DAVF	3 (15.0)	1 (5.0)
CAS	2 (10.0)	4 (20.0)
PTAS	1 (5.0)	2 (10.0)
Embolization for AVM	1 (5.0)	2 (10.0)
Anesthesia (No.) (%)		
General anesthesia	17 (85.0)	16 (80.0)
Local anesthesia	3 (15.0)	4 (20.0)

Note:—DAVF indicates dural arteriovenous fistula; CAS, carotid artery stenting; PTAS = percutaneous transluminal angioplasty and stenting; FD, flow diverter.

1.83 versus 1.67, $P = .035$; frontal lobe, 1.67 versus 1.33, $P < .001$; temporal lobe, 2.83 versus 2.33, $P < .001$; occipital lobe, 3.00 versus 2.33, $P = .085$ (Fig 5A).

Results of the Low-Dose Butterfly Group

Figure 2E–H shows 1 case of representative images of both conventional CBCT and low-dose butterfly scans in the low-dose group (Fig 2E, -F, conventional CBCT; Fig 2G, -H, low-dose butterfly).

In artifact evaluation, low-dose butterfly scans showed significant reductions in artifacts in both supra- and infratentorium areas compared with conventional CBCT. The scores for each area were as follows: conventional CBCT versus low-dose butterfly scan: supratentorium, 2.33 versus 1.00, $P < .001$; infratentorium, 3.67 versus 2.00, $P < .001$ (Fig 3B).

In contrast evaluation, low-dose butterfly scans showed significantly better contrast than conventional CBCT in all the areas examined except for the occipital lobe.

The scores for each area were as follows: conventional CBCT versus low-dose butterfly scan: medulla oblongata, 4.00 versus 3.17, $P = .001$; pons, 3.83 versus 2.33, $P < .001$; midbrain, 2.33 versus 1.67, $P < .001$; basal ganglia, 1.33 versus 1.00, $P < .001$; frontal lobe, 1.67 versus 1.00, $P = .001$; temporal lobe, 2.00 versus 1.33, $P < .001$; occipital lobe, 2.00 versus 1.67, $P = .218$ (Fig 4B).

In corticomedullary junction discrimination, no significant difference was observed between the 2 imaging methods in the basal ganglia, frontal lobe, or temporal lobe. In the occipital lobe, the low-dose butterfly scan showed a deterioration compared with conventional CBCT: conventional CBCT versus low-dose butterfly scan: basal ganglia, 1.67 versus 2.00, $P = .212$; frontal lobe, 2.50 versus 2.33, $P = .093$; temporal lobe, 1.67 versus 1.83, $P = .565$; occipital lobe, 2.50 versus 2.67, $P = .010$ (Fig 5B).

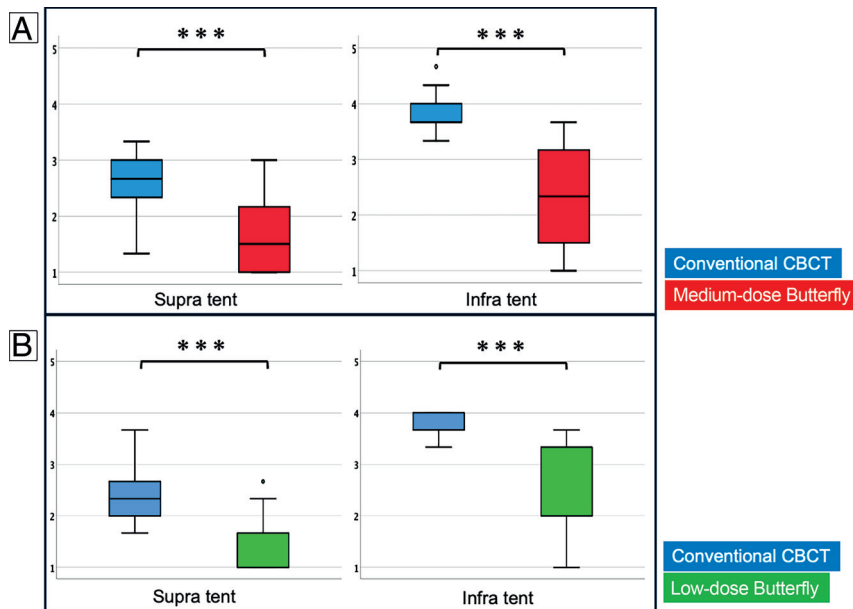


FIG 3. Results of artifact evaluations. A, The results of the medium-dose group. B, The results of the low-dose group. ***, $P < .001$; **, $P < .01$; *, $P < .05$. Supra tent indicates supratentorial; Infra tent, infratentorial.

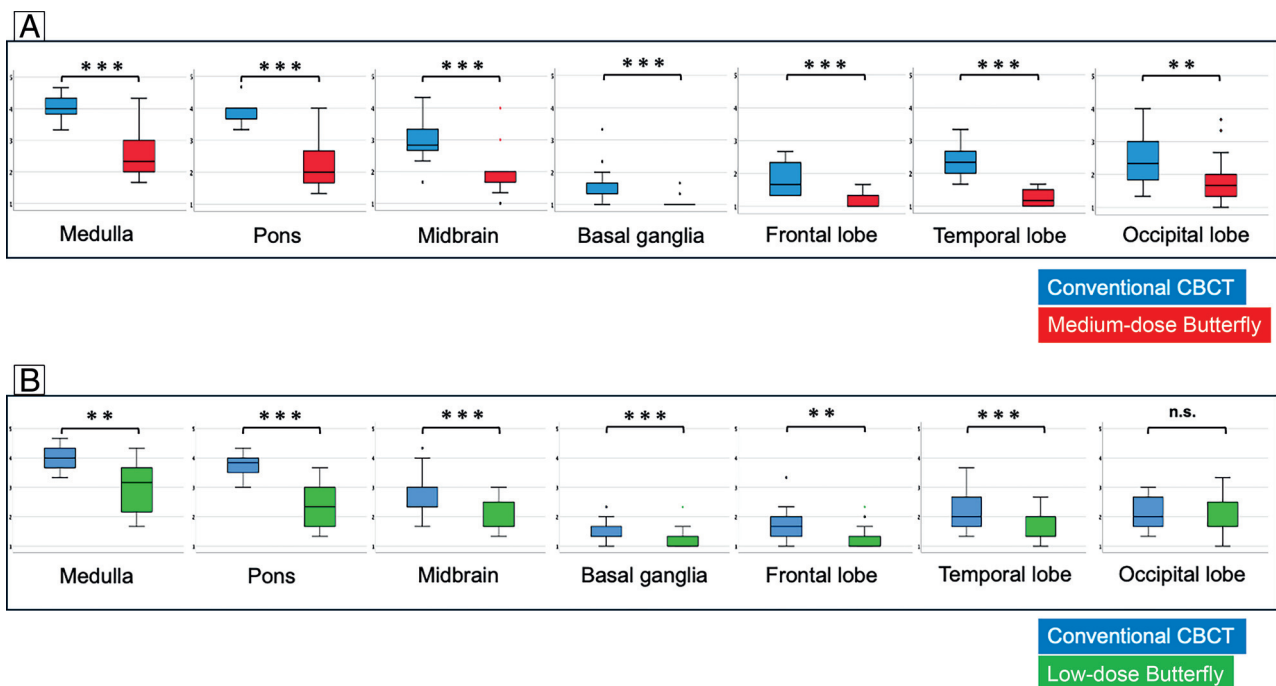


FIG 4. Results of contrast evaluations. A, The results of the medium-dose group. B, The results of the low-dose group. ***, $P < .001$; **, $P < .01$; *, $P < .05$; n.s., not significant.

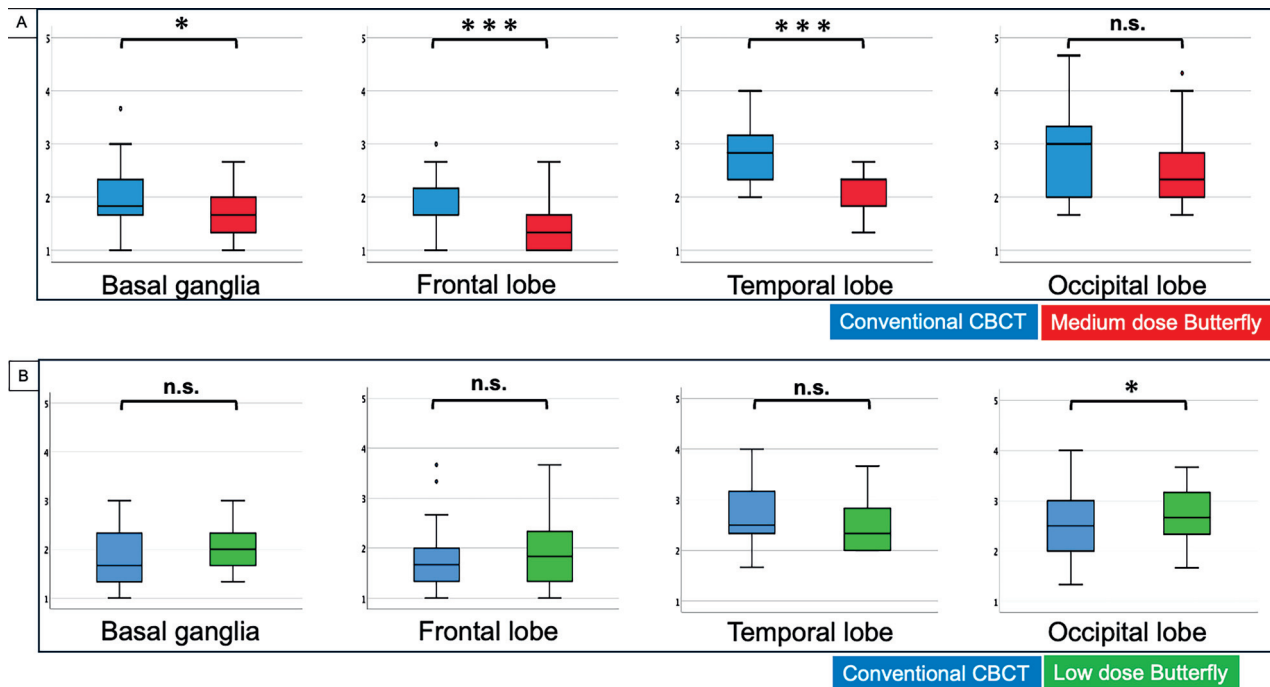


FIG 5. Results of corticomedullary junction discrimination. *A*, The results of the medium-dose group. *B*, The results of the low-dose group: ***, $P < .001$; **, $P < .01$; *, $P < .05$; n.s., not significant.

DISCUSSION

Compared with conventional CBCT, the medium-dose butterfly scan (45 mGy), similar to the previously investigated normal dose of high-quality mode (65 mGy), exhibited reduced artifacts and improved contrast evaluation and corticomedullary junction discrimination, though no significant advantage was observed in corticomedullary junction discrimination in the occipital lobe. As the dose decreased to low-dose butterfly scan (30 mGy), the superiority in reducing artifacts and improving contrast, except in the occipital lobe, compared with conventional CBCT, was maintained. However, in terms of corticomedullary junction discrimination, it was either equivalent in all regions examined or inferior in the occipital lobe.

In a dual-axis butterfly scan, both horizontal movements and pendulum-like vertical movements are involved, resulting in reduced artifacts because bone beam-hardening and conebeam effects are mitigated, leading to reduced artifacts and improved contrast and corticomedullary junction discrimination. Despite the fewer acquired images and shorter imaging time exhibited by dual-axis butterfly scans relative to conventional CBCT, image quality improves due to this unique imaging trajectory.^{3,4,6} However, when the dose decreases to around 50%, though the artifact-reduction effect of the unique trajectory is maintained, superiority in brain parenchymal image quality may diminish. This result is particularly evident in areas susceptible to bone influence. The deteriorating image quality of the occipital lobe may be attributed, in part, to reconstruction using images acquired from inclined angles not irradiated in the conventional circular rotation in the butterfly scan. Specifically, data obtained from x-ray irradiation along a line connecting the mandible to the occipital lobe tend to have higher bone density and lower x-ray penetration,

resulting in insufficient contrast during reconstruction. Although the low-dose butterfly scan yielded improvement in intratentorium artifacts compared with conventional CBCT, reducing the dose may also lower the effectiveness of artifact reduction.

The medium-dose butterfly scan and conventional CBCT in this study had approximately the same radiation dose, but the former had superior image quality in almost all aspects, implying that the new trajectory of the butterfly scan has a direct effect on reducing artifacts and improving contrast.

CBCT performed with angiographic devices offers the advantage of promptly detecting hemorrhagic complications during or after procedures. In addition, we expect it may also have potential utility in diagnosing acute-phase cerebral infarction. Patients suspected of having acute ischemic stroke usually undergo CT imaging for diagnosis first. Early ischemic changes are recognized by the blurring of the gray-white matter interface, allowing estimation of the ischemic core from this area.¹⁰ CT findings are important not only in excluding hemorrhagic stroke but also in determining the treatment strategy for large-vessel occlusion. In cases of large-vessel occlusion, early reperfusion therapy is desirable for a more favorable outcome. In recent years, the concept of the Direct to Angio-Suite Protocol has emerged, in which routine CT is bypassed and patients are directly transported to the angi-suite. The time metrics of direct transport to angiography suites has been reported in several observational studies and single-center randomized controlled trials.¹¹⁻¹⁴ Requena et al¹⁴ conducted a randomized controlled trial and reported that the use of this strategy increased the odds of patients undergoing endovascular treatment, decreased hospital workflow, and improved clinical outcome compared with the conventional workflow. They used flat panel CBCT for diagnosis. Subsequently, a diagnostic angiogram

was obtained to confirm the presence of a large-vessel occlusion. A meta-analysis integrating these studies also suggested that directly transporting patients to angiography suites could lead to faster treatment and reperfusion, potentially resulting in improved long-term functional outcomes.¹⁵ To ensure the quality of this treatment workflow, the image quality of CBCT is crucial. A butterfly scan, which improves corticomedullary junction discrimination, can detect early signs of ischemia while effectively differentiating hemorrhagic stroke. Furthermore, given the frequent agitation and inability of patients to remain still, the butterfly scan, which has a shorter duration (8 seconds) compared with conventional CBCT (20.8 seconds), is anticipated to offer substantial benefits. Considering the dose for the butterfly scan, the high-quality mode (65 mGy) is recommended for the detailed detection of early ischemic changes.

Conversely, for evaluating hemorrhagic complications post-conventional neuroendovascular treatment, doses at or above the medium-dose mode (45 mGy) are likely sufficient for effective detection. The low-dose mode (30 mGy) has decreased ability in identifying corticomedullary junction discrimination, yet artifact reduction and contrast remain superior to those of conventional CBCT. In cases of pediatric cerebral arteriovenous shunt diseases, such as vein of Galen aneurysmal malformation, dural sinus malformation, and arteriovenous malformation, in which repeated treatments are often necessary,^{16,17} consideration should be given to using the low-dose mode to mitigate potential future effects of radiation exposure.

Compared with conventional CBCT, the butterfly scan also involves movement in the vertical direction; thus, consideration is needed to avoid interference with surrounding equipment such as anesthesia machines. However, patient positioning can be performed in the same manner.⁴

In recent years, reports have described the imaging trajectories in CBCT using flat panel detectors with other types of angiography suites that incorporate vertical movement, similar to the imaging protocol used in this study. Although the angle of vertical movement differs, with ours being 15° cranially and caudally and that in other reports being 10° in both directions, the addition of vertical movement contributes to improved image quality.^{18,19} It is expected that further improvements in image quality can be achieved by adjusting the angle and range of movement of the flat panel.

This study has certain limitations. It was based on a small number of cases within a single institution and a limited time period. It was anticipated beforehand that reducing the dose versus the full dose could result in lower image quality. Therefore, we aimed to verify through comparisons with conventional CBCT whether the improvement in image quality of the new trajectory of the butterfly scan could be ensured with a lower dose. The reduction in dose suggested a decrease in contrast and discrimination of the corticomedullary junction; however, the comparison was made only between the butterfly scan and conventional CBCT. Although the reduction in dose maintained the artifact reduction effect compared with conventional CBCT, the specific changes resulting from dose reduction of butterfly scans require further investigation. Furthermore, this study and previous research did not compare the image quality between the dual-axis butterfly scan and conventional CT. Future studies should address this omission by evaluating the extent to which the dual-

axis butterfly scan improves image quality compared with conventional CT.

CONCLUSIONS

In the dose-reduction mode of the butterfly scan, reducing the dose to 70% of the original dose still resulted in satisfactory artifact reduction, contrast enhancement, and corticomedullary junction discrimination. However, at a 50% dose reduction, while artifact reduction and contrast improvement were still attainable, the images became more susceptible to interference from bone. Improved corticomedullary junction discrimination was then lost. Even with a reduction in dose, the specialized trajectory of the butterfly scan enables artifact reduction, improvement in contrast, and enhancement of corticomedullary junction discrimination. However, the impact of the reduced dose was more noticeable, particularly in the occipital region where susceptibility to bone interference results in decreased contrast and compromised corticomedullary junction discrimination. Overall, setting the dose to at least 45 mGy is recommended to maintain optimal imaging quality.

ACKNOWLEDGMENTS

We would like to thank Paul Withagen, Peter van de Haar, Fred van Nijnatten, Erik Hummel (Image Guided Therapy, Phillips Healthcare), and Dirk Schäfer (Philips Research) for their contribution to the process of algorithm development. We would also like to thank Enrico Contini and Marijke van Vlimmeren (Image Guided Therapy; Phillips Healthcare) for their contribution to the study support.

Disclosure forms provided by the authors are available with the full text and PDF of this article at www.ajnr.org.

REFERENCES

1. van Rooij WJ, Sluzewski M, Beute GN, et al. **Procedural complications of coiling of ruptured intracranial aneurysms: incidence and risk factors in a consecutive series of 681 patients.** *AJNR Am J Neuroradiol* 2006;27:1498–501 [Medline](#)
2. White PM, Gilmour JN, Weir NW, et al. **AngioCT in the management of neurointerventional patients: a prospective, consecutive series with associated dosimetry and resolution data.** *Neuroradiology* 2008;50:321–30 [CrossRef Medline](#)
3. Nicholson P, Cancelliere NM, Bracken J, et al. **Novel flat-panel cone-beam CT compared to multi-detector CT for assessment of acute ischemic stroke: a prospective study.** *Eur J Radiol* 2021;138:109645 [CrossRef Medline](#)
4. Hosoo H, Ito Y, Marushima A, et al. **Image quality improvements for brain soft tissue in neuro-endovascular treatments: a novel dual-axis “butterfly” trajectory for optimized cone-beam CT.** *Eur J Radiol* 2023;160:110713 [CrossRef Medline](#)
5. Brenner D, Elliston C, Hall E, et al. **Estimated risks of radiation-induced fatal cancer from pediatric CT.** *AJR Am J Roentgenol* 2001;176:289–96 [CrossRef Medline](#)
6. Cancelliere NM, Hummel E, van Nijnatten F, et al. **The butterfly effect: improving brain cone-beam CT image artifacts for stroke assessment using a novel dual-axis trajectory.** *J Neurointerv Surg* 2022;15:283–87 [CrossRef Medline](#)
7. Schomberg HA. **Fourier-filtered backprojection algorithm for cone-beam CT.** In: *Proceedings of the Eighth International Meeting*

- on Fully Three-Dimensional Image Reconstruction in Radiology and Nuclear Medicine. Salt Lake City, Utah. July 11–July 15, 2005.
8. Joseph PM, Spital RD. A method for correcting bone induced artifacts in computed tomography scanners. *J Comput Assist Tomogr* 1978;2:100–08 [CrossRef Medline](#)
 9. Nalcioglu O, Lou RY. Post-reconstruction method for beam hardening in computerised tomography. *Phys Med Biol* 1979;24:330–40] [CrossRef Medline](#)
 10. Barber PA, Demchuk AM, Zhang J, et al. Validity and reliability of a quantitative computed tomography score in predicting outcome of hyperacute stroke before thrombolytic therapy: ASPECTS Study Group—Alberta Stroke Programme Early CT Score. *Lancet* 2000;355:1670–74 [CrossRef Medline](#)
 11. Psychogios MN, Maier IL, Tsogkas I, et al. One-stop management of 230 consecutive acute stroke patients: report of procedural times and clinical outcome. *J Clin Med* 2019;8:2185 [CrossRef](#)
 12. Psychogios MN, Behme D, Schregel K, et al. One-stop management of acute stroke patients: minimizing door-to-reperfusion times. *Stroke* 2017;48:3152–55 [CrossRef Medline](#)
 13. Pfaff JA, Schönenberger S, Herweh C, et al. Direct transfer to angi-suite versus computed tomography-transit in patients receiving mechanical thrombectomy: a randomized trial. *Stroke* 2020;51:2630–38 [CrossRef Medline](#)
 14. Requena M, Olivé-Gadea M, Muchada M, et al. Direct to angiography suite without stopping for computed tomography imaging for patients with acute stroke: a randomized clinical trial. *JAMA Neurol* 2021;78:1099–107 [CrossRef Medline](#)
 15. Mohammeden MH, Doheim MF, Elfil M, et al. Direct to angi-suite versus conventional imaging in suspected large vessel occlusion: a systemic review and meta-analysis. *Stroke* 2022;53:2478–87 [CrossRef Medline](#)
 16. Giorgi L, Durand P, Morin L, et al. Management and outcomes of neonatal arteriovenous brain malformations with cardiac failure: a 17 years' experience in a tertiary referral center. *J Pediatr* 2020;218:85–91.e82 [CrossRef Medline](#)
 17. Berenstein A, Ortiz R, Niimi Y, et al. Endovascular management of arteriovenous malformations and other intracranial arteriovenous shunts in neonates, infants, and children. *Childs Nerv Syst* 2010;26:1345–58 [CrossRef Medline](#)
 18. Petroulia VD, Kaesmacher J, Piechowiak EI, et al. Evaluation of sine spin flat detector CT imaging compared with multidetector CT. *J Neurointerv Surg* 2023;15:292–97 [CrossRef Medline](#)
 19. Luecking H, Hoelter P, Lang S, et al. Change your angle of view: sinusoidal C-arm movement in cranial flat-panel CT to improve image quality. *Clin Neuroradiol* 2022;32:1109–15 [CrossRef Medline](#)