

Are your **MRI contrast agents** cost-effective?

Learn more about generic **Gadolinium-Based Contrast Agents**.



FRESENIUS
KABI

caring for life

AJNR

CT-guided biopsy for the detection and staging of tumors of the head and neck.

R A Gatenby, C B Mulhern, Jr, M P Richter and P J Moldofsky

AJNR Am J Neuroradiol 1984, 5 (3) 287-290

<http://www.ajnr.org/content/5/3/287>

This information is current as
of May 27, 2024.

CT-Guided Biopsy for the Detection and Staging of Tumors of the Head and Neck

Robert A. Gatenby¹
 Charles B. Mulhern, Jr.
 Melvyn P. Richter
 Philip J. Moldofsky

Twenty patients underwent computed tomography (CT)-guided thin-needle biopsy of tumors of the head and neck without complication. This technique was found to have wide application in confirming the presence and extent of primary disease as well as documenting nodal and bony metastases not apparent clinically.

The value of computed tomography (CT)-guided thin-needle biopsy in the abdomen is well recognized [1, 2]. We previously reported a method of CT-guided biopsies of tumors of the head and neck [3] and wish to describe our recent experience in which this technique proved valuable in a variety of clinical problems.

Materials and Methods

Twenty patients underwent CT-guided biopsy to assist in the staging of head and neck neoplasms. All biopsies were performed with the patient in a supine position. The head was not generally fixed during the examination since it frequently had to be rotated slightly during the insertion of the needle. Scanning during the biopsy was performed with the patient's head facing forward with 8 mm section thickness at 4 mm increments. The entire biopsy procedure was performed in the CT room with the patient simply being moved out of the gantry slightly for needle positioning and for the actual biopsy. In general, the entire biopsy procedure lasted about 30 min.

A retromandibular approach was used in 10 patients with oropharyngeal or nasopharyngeal primaries. CT scans were initially obtained to localize the tumor. The skin at that level was then marked using the light from the gantry. After local anesthesia, a 22-gauge needle was inserted behind the mandible to a length predetermined by CT scan measurement to place the tip of the needle within the middle of the tumor. An aspiration biopsy was subsequently performed in the usual manner [4]. Generally, two or three biopsies were obtained on each patient.

Biopsies of eight masses within the neck were performed using similar localizing techniques as described above. The needle was generally inserted through the lateral aspect of the sternocleidomastoid anterior to the level of the carotid and passed parallel to the tabletop so that the carotid artery could be avoided.

Biopsy of a mass involving the sphenoid ridge was performed by inserting the needle under the zygoma and directing the needle tip superiorly to lie behind the maxillary sinus and anterior to the sphenoid wing. A lesion in the maxillary sinus was biopsied by breaking through the anterior wall, which had been thinned by the mass.

Results

The results of the initial 20 patients are summarized in table 1. Pathologic material adequate for diagnosis was obtained in all patients.

In seven patients, no tumor was detectable clinically by physical examination, including direct visualization and palpation. CT was performed to clarify symptoms strongly suggestive of a head and neck tumor, such as cranial nerve paralysis or

Received June 21, 1983; accepted after revision October 24, 1983.

¹All authors: Department of Radiology, Fox Chase Cancer Center and Jeanes Hospital, Central Ave. and Shelmire St., Philadelphia, PA 19111. Address reprint requests to R. A. Gatenby.

AJNR 5:287-289, May/June 1984
 0195-6108/84/0503-0287 \$00.00
 © American Roentgen Ray Society

persistent posterior epistaxis. All of these patients had predominantly or completely submucosal nasopharyngeal masses (figs. 1 and 2).

In eight patients, biopsies were performed as part of a staging procedure. In four, the biopsy was required because CT indicated that the primary tumor was far more extensive than was apparent clinically (figs. 3 and 4). Pathologic confirmation of the CT results was necessary to determine the mode and extent of therapy (i.e., radiation therapy rather than surgery or larger radiation portals than initially planned). In three patients, CT-guided biopsy was used to confirm lymph-node metastasis that was not apparent clinically (fig. 5). In one case, a metastasis to the sphenoid ridge from adenoid cystic carcinoma of a submandibular salivary gland was confirmed (fig. 6).

In five cases, the presence of benign disease was docu-

mented (fig. 7). In two patients, pus was aspirated from an enlarged lymph node. In one case, postoperative fibrosis could not be distinguished from recurrent tumor in a patient who had previously undergone radical neck dissection. In all three cases, clinical follow-up of 6 months to 1 year confirmed the presence of benign disease.

No complications were encountered.

Discussion

We have found CT-guided biopsy in the head and neck to be both safe and clinically useful. In all 20 patients who underwent CT-guided biopsy, the results of the biopsies substantially changed the clinical management.

In eight patients, the presence of a primary or recurrent tumor could be detected only by CT scanning. All of these tumors were predominantly or completely submucosal and therefore not apparent to the clinical examiner. CT-guided biopsy allowed confirmation of the presence of tumor and institution of appropriate therapy without the need for surgical biopsy.

In four patients, the local disease measured by CT was far more extensive than that detected clinically. In all cases, this involved either submucosal or subcutaneous extension of tumor that could not be seen or palpated by the examiners. CT-guided biopsy was used only when a substantial change in therapy would be required by the more extensive tumor seen on CT. By documenting the location of the tip of the biopsy needle with the CT scan and by carefully marking the biopsy specimen, precise information on the level of tumor can be obtained. This information can be critical in decisions involving the mode of therapy (i.e., radiation therapy or surgery) or the planning of portals for radiation therapy.

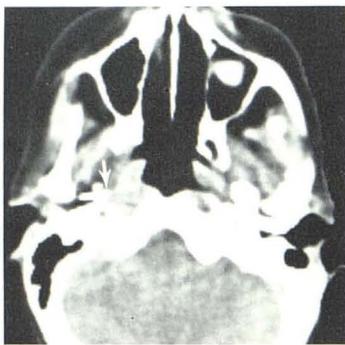
Documentation of lymph-node metastases or tumor extension to the base of the skull also can be performed to clarify tumor stage and determine appropriate management.

Although we have not yet had a false-negative biopsy

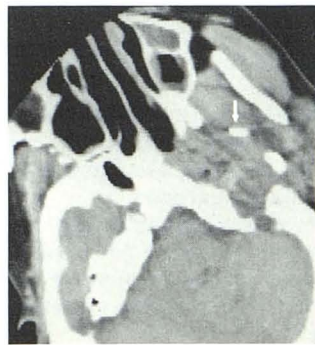
TABLE 1: Summary of CT-Guided Biopsies in the Head and Neck

Indication: Finding	No. Cases
Possible primary or recurrent tumor:	
Squamous cell carcinoma	6
Chondroid chordoma	1
No malignant cells seen*	3
Subtotal	10
Tumor staging:	
Squamous cell carcinoma more extensive than clinically apparent	4
Squamous cell carcinoma in lymph-node metastasis	3
Adenoid cystic carcinoma; metastases to base of skull	1
Pus aspirated from lymph nodes thought possibly to harbor metastasis	2
Subtotal	10
Total	20

* Final diagnoses: one normal regenerated thyroid (after thyroidectomy); one benign mixed tumor of parotid; and one hemangioma.



1 Fig. 1.—Squamous cell carcinoma in pharynx. Needle (arrow) in periphery of small predominantly submucosal squamous cell carcinoma arising in left lateral pharyngeal recess.



2 A Fig. 2.—Chordoma in nasopharynx. **A**, Tip of needle (arrow) in completely submucosal mass in right nasopharynx. **B**, High-power view showing physaliphorous cells indicating chordoma.

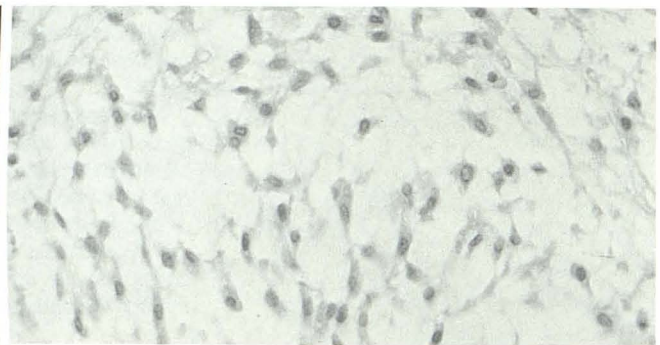


Fig. 3.—Necrotic submandibular cancer. **A**, Necrotic mass in inferior neck. **B** and **C**, Subcutaneous extension superiorly to level of mandible was not clinically apparent. Biopsy needle at level of mandible confirms superior extent of tumor.

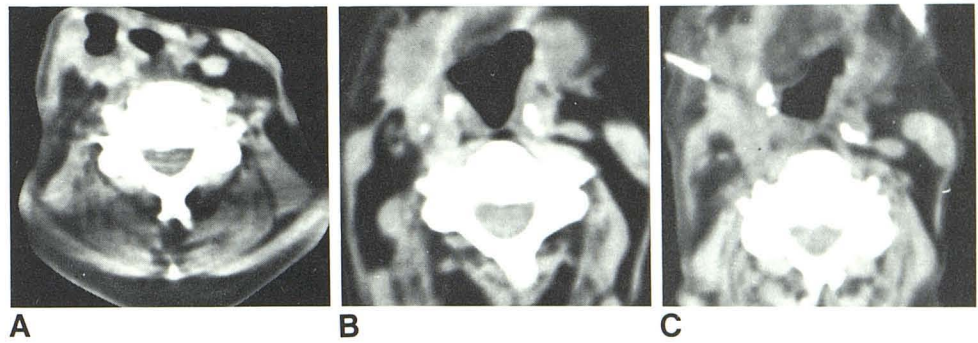
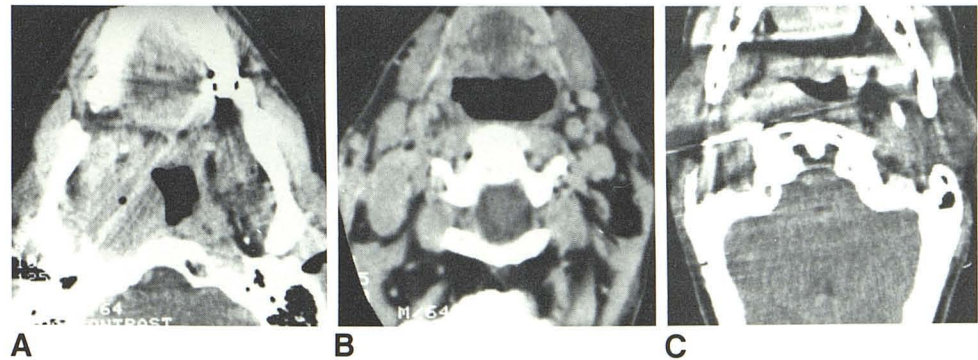


Fig. 4.—Extensive nasopharyngeal cancer. **A** and **B**, Nasopharyngeal carcinoma with submucosal extension into oropharynx to level of base of tongue was not apparent clinically. Adenopathy is also seen. **C**, CT section from multiple biopsies at various levels in nasopharynx and oropharynx confirms more extensive tumor seen in **A** and **B**.



result, we recommend conventional, surgical biopsy be performed if CT-guided needle biopsy does not yield tumor when clinical and/or radiographic suspicion of tumor is high. No complications were encountered in our 20 patients undergoing biopsy. The last 13 cases were biopsied on an outpatient basis without complication. Our initial experience with this technique indicates that it is safe and can play a critical role in both detecting and staging tumors of the head and neck, thereby facilitating optimal management.

ACKNOWLEDGMENTS

We thank Janet Spause, Susan Higman, and Irene Gardner for assistance in manuscript preparation.

Fig. 6.—Adenoid cystic carcinoma in sphenoid ridge. **A**, Destructive mass involving right sphenoid ridge and right orbit in patient with adenoid cystic carcinoma of submandibular gland. **B**, Needle in place in periphery of mass, confirming metastatic adenoid cystic carcinoma.

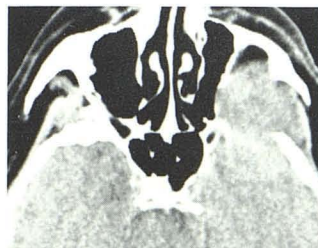
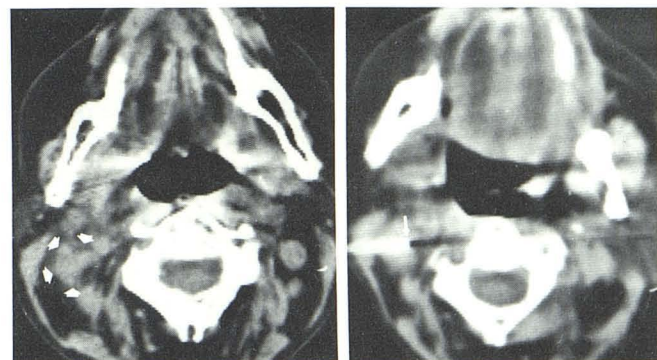


Fig. 7.—Hemangioma of maxillary sinus. Needle within lesion of the right maxillary sinus. Pathology showed blood and multiple endothelial cells but no malignant cells. Final diagnosis: hemangioma.

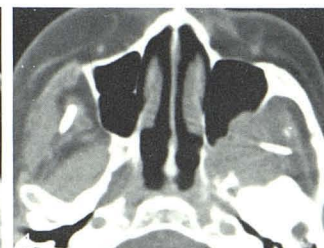
6A



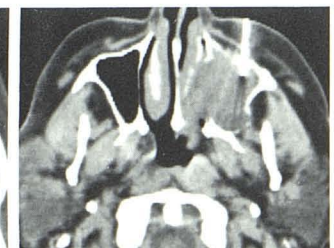
A

B

Fig. 5.—Node metastasis, squamous carcinoma. **A**, Increased soft tissue adjacent to left carotid artery and jugular vein (arrows) suggests adenopathy. **B**, Needle in place (arrow). Biopsy results confirmed metastatic squamous cell carcinoma.



6B



7

REFERENCES

1. Haaga JR, Vanek J. Computed tomographic guided liver biopsy using the Menghini needle. *Radiology* **1979**;133:405-408
2. Ferrucci JT Jr, Wittenberg J. CT biopsy of abdominal tumors: aids for lesion localization. *Radiology* **1978**;129:739-744
3. Gatenby RA, Mulhern CB Jr, Strawitz J. CT-guided percutaneous biopsy of head and neck masses. *Radiology* **1983**;146:717-719
4. Ferrucci JT Jr, Wittenberg J, Mueller PR, et al. Diagnosis of abdominal malignancy by radiologic fine-needle aspiration biopsy. *AJR* **1980**;134:323-330