

Are your **MRI contrast agents** cost-effective?

Learn more about generic **Gadolinium-Based Contrast Agents**.



FRESENIUS  
KABI

caring for life

**AJNR**

**Value of sagittal sonography and direct sagittal CT of the Dandy-Walker syndrome.**

C M Groenhout, R H Gooskens, J A Veiga-Pires, L Ramos, J Willemsse and O van Nieuwenhuizen

*AJNR Am J Neuroradiol* 1984, 5 (4) 476-477

<http://www.ajnr.org/content/5/4/476.citation>

This information is current as of April 19, 2024.

## Value of Sagittal Sonography and Direct Sagittal CT of the Dandy-Walker Syndrome

C. M. Groenhout,<sup>1</sup> R. H. Gooskens,<sup>1</sup> J. A. Veiga-Pires,<sup>2</sup> L. Ramos,<sup>2</sup> J. Willemse,<sup>1</sup> and O. van Nieuwenhuizen<sup>1</sup>

The Dandy-Walker syndrome was first described in 1914 by Dandy and Blackfan [1] and in 1942 by Taggart and Walker [2]. According to Hart et al. [3], the constant features of the syndrome are hydrocephalus, hypoplasia or aplasia of the vermis, and cystic dilatation of the fourth ventricle. Obstruction of the foramina of Luschka and Magendie and the high insertion of the tentorium may be present, but are not constant features. Thus, the syndrome may be noncommunicating or communicating, depending on the patency of the foramina of Luschka and Magendie. In addition, either type may develop secondary obstruction of the aqueduct. Each of these types, therefore, may present a nonobstructive or a secondary obstructive form. Their appearances with conventional radiologic techniques have been well documented [4]. We describe the value of sonography and direct sagittal computed tomographic (CT) scanning in the diagnosis of a patient with Dandy-Walker syndrome. If CT is performed in association with metrizamide ventriculography and/or cisternography, the dynamics of the cerebrospinal fluid (CSF) can be evaluated and the type and form of the lesion established.

### Case Report

A 5-month-old boy was seen with rapidly enlarging head and a wide bulging anterior fontanelle associated with a right frontal bone defect. The patient was one of identical twins of an uncomplicated pregnancy carried to term. The sibling was normal. Within 8 weeks of birth his head circumference increased from the 50th percentile to the 98th percentile. Both the somatic and mental development of the child were normal and equal to that of his sibling. Sonographic sector scanning of the head showed a dilated ventricular system associated with a cyst of the posterior fossa and a hypoplastic cerebellum (fig. 1A). This finding suggested a cerebellar dysplasia.

To ascertain the nature of the lesion, the child was further investigated by conventional CT scanning, which showed marked dilatation of the ventricular system and the characteristic relation of the cyst to the fourth ventricle. No supratentorial developmental lesions were seen (figs. 1B and 1C).

The examination was extended by metrizamide ventriculography. Direct coronal and direct sagittal scans were obtained to study the CSF dynamics. Not only was the connection between the ventricular

system and the cyst confirmed, but an obstruction of the flow of the contrast medium into the subarachnoid spaces was also seen (figs. 1D and 1E). The diagnosis of noncommunicating Dandy-Walker cyst without aqueduct obstruction was made. A single Pudenz drain was placed in the cyst.

### Discussion

Several theories about the pathogenesis of Dandy-Walker syndrome have been postulated. That the pathogenesis of the syndrome is simply atresia of the foramina of Luschka and Magendie [1, 2] has been refuted [5]. Some authors have suggested a maldevelopment in the genesis of the rhombencephalic roof before the foramina open [6, 7].

In the embryo, according to Gardner [8], there is normally an equilibrium between the production of CSF by the choroid plexus and that by the lateral and fourth ventricles. In the Dandy-Walker syndrome this equilibrium is somehow disrupted by a relative overproduction of CSF at the level of the fourth ventricle, which alters its dynamics. This may be associated with a primary agenesis or hypoplasia of the vermis or may be the cause of the vermial dysgenesis. The roof of the rhombencephalic ventricle then herniates along the path of the valleculla and balloons out to form a cyst. This cyst compresses the aqueduct rarely [9]. The foramina of Luschka and Magendie may or may not become patent, resulting in a communicating or a noncommunicating type of lesion.

In our case a wide open fontanelle permitted the workup to proceed from the least invasive (sonography [10]) to the more invasive study (CT metrizamide ventriculography). This demonstrated a noncommunicating Dandy-Walker cyst with aqueduct patency. In our opinion, the variant Dandy-Walker cyst described by Archer et al. [11] and Raybaud [12] falls into the latter category.

We believe that the two types of Dandy-Walker syndrome manifest themselves at different ages. In the noncommunicating type the foramina of Luschka and Magendie are closed ab initio, and this explains both the early onset of the symptoms and the characteristic CT appearances seen in our case. In the communicating type, the foramina must remain open

Received January 6, 1983; accepted after revision August 8, 1983.

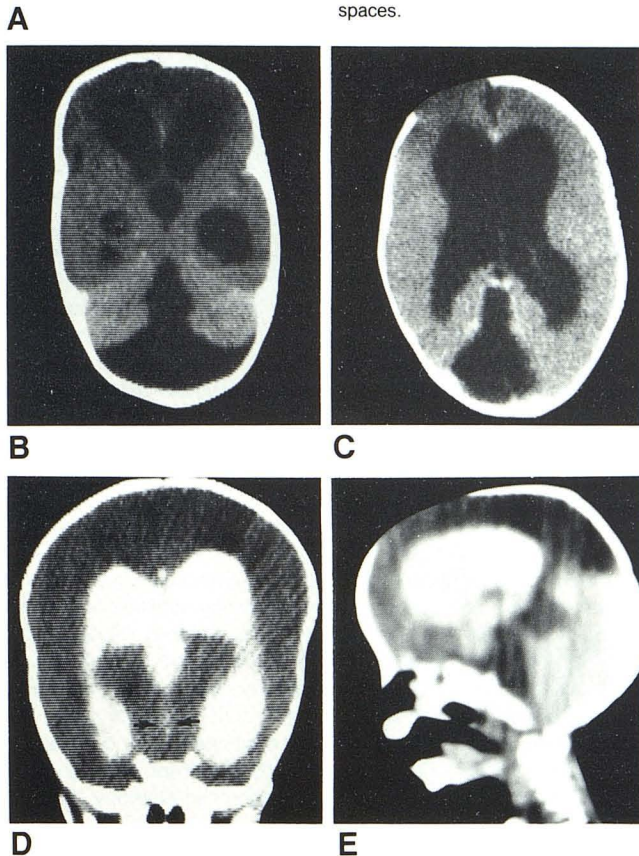
<sup>1</sup> Department of Child Neurology, University Hospital Utrecht, Catharijnesingel 101, 3511 GV Utrecht, The Netherlands. Address reprint requests to R. H. Gooskens.

<sup>2</sup> Department of Neuroradiology, University Hospital Utrecht, 3511 GV Utrecht, The Netherlands.



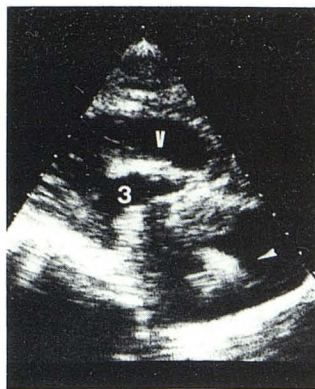

Fig. 1.—**A**, Sagittal paramidline sector sonogram. Dilated lateral ventricular (V) systems; third ventricle (3). Cyst in posterior fossa; hypoplastic cerebellum (arrowhead). **B**, Conventional CT scan shows characteristic shape of fourth ventricle and ballooned posterior wall limited by hypoplastic cerebellar hemispheres. **C**, Gross ventricular dilatation. Large right frontal bone defect. **D**, CT metrizamide ventriculography. Direct coronal scan shows contrast in dilated ventricular system and wide aqueduct (arrows). **E**, Direct sagittal scan. Contrast in lateral ventricles, fourth ventricle, and cyst. High tentorium. No contrast in subarachnoid spaces.



for variable periods of time before the clinical manifestations of the syndrome are obvious [5]. This state of unstable dynamic equilibrium can be disturbed by any form of stress. The actual disturbances of the CSF dynamics may induce further growth of the cyst, which in turn will cause complete or partial functional CSF flow failure. In our experience [13–15] direct sagittal CT scans of the head have proven to be an essential method for imaging intracranial structures, but metrizamide ventriculography is necessary to establish the CSF dynamics. That there was no communication between

the ventricular system and/or cyst and the subarachnoid spaces in the presence of a wide patent aqueduct was instrumental in determining surgical management [9].

In the communicating type without aqueduct obstruction, drainage is not required, but if the aqueduct is obstructed a ventricular shunt is necessary. In the noncommunicating type, drainage is always necessary, with a single shunt in the cyst if the aqueduct is patent. If the aqueduct is occluded both the ventricles and the cyst must be drained.

#### ACKNOWLEDGMENTS

We thank M. C. Kaiser for constructive criticism and T. Wollenberg for illustrations.

#### REFERENCES

1. Dandy WF, Blackfan KD. Internal hydrocephalus: an experimental, clinical and pathological study. *Am J Dis Child* 1914;8:406–482
2. Taggart JK Jr, Walker AE. Congenital atresia of the foramen of Luschka and Magendie. *Arch Neurol Psychiatry* 1942;48:583–612
3. Hart MN, Malamud N, Ellis WG. The Dandy-Walker syndrome: a clinicopathological study based on 28 cases. *Neurology (NY)* 1972;22:771–780
4. Bentson JR, Alberti J. The fourth ventricle. In: Newton TH, Potts DG, eds. *Radiology of skull and brain, vol 4. Ventricles and cisterns*. St. Louis: Mosby, 1978:3303–3363
5. Tal Y, Freigang B, Dunn HG, Durity FA, Moyes PD. Dandy-Walker syndrome: analysis of 21 cases. *Dev Med Child Neurol* 1980;22:189–201
6. Benda CE. The Dandy-Walker syndrome or the so-called atresia of the foramen of Magendie. *J Neuropathol Exp Neurol* 1954;13:14–29
7. Brodal A, Hauglie-Hanssen E. Congenital hydrocephalus with defective development of the cerebellar vermis (Dandy-Walker syndrome). *J Neurol Neurosurg Psychiatry* 1959;22:99–108
8. Gardner WJ. Hydrodynamic factors in Dandy-Walker and Arnold-Chiari malformations. *Childs Brain* 1977;3:200–212
9. Sawaya R, McLaurin RL. Dandy-Walker syndrome. Clinical analysis of 23 cases. *J Neurosurg* 1981;55:89–98
10. Haber K, Wachter RD, Christenson PC, Vaucher Y, Sahn DJ, Smith JR. Ultrasonic evaluation of intracranial pathology in infants: a new technique. *Radiology* 1980;134:173–178
11. Archer CR, Darwish H, Smith K Jr. Enlarged cisternae magna fossa cysts simulating Dandy-Walker syndrome on computed tomography. *Radiology* 1978;127:681–686
12. Raybaud C. Cystic malformations of the posterior fossa. *J Neuro-radiol* 1982;9:103–133
13. Gooskens RH, Veiga-Pires JA, van Nieuwenhuizen O, Kaiser MC. CT of sebaceous nevus syndrome (Jadassohn disease). *AJNR* 1983;4:203–205
14. Kaiser MC, Veiga-Pires JA. Evaluation de nouvelles techniques en tomodynamométrie. *Ann Radiol (Paris)* 1980;23:559–563
15. Kaiser MC, Gooskens RH, Veiga-Pires JA, Troost J. Indications for direct multidirectional or multiplanar electronics reconstructions in CT-scanning of the head. *Eur J Radiol* 1982;2:319–322